



## OLGU SUNUMU / CASE REPORT

# Desmoplastic ameloblastoma masquerading as a fibro-osseous lesion

Bir fibro-kemik lezyonunu taklit eden desmoplastik ameloblastoma

Ananya Madiyal<sup>1</sup>, G. Subhas Babu<sup>1</sup>, Vidya Ajila<sup>1</sup>, Medhini Madi<sup>1</sup>, Renita Castelino<sup>1</sup>, Kumuda Rao<sup>1</sup>

<sup>1</sup>Department of Oral Medicine and Radiology, A. B. Shetty Memorial Institute of Dental Sciences, Nitte University.

*Cukurova Medical Journal 2017;42(3):575-578*

### Abstract

Desmoplastic ameloblastoma shows distinct clinical, radiographic and histopathologic characteristics. It is characterised by unusual histomorphology comprising of extensive stromal colonisation or desmoplasia. The mixed radiopaque-radiolucent appearance of the tumor makes its diagnosis complex leading to delay in treatment or lack of aggression in the treatment modality. This, along with its propensity to occur in the maxilla and its infiltrative nature makes desmoplastic ameloblastoma a perilous lesion to misdiagnose. We describe here a case of desmoplastic ameloblastoma that showed clinical and radiographic features of a fibro-osseous lesion thereby necessitating histopathologic confirmation. With a dearth of reported cases in the Indian subcontinent, we hope to improve the body of knowledge regarding this unusual lesion and demonstrate the importance of early and accurate diagnosis.

**Key words:** Ameloblastoma, desmoplastic, radiopaque-radiolucent.

### Öz

Desmoplastik ameloblastoma farklı klinik, radyografik ve histopatolojik özellikler gösterir. Kapsamlı stroma kolonizasyonu veya desmoplaziyi içeren olağandışı histomorfoloji ile karakterizedir. Tümörün karışık radyopak-radyolüsent görünümü, tanıyı karmaşık hale getirir ve tedavi modalitesinde tedavide gecikmeye veya agresivite eksikliğine neden olur. Bu maksillerde ortaya çıkma eğilimi ve infiltratif doğası ile birlikte desmoplastik ameloblastoma yanlış teşhis için tehlikeli bir lezyon oluşturur. Burada fibro-osseöz lezyonun klinik ve radyografik özelliklerini gösteren, bu nedenle histopatolojik doğrulama gerektiren bir desmoplastik ameloblastom olgusunu sunuyoruz. Hint alt kıtasında bildirilen vakaların azlığı ile bu alışılmadık lezyonla ilgili bilgi birikimimizi iyileştirmeyi ve erken ve doğru teşhisinin önemini ortaya koymayı umuyoruz.

**Anahtar kelimeler:** Ameloblastoma, desmoplastik, radyopak-radyolüsen.

## INTRODUCTION

Ameloblastomas are a perplexing group of oral tumors. Although they exhibit profound local invasion, they are considered as a benign neoplasm of odontogenic origin<sup>1</sup>. The neoplasm was first described by Cusak in 1827 and went through a series of name revisions including ‘cystosarcoma’, ‘adamantinoma’, ‘adamantine epithelioma’ and finally ‘ameloblastoma’ for the French word ‘amel’ meaning enamel and the Greek word ‘blastos’ which means germ or bud<sup>2,3</sup>. It is one of the most common types of odontogenic tumors and is known to arise from epithelial cell rests of Malassez, the cell rests of Serre, epithelium surrounding odontogenic cysts and

basal cell layer of gingiva or oral mucosa<sup>4</sup>.

Eversole described desmoplastic ameloblastoma (DA) as early as in 1984 calling it “ameloblastoma with pronounced desmoplasia”<sup>5</sup>. But it was only in 1992 that WHO recognised DA as a variant of classic ameloblastoma<sup>6</sup>. DA is a rare type of ameloblastoma comprising of about 4-5% of the reported cases. It is characterised by unusual histomorphology comprising of extensive stromal colonisation or desmoplasia<sup>7,8</sup>. Several cases of DA have been reported in the Malaysian, Chinese, Japanese, Western and African populations but very few cases have been described in the Indian subcontinent<sup>8</sup>. We present here a case of desmoplastic ameloblastoma which masqueraded as

Yazışma Adresi/Address for Correspondence: Dr. Ananya Madiyal, Department of Oral Medicine and Radiology, A. B. Shetty Memorial Institute of Dental Sciences Nitte University, Deralakatte, Mangalore Email: ananyamadiyal@gmail.com  
Geliş tarihi/Received: 15.10.2016 Kabul tarihi/Accepted: 02.11.2016

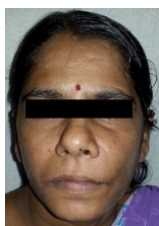a fibro-osseous lesion in its clinical and radiographic features.

## CASE

A 46 year old female patient reported to the dental hospital with a complaint of a painless, gradually progressive swelling in the left side of the face since 1 year. Paraesthesia or discharge was not reported. The teeth in the region were extracted 2 months ago. Her medical history was non-contributory.

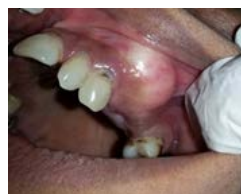Extra-oral examination revealed a diffuse, non-tender, bony hard swelling on the left middle third of the face measuring approximately 3 X 3 cm in dimensions obliterating the nasolabial fold. It extended anteriorly from the philtrum, posteriorly up to 5 cm ahead of the tragus of the left ear. Superiorly the swelling extended from 2 cm below the inferior palpebral conjunctiva, inferiorly up to the upper border of the upper lip. The overlying skin appeared normal. (Figure 1)

Intra-oral examination revealed a diffuse swelling measuring approximately 2 X 2 cm on the buccal aspect of the alveolar ridge extending from the mesial aspect of the left maxillary canine up to the mesial aspect of first maxillary molar on the left side. Obliteration of the upper buccal sulcus was seen. A similar swelling was noticed on the palate extending up to the midline. The lesion was covered by normal appearing mucosa, was bony hard in consistency and non-tender. Hard tissue examination revealed several missing teeth and teeth that were grossly decayed. (Figure 2, Figure 3)

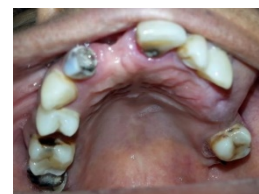

**Figure 1.** Extra-oral view showing swelling on the left middle third of the face.

Electric pulp vitality testing was done on all the teeth in the upper left quadrant and all teeth showed adequate response. Based on the history and clinical features, a provisional diagnosis of a fibro-osseous lesion was made. Differential diagnoses such as benign odontogenic tumor, ossifying fibroma and fibrous dysplasia were considered and radiographic examination was carried out.

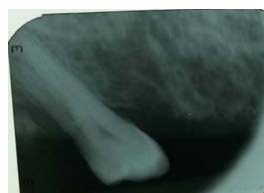


**Figure 2.** Intra-oral view showing swelling in the labial side of the alveolus.

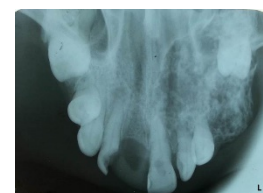

**Figure 3.** Intra-oral view showing swelling in the palatal side of the alveolus.

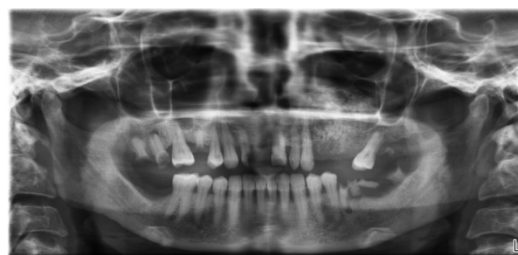Intra-oral periapical radiograph of the left posterior maxilla showed increased radiopacity and trabeculation of the alveolar bone (Figure 4). Maxillary true occlusal radiograph showed increased trabecular density with a diffuse area of radiopacity and increased trabeculation extending from the left maxillary first molar up to the left central incisor. Expansion of the buccal cortical plate of the left maxilla was also evident (Figure 5). Panoramic radiography revealed diffuse radiopacity extending from the distal aspect of left maxillary central incisor up to the mesial aspect of left maxillary first molar with increased trabecular density. Radiopacity was noticed over the lower aspect of the left maxillary sinus (Figure 6). Based on the findings, a radiographic differential diagnosis of fibro-osseous lesion was considered and biopsy was advised.



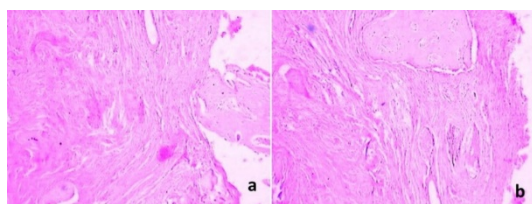
**Figure 4.** Intraoral periapical radiograph showing mixed radiopaque-radiolucent lesion.



**Figure 5.** Maxillary occlusal radiograph showing mixed radiopaque-radiolucent lesion and expansion of the buccal cortical plate.



**Figure 6.** Orthopantomograph showing mixed radiopaque-radiolucent lesion.



**Figure 7 (a-b). Photomicrographs showing dense fibrous connective tissue, bony trabeculae and ameloblastic islands.**

Under local anesthesia, buccal flap was raised and part of the alveolar bone was removed. Histopathological examination of decalcified H & E stained sections showed presence of dense fibrous connective tissue, bony trabeculae and few ameloblastic islands. The bony bits showed both woven and lamellated bone. Ameloblastic islands seen were of varying size, peripheral columnar and central stellate reticulum like cells. Some of the islands showed cystic change. Extravasted RBCs were also seen giving the impression of desmoplastic ameloblastoma (Figure 7 a-b). Surgical resection was done. Post-operative period was uneventful and the patient was disease free and was under routine follow-up.

## DISCUSSION

Tumors arising from odontogenic tissues make up only 1% of all jaw tumors in humans and ameloblastomas comprise of nearly half of these odontogenic tumors<sup>4</sup>. The estimated global incidence of ameloblastoma is at 0.5 cases per million person years, and a majority of these cases are diagnosed in patients in the age range of 30–60 years<sup>1</sup>. Several researches have tried to elucidate the cause for the development of ameloblastoma. Until recently, little was known about the molecular anomalies due to both the rarity of the tumor as well as the deficiency in advances in technologies. However, it has now been found that a majority of these tumors show somatic mutations impacting the mitogen activated protein kinase (MAPK) signaling pathway that controls cell proliferation<sup>1</sup>. Alterations in various factors that play a role in the development and progression of tumors such as oncogenes like fibroblast growth factor receptor, transcription factors like myc, tumour suppressor genes like retinoblastoma, oncoviruses like human papilloma virus and Epstein barr virus have been found<sup>4</sup>. WHO classified ameloblastoma into 4

subtypes: classic solid/ multicystic ameloblastoma, unicystic ameloblastoma, extra osseous ameloblastoma and desmoplastic ameloblastoma<sup>9</sup>. Other histologic variants include follicular and plexiform patterns which are the most common as well as the acanthomatous and granular cell types. Less common cellular variants are the papilliferous keratoameloblastoma, keratoameloblastoma, basal cell ameloblastoma and clear cell ameloblastoma<sup>10</sup>. Desmoplastic ameloblastoma differs in its anatomic distribution, radiographic features and histopathologic features when compared to the classic ameloblastoma.

The tumor is commonly seen in the third to fifth decade of life with equal preference for both genders. Demographic data shows that they occur more often in the western population when compared to Asians<sup>8,11</sup>. Unlike classic ameloblastoma which is more often seen in the posterior aspect of the mandible, DA shows nearly equal predilection for both jaws with a maxilla-to-mandible ration of 1:0.9<sup>4</sup>. It is found to have an affinity for the anterior or premolar regions of the jaws while the classic ameloblastoma is most often seen in the posterior jaw<sup>8</sup>. The present case also conformed to the literature on these aspects. No fixed radiographic features are associated with this type of ameloblastoma. Cases have been reported of localized irregular multilocular radiolucency with indistinct borders or a mixed radiopaque-radiolucent appearance or a massive expansible osteolytic lesion with honeycomb, mottled or multilocular appearance. The ill-defined borders are suggestive of its infiltrative nature<sup>4,8,10,11</sup>.

A similar mixed radiographic appearance with indistinct borders and a long and asymptomatic clinical history in the present patient led to a differential diagnosis of a fibro-osseous lesion such as fibrous dysplasia. Tooth displacement is a common feature. Impacted teeth are found in approximately 3.4% of the cases as compared to 8.7% of the classic ameloblastoma cases<sup>4,8</sup>. These features were not found in the present case.

Waldron et al described the histologic appearance of DA as small ovoid islands and narrow cords of odontogenic epithelium widely separated by dense, moderately cellular fibrous connective tissue. Extensive stromal desmoplasia is a prominent feature and myxoid changes of the stroma may be observed surrounding the odontogenic epithelium. The desmoplastic stroma of DA is not scar tissue

but newly produced connective tissue<sup>12</sup>. Clinically, maxillary lesions are more dangerous than mandibular ones as they allow loco-regional spread. Only a weak natural barrier exists in the form of the thin maxillary bone and the tumors can invade the adjacent sinus and orbit thereby involving vital structures early in the disease process<sup>4,8</sup>. Surgical treatment of the tumor becomes complicated due to the anatomic preference for maxilla, a potential to grow into a large size and a mixed radiographic appearance with indistinct interface with the normal bone. Enucleation or curettage alone may lead to recurrence due to its infiltrative nature. Therefore, complete resection and regular follow-up is recommended as was done in the present case<sup>4,13</sup>.

Until a more focused treatment modality is formulated for DA, it continues to be treated similar to classic ameloblastoma with a similar or slightly higher recurrence rate of 15.9%<sup>4</sup>. For surveillance purposes, patients should have a post-operative lifetime annual clinical exams. In the asymptomatic patient, surveillance at increasing intervals over the first 5 years is reasonable<sup>1</sup>.

From first being described in 1827 by Cusack, to the recent genetic discoveries, our understanding of ameloblastoma has greatly improved. However, given the paucity of certain types of ameloblastomas like the desmoplastic variant, a vacuum exists in the body of knowledge regarding its behaviour and eventual prognosis. Moving forward, it will be imperative to further enhance our understanding of the disease both clinically and molecularly to improve the precision with which we treat this tumor.

## REFERENCES

1. McClary AC, West RB, McClary AC, Pollack JR, Fischbein NJ, Holsinger CF et al.. Ameloblastoma: a clinical review and trends in management. *Eur Arch Otorhinolaryngol.* 2016;7:1649-61.
2. Cusack JW. Report of the amputations of the lower jaw. *Dublin Hop Rec.* 1827;4:1-38.
3. Ivery RH, Churchill HR. The need of a standardized surgical and pathological classification of tumors and anomalies of dental origin. *Am Assoc Dent Sch Trans.* 1930;7:240-5.
4. Laxmidevi BL, Kokila G, Mahadesh J. Ameloblastoma: adding perspectives. *Journal of Dental Sciences and Research.* 2010;1(2):11-22.
5. Eversole LR, Hansen LS, Leider AS. Ameloblastomas with pronounced desmoplasia. *J Oral Maxillofac Surg* 1984;42:735-40.
6. Sivapathasundharam B, Einstein A, Syed RI. Desmoplastic ameloblastoma in Indians: report of five cases and review of literature. *Indian J Dent Res.* 2007;18:218-21.
7. Savithri V, Janardhanan M, Suresh R, Kumar RB. Desmoplastic ameloblastoma with osteoplasia: Review of literature with a case report. *J Oral Maxillofac Pathol.* 2013;17:298-301.
8. Laxmana AR, Gogineni SB, Thomas PS, Shetty SR. Desmoplastic ameloblastoma - a report of two clinical cases. *Braz J Oral Sci.* 2010;9:137-41.
9. Barnes L, Eveson JW, Reichart PA, Sidransky D. *World Health Organization Classification of Tumours. Pathology and genetics of head and neck tumours.* Lyon, IARC Press, 2005.
10. Pillai RS, Ongole, R, Ahsan A, Radhakrishnan RA, Pai KM. Recurrent desmoplastic ameloblastoma of the maxilla: a case report. *J Can Dent Assoc.* 2004;70:100-4.
11. Manuel S, Simon D, Rajendran R, Naik BR. Desmoplastic ameloblastoma: a case report. *Oral Maxillofac Surg.* 2002;60:1186-8.
12. Waldron CA, El-Mofty SK. A histopathological study of 116 ameloblastomas with special reference to the desmoplastic variant. *Oral Surg Oral Med Oral Pathol.* 1997;63:441-51.
13. Sun ZJ, Wu YR, Cheng N, Zwahlen RA, Zhao YF. Desmoplastic ameloblastoma: a review. *Oral Oncol.* 2009;45:752-9.