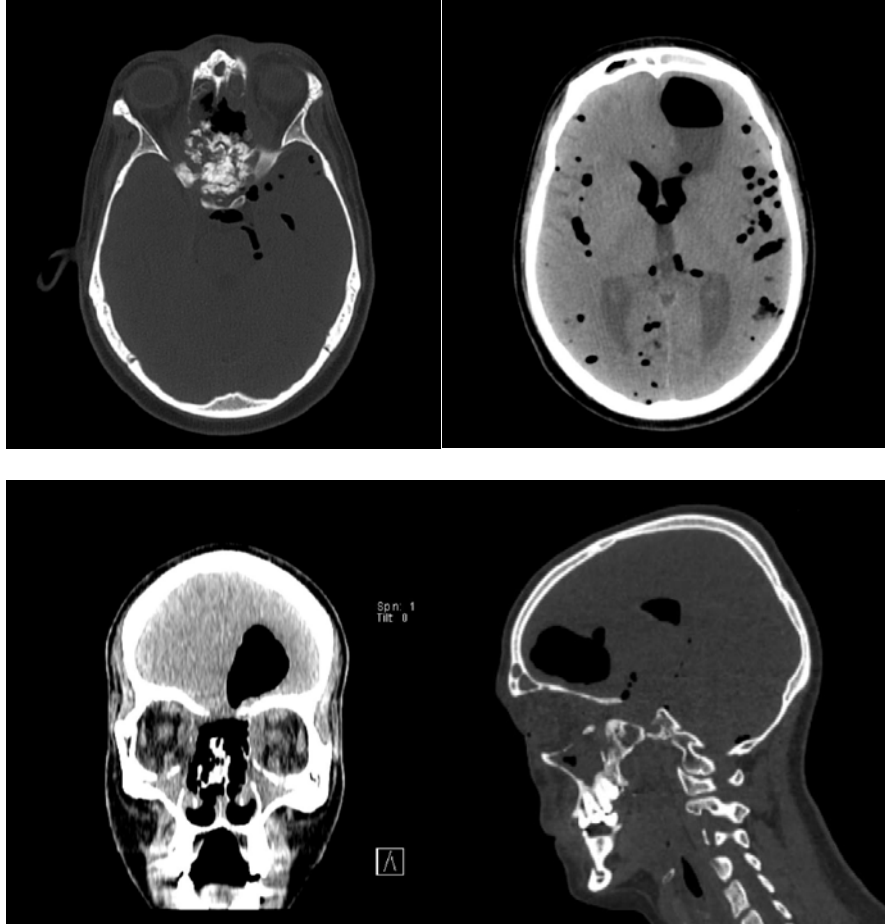


## A Rare Cause Of Pneumocephalus; Nasopharynx Cancer

Pnömocefalinin Nadir Bir Nedeni; Nazofarinks Kanseri

**Çakmak F, Aman G, Tunc G**

Department of Emergency Medicine, Cerrahpasa Faculty of Medicine, Istanbul University-Cerrahpasa, Istanbul, Turkey



Cranial and paranasal sinus tomography (Somatom definition AS Plus, Siemens; Erlangen, Germany) was performed, and the results showed a lytic expansile mass lesion on the sphenoid bone and sphenoid sinus, middle brain fossa and brain base with sclerotic amorphous calcifications. The described mass extends from the sphenoid bone to posterior ethmoid cells and tuberculum sellae. In the anterior part of the lesion, air images associated with the nasal cavity were present. The lesion described, destroyed the medial walls of both maxillary sinuses and extended to the right subtemporal fossa. A 5 cm round, abscess-compatible lesion with air-fluid level

was observed in the left frontal lobe. Air fluid levels were observed in both lateral ventricles and third ventricles. Multiple air images were observed in bilateral infra and supratentorial cisterns. Partial aeration loss was observed in both halves of the frontal sinus and maxillary sinus. Osteodural tear and abscess were detected in the left frontal lobe.

The patient was operated on for nasopharyngeal cancer five months ago and received radiotherapy four months ago. The patient presented to the emergency department with sudden onset of nausea and general deterioration.

**Received:** 13.09.2019

**Accepted:** 14.09.2019

**Correspondence:** Fatih Çakmak, MD Istanbul University-Cerrahpasa, Cerrahpasa Faculty of Medicine, Emergency Department, Istanbul, Turkey. **Email:** [faith.cakmak@istanbul.edu.tr](mailto:faith.cakmak@istanbul.edu.tr) **Phone:** +90 532 6539947

**Cite this article as:** Çakmak F, Aman G, Tunc G. A Rare Cause Of Pneumocephalus; Nasopharynx Cancer. Phnx Med J. 2019;1(1):50.