

## Percutaneous drainage in treatment for spontaneous rectus abdominis hematoma due to rivaroxaban usage

Nurullah Dogan<sup>1</sup>, Aydin Dursun<sup>2</sup>

<sup>1</sup> Department of Radiology, Bursa Doruk Hospital, Bursa, Turkey

<sup>2</sup> Department of Cardiology, Bursa Medical Park Hospital, Bursa, Turkey

### ABSTRACT

Rivaroxaban is currently used to prevent stroke in patients with atrial fibrillation. Like all anticoagulants, rivaroxaban carries a risk of bleeding. There is a single reported case of rectus abdominis hematoma due to rivaroxaban use in the literature. We present an 82-year-old female patient presented to our outpatient clinic with sudden pain and swelling in the abdominal region. The patient had been treated with rivaroxaban for three months without warfarin. Computed tomography scanning showed a 25x10x15 cm long acute hematoma in the left rectus abdominis. Rivaroxaban was replaced with enoxaparin for thromboembolus prophylaxis. We performed percutaneous drainage in order to reduce pain and recovery time by decreasing the hematoma size. Catheter drainage was used in the third day to minimize rivaroxaban activity. We did not come across any literature date on percutaneous drainage treatment of spontaneous rectus abdominis hematoma. We report a case of hematoma of the rectus abdominis muscle that occurred following rivaroxaban use and was successfully treated with percutaneous drainage.

*Eur Res J 2016;2(2):151-153*

**Keywords:** Rivaroxaban; spontaneous rectus abdominis hematoma; treatment; percutaneous drainage

### Introduction

Rivaroxaban is currently used to prevent strokes in patients with atrial fibrillation. It offers several advantages compared with standard agents, including rapid onset of action, fixed dosing, and no requirement for routine coagulation monitoring. However, like all anticoagulants, rivaroxaban carries a risk of bleeding [1-3]. Hematomas of the rectus abdominis muscle are commonly reported complications of systemic anticoagulation treatment [4]. There is a single

reported case of rectus abdominis hematoma due to rivaroxaban use in the literature [5]. We did not come across any literature date on percutaneous drainage treatment of spontaneous rectus abdominis hematoma. We report a case of hematoma of the rectus abdominis muscle that occurred following rivaroxaban use and was successfully treated with percutaneous drainage.

### Case Presentation

*Address for correspondence:*

Nurullah Dogan, Department of Radiology, Bursa Bahar Hospital, Bursa, Turkey

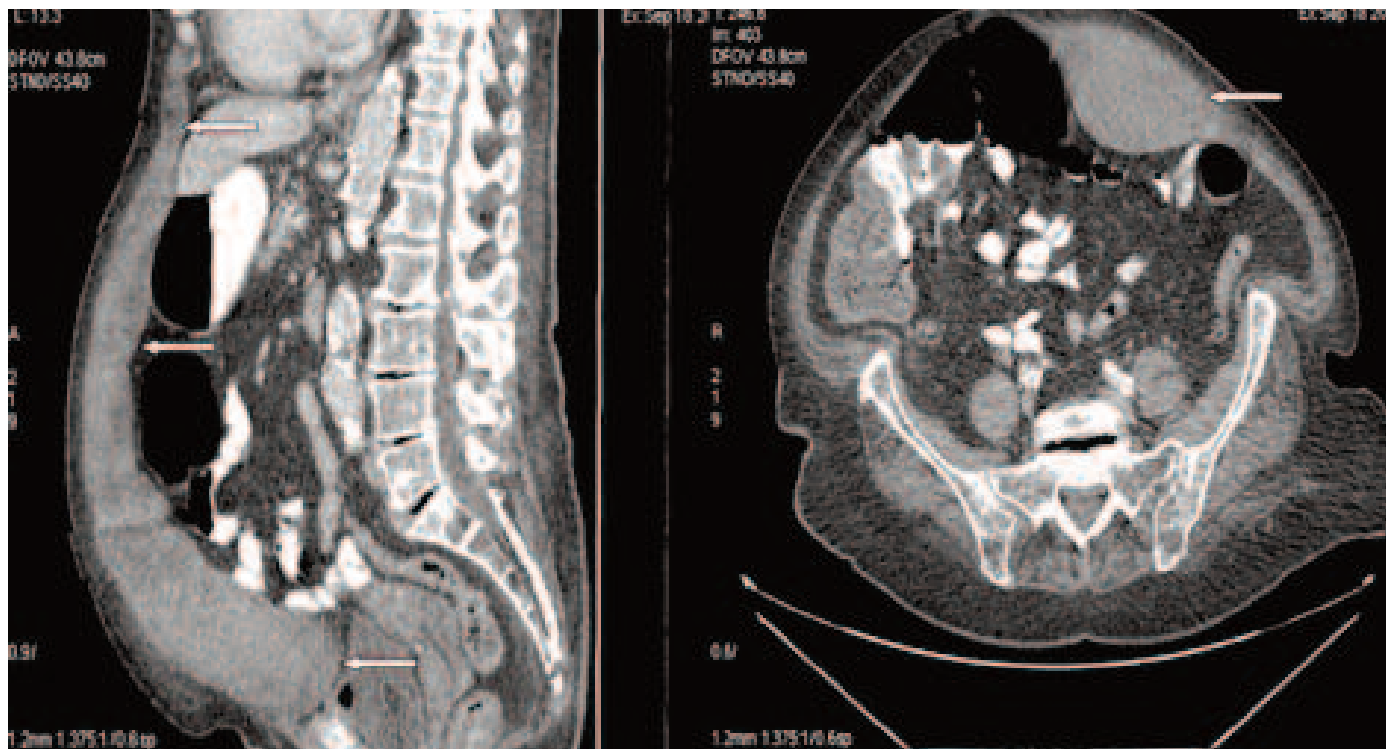
Email: [drndogan@gmail.com](mailto:drndogan@gmail.com)

Received: November 24, 2015; Accepted: March 22, 2016; Published Online: May 11, 2016

An 82-year-old female patient presented to our outpatient clinic with sudden pain and swelling in the abdominal region. She had a history of previous coronary artery bypass surgery, heart failure, hypertension, diabetes mellitus, and atrial fibrillation. Her medical treatment consisted of diltiazem, furosemide, rosuvastatin, valsartan and rivaroxaban. The CHA2DS2-VASC and HAS BLED scores were 7 and 2 respectively. The patient had been treated with

rivaroxaban for three months without warfarin because of the difficulty of dosing warfarin in elderly patients. Physical examination revealed a mass in the left side of the umbilicus. Laboratory results were hemoglobin (Hb):12 gr/dl, platelets: 178000 K/uL, prothrombin time: 14.2 sec, international normalization ratio (INR): 1.12, and serum creatinine: 0.81 mg/dl, with normal liver function test results.

Computed tomography (CT) scanning showed a



**Figure 1.** Computed tomography showing long acute hematoma in the left rectus abdominis (Arrows)

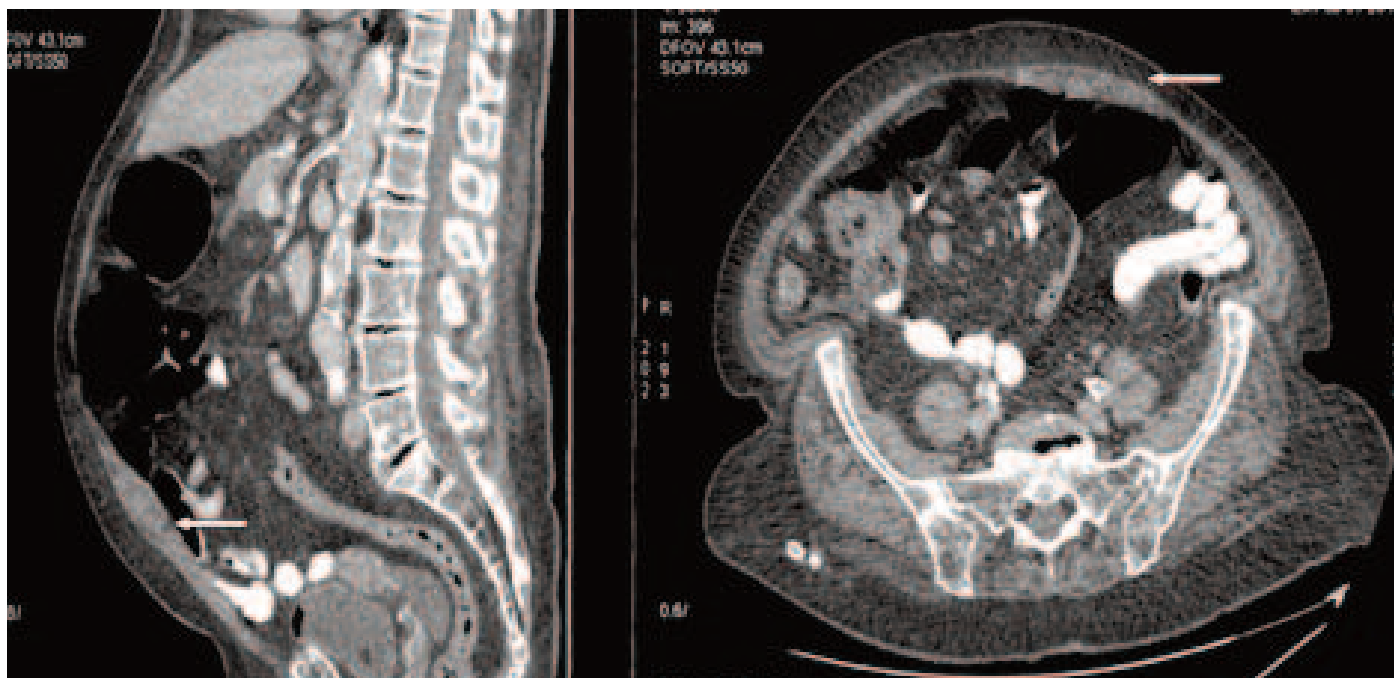
25x10x15 cm long acute hematoma in the left rectus abdominis (Figure 1). In history, there was no surgical intervention or trauma which cause hematoma. Rivaroxaban was replaced with enoxaparin for thromboembolic prophylaxis. The hb level was 9.8 gr/dl on the first day and she was administered 2 units of erythrocyte suspension. Hb values remained stable at follow-up. However patient had severe abdominal pain resulting in hypotension and abdominal discomfort. Therefore, we decided for percutaneous drainage instead of spontaneous resorption. On the third day, an ultrasound-guided percutaneous drainage catheter (12 F drainage catheter Skater, Angiotech) was implanted to the hematoma region under local anaesthesia to accelerate the resorption of the hematoma. Partial drainage of the hematoma was performed by manual aspiration and then free drainage was allowed. Adequate drainage was provided and the catheter was removed on the 3<sup>rd</sup> postoperative day. Abdominal pain and patients discomfort ceased after

the successful drainage of the hematoma. The patient was discharged on the clopidogrel and acetylsalicylic acid combination because of the refusal of rivaroxaban use by the patient and her relatives. The rectus muscle hematoma was almost completely resorbed at the third month follow-up CT (Figure 2).

## Discussion

Rivaroxaban is an oral anticoagulant agent that directly inhibits Factor Xa and interrupts both the intrinsic and extrinsic pathways. It is currently indicated for atrial fibrillation and prophylaxis of deep venous thrombosis. It does not require INR monitoring like warfarin [5].

Real-world data on bleeding with rivaroxaban are limited, but trial sub-analyses are available. In the Rivaroxaban Once-daily, Oral, Direct Factor Xa Inhibition Compared with Vitamin K Antagonism for



**Figure 2.** The rectus muscle hematoma is almost completely resorbed at the third month follow-up CT scan (Arrows)

Prevention of Stroke and Embolism Trial in Atrial Fibrillation (ROCKET AF Trial) study, predictors of major bleeding with rivaroxaban included older age, male sex, increased body mass index, diabetes, chronic obstructive lung disease, and worsening renal function. Risks of major adverse outcomes including death following a major bleeding event were similar in patients treated with rivaroxaban and warfarin in the ROCKET AF Trial [1-3].

Rectus hematoma is considered an uncommon bleeding complication that can occur spontaneously after trauma or as a result of anticoagulation therapy. Management of a rectus hematoma is usually conservative [4]. Invasive treatment is only indicated if the rectus hematoma is progressive or if the patient is hemodynamically unstable [6]. We performed percutaneous drainage in order to reduce pain and recovery time by decreasing the hematoma size. Catheter drainage was used in the third day to minimize rivaroxaban activity.

## Conclusion

Rectus abdominis hematoma should be considered in patients who complain of abdominal pain/swelling while using rivaroxaban. The hematoma may occur without surgery or trauma especially in older patients. Large muscle hematomas can be drained percutaneously in order to terminate abdominal pain, which may cause vagal reactions and to accelerate

patients' recovery.

### *Informed consent*

Written informed consent was obtained from the patient for the publication of this case report.

### *Conflict of interest*

The authors declared that there are no potential conflicts of interest with respect to the research, authorship, and/or publication of this article.

## References

- [1] Patel MR, Mahaffey KW, Garg J, Pan G, Singer DE, Hacke W, et al. Rivaroxaban versus warfarin in nonvalvular atrial fibrillation. *N Engl J Med* 2011;365:883-891.
- [2] Yang E. A clinician's perspective: novel oral anticoagulants to reduce the risk of stroke in nonvalvular atrial fibrillation – full speed ahead or proceed with caution. *Vasc Health Risk Manag* 2014;21:507-522.
- [3] Fontaine GV, Mathews KD, Woller SC, Stevens SM, Lloyd JF, Evans RS. Major bleeding with dabigatran and rivaroxaban in patients with atrial fibrillation: a real-world setting. *Clin Appl Thromb Hemost* 2014;20:665-672.
- [4] Sullivan LEJ, Wortham DC, Litton KM. Rectus sheath hematoma with low molecular weight heparin administration: a case series. *BMC Res Notes* 2014;7:586.
- [5] Kocayigit I, Can Y, Sahinkus S, Aydin E, Vatan MB, Kilic H, et al. Spontaneous rectus sheath hematoma during rivaroxaban therapy. *Indian J Pharmacol* 2014;46:339-340.
- [6] Galyfos G, Karantzikos G, Palogos K, Sianou A, Filis K, Nikolaos K. Spontaneous rectus sheath hematoma in the elderly: an unusual case and update on proper management. *Case Rep Emerg Med* 2014;2014:675678.