



Masif Hemoptizi Etiyolojisinde Nekrotizan Pnömoni: Olgu sunumu Necrotising Pneumonia In Etiology of Massive Hemoptysis: A case report

Fulsen Bozkuş¹, Nurhan Atilla², Selma Ateş³

Kahramanmaraş Sütçü İmam Üniversitesi Tıp Fakültesi Göğüs Hastalıkları, Kahramanmaraş
Kahramanmaraş Sütçü İmam Üniversitesi Tıp Fakültesi Göğüs Hastalıkları, Kahramanmaraş
Kahramanmaraş Sütçü İmam Üniversitesi Tıp Fakültesi Enfeksiyon Hastalıkları, Kahramanmaraş

ÖZET

Nekrotizan pnömoni, toplum kökenli pnömoni seyri sırasında akciğer parankiminin nekroze olması sonucu gelişir. Radyolojik olarak kavite sıklıkla görülür ancak her zaman klinik duruma eşlik etmeyebilir. Pnömonisi olan hastada ateşin uzun süre devam etmesi ve klinik tablonun bozulması şüphe uyandırmalıdır. Kaviteyle seyretmesi, tedaviye geç cevap vermesi ve kültürde çoğunlukla üreme olmaması hem tüberküloz gibi kaviteyle seyreden hastalıklar arasında ayırıcı tanıda, hem de tedavide problem oluşturmaktadır. Biz burada masif hemoptizi ile prezente olan nekrotizan pnömoni olgusunu sunduk.

Anahtar Kelimeler: Nekrotizan Pnömoni, hemoptizi, nekroz.

ABSTRACT

Necrotising pneumonia (NP) is characterized by necrosis within infected lung tissue. Sometimes it is misnomered as cavitating pneumonia as it is not always complicated with cavitation. Long lasting fever and clinic deterioration of the patient can be the clues of NP. By means of cavitation, hemoptysis and negative culture; tuberculosis should be considered in differential diagnosis. False negative cultures are also problematic in treatment. In this case study, we aimed to present a case with massive hemoptysis diagnosed as NP.

Key words: Necrotizing pneumonia, hemoptysis, necrosis.

Corresponding Author: Fulsen Bozkuş
Adress: Kahramanmaraş Sütçü İmam Üniversitesi Tıp Fakültesi
Göğüs Hastalıkları, Kahramanmaraş
E-mail: fulsenbatmaz@gmail.com

Başvuru Tarihi/Received: 25-04-2016
Kabul Tarihi/Accepted: 26-04-2016



Introduction

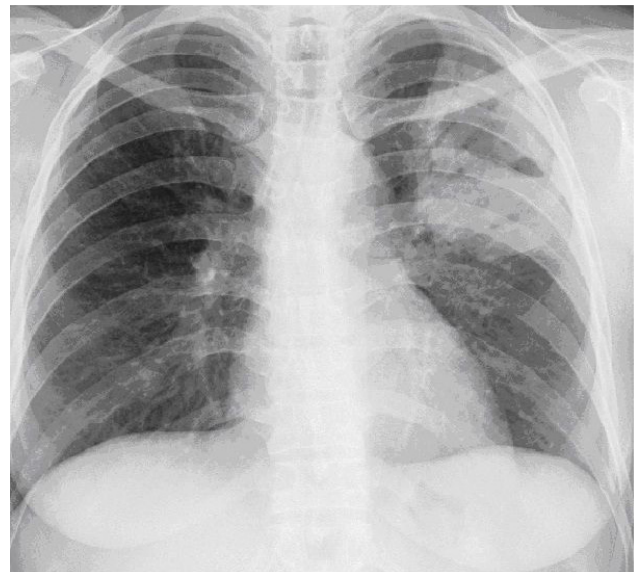
Hemoptysis is a common finding in a daily practice of a pulmonologist. It can be presented in a wide range from blood-streaked sputum to major bleeding with ensuing respiratory compromise and hemodynamic instability. Massive hemoptysis should always be considered as a life threatening condition which needs great interest in evaluation of the patient [1]. The most common causes of massive hemoptysis are infections which are generally caused by *Mycobacterium* (particularly tuberculosis), fungi (including *mycetoma*), necrotising pneumonia (NP) and lung abscess (*Klebsiella pneumoniae*, *Pseudomonas aeruginosa*, *Staphylococcus aureus*, *Streptococcus pneumoniae*, other *Streptococcus spp.* and *Actinomyces spp.*), bacterial endocarditis with septic emboli and parasites (paragonimiasis, hydatid cyst) [1]. We aimed to present massive hemoptysis with NP which is a rare condition and can easily be misdiagnosed as tuberculosis and resistant to treatment.

Case report

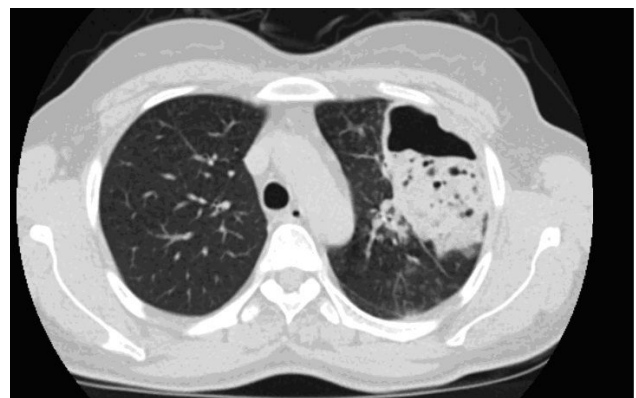A 30-year old female patient admitted to our clinics with a history of 15 day coughing which is followed by fever after a few days. In another clinic which she was previously admitted diagnosed her as pneumonia and started the treatment of ceftriaxon 1g 2x1, clarithromycin 500 mg 2x1. On the fourth day of treatment she has presented with massive hemoptysis and shortness of breath. She was brought to emergency department. On her examination she had a fever of 38.50C, blood pressure was 90/60 mm Hg, respiratory rate was 22 breaths per minute. Oxygen saturation of fingertip artery was 92% while she was breathing with room air.

Laboratory examination on admission revealed white blood cell count of 14,140/mm³, hematocrit 28,5%, hemoglobin count 9,8gr/dl, and C-reactive protein 151mg/dL. On chest X ray, there was air density surrounded by consolidation area on upper segment of left lung (Picture 1). On thoracal computed tomography (CT), there was a consolidation area which contains cavitation and necrosis in the center which

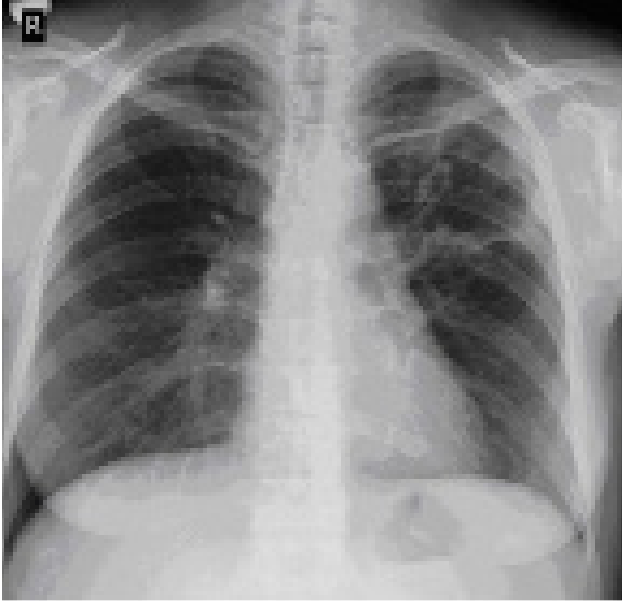
is located in periphery of superior segment of left lung (Picture 2). She was hospitalized with presumptive diagnosis of tuberculosis, lung abscess and NP. Intravenous 3x1 g meropenem and 1x1 g aminoglycoside treatment have been started. Her amount of hemoptysis was 250 cc/day. Fiberoptic bronchoscopy was performed and revealed no active bleeding at the bronchial system. Bronchial lavage has been done. After 48 hours her body temperature was decreased into normal levels but her hemoptysis continued 200-250 cc/day. Her four consecutive sputum and bronchial lavage specimens revealed no staining with Ehrlich-Ziehl-Neelsen and culture results were negative. After 14 days of antibiotherapy her laboratory and radiological results were improved (Picture 3).



Picture 1



Picture 2



Picture 3

Discussion

NP is characterized with pneumonic consolidation with multiple necrosis of lung parenchyma. Coalescent of these necrotic foci may result in lung abscess or pulmonary gangrene if involves entire lobe. This process can occur in any lobe of lung but it is more common in right lower, right middle and left lower lobes [2]. In our case, left upper lobe was involved.

There are some patient related and bacteriological related factors in development of NP. Most common causative agent of this situation is generally bacteriological which are; *Staphylococcus aureus*, *Streptococcus pneumoniae* and *Klebsiella pneumoniae*. *Pseudomonas aeruginosa*, *Haemophilus influenzae*, *Escherichia coli*, *Acinetobacter baumannii*, and *anaerobic pathogens* [2].

Tseng et al. investigated 30 patients with NP; most patients either had infection with *S. pneumoniae* or *S. aureus* or no causative microorganism that could be identified [3]. In five patients, however, only a non-bacterial pathogen was isolated from lung tissue, including *Mucor species* and *Aspergillus fumigatus*. All patients with non-bacterial pathogens isolated were immunosuppressed. Subsequent studies have also suggested that non-bacterial infectious causes for lung necrosis are more common in immunocompro-

mised patients [4]. Our patient had no immunosuppressing condition or medication exposure.

The most common symptoms are cough, fever, shortness of breath, chest pain, hemoptysis and purulent sputum. These patients may sometimes present with confusion [5]. Complications such as parapneumonic effusion or empyema may develop commonly. Bronchopleural fistula, massive hemoptysis, and bilateral diffuse pneumonia are rare complications [2]. In our case, the presenting symptom was massive hemoptysis. NP should be kept in mind in the differential diagnosis of massive hemoptysis although it is seen rarely. In a series of 62 Chinese patients who underwent bronchial arterial embolization for massive hemoptysis (> 600 ml/24 h) between 2000 and 2005, the underlying cause was an old tuberculosis in 34 (55%) subjects, bronchiectasis in 14 (23%), mycetoma in 5 (8%), lung cancer in 4 (6%), necrotizing pneumonia in 4 (6%), and an arteriovenous malformation in 1 (2%) [6].

Although massive hemoptysis is always associated as a possible lethal condition, there is no exact consensus on its precise definition. The daily amount of blood is used in the definition of massive hemoptysis. Unfortunately there isn't any standart cutoff value. Blood volume ranging from 100 ml/24 h to more than 1,000 ml/24 h have been proposed to define massive hemoptysis [1]. In our case there was 250 cc/day of hemoptysis. Screening is essential in these patients for prevention of aspiration, hemostasis and treatment of underlying reason.

Sputum Gram's stain can be quickly obtained but usually shows large concentrations of Gram-positive and Gram-negative bacteria. The result of sputum culture is also not reliable due to contamination from normal oropharyngeal flora. Cultures of infected lung tissue (obtained at the time of surgery), peripheral blood (if bacteremia is suspected), and pleural fluid (when pleural effusion coexists) are more reliable than sputum culture in the issue of bacteriological diagnosis of necrotizing pneumonia [2]. In our case, gram stains of specimens showed gram positive and negative bacteria but cultures were negative.

The diagnosis of necrotizing pneumonia is made generally according to chest imaging stud-

ies, including a series of radiography and contrast-enhanced computed tomography (CT). Early in the disease course, necrotizing pneumonia typically appears as consolidation on the chest radiograph [2]. Although chest X-ray is helpful in the diagnosis of necrotizing pneumonia, contrast-enhanced chest CT is the standard procedure in making the diagnosis especially at the onset of disease [7]. As in our case, pneumonic consolidation with multiple areas of necrotic low attenuation on CT is suggestive of necrotizing pneumonia.

Treatment of necrotizing pneumonia is mainly medical. Surgical intervention may be considered as an alternative treatment when the disease deteriorates or complications occur in

spite of optimal medical treatment. The choice of initial antibiotics should be directed at broad coverage with commonly implicated pathogens (*S. aureus*, *streptococci*, *K. pneumoniae*, etc) [8]. Additional empirical anaerobic antibiotic should be considered in patients with lung abscesses. We have given antibiotherapy as mentioned above. After 14 days we have seen the improvement of the clinical and radiological findings.

As a result, antibiotics remain the mainstay of treatment for necrotizing pneumonia. In addition to this; patient with massive hemoptysis should also be considered as NP and it should be noted that it can occur in individuals without underlying disease.

REFERENCES

1. Hirshberg B, Biran I, Glazer M, Kramer MR. Hemoptysis: etiology, evaluation, and outcome in a tertiary referral hospital. *Chest* 1997;112(2):440–444.
2. Tsai YF, Ku YH. Necrotizing pneumonia: a rare complication of pneumonia requiring special consideration. *Curr Opin Pulm Med* 2012;18(3):246–252.
3. Tseng YL, Wu MH, Lin MY, Lai WW, Liu CC. Surgery for lung abscess in immunocompetent and immunocompromised children. *J Pediatr Surg* 2001;36(3):470–473.
4. Mansharamani N, Balachandran D, Delaney D, Zibrak JD, Silvestri RC, Koziel H. Lung abscess in adults: clinical comparison of immunocompromised to non-immunocompromised patients. *Respir Med* 2002;96(3):178–185.
5. Li HT, Zhang TT, Huang J, Zhou YQ, Zhu JX, Wu BQ. Factors associated with the outcome of lifethreatening necrotizing pneumonia due to community-acquired *Staphylococcus aureus* in adult and adolescent patients. *Respiration* 2011;81(6):448–460.
6. Shigemura N, Wan IY, Yu SC, Wong RH, Hsin MK, Thung HK et al. Multidisciplinary management of life-threatening massive hemoptysis: a 10-year experience. *Ann Thorac Surg* 2009;87(3):849–853.
7. Chen CH, Huang WC, Chen TY, Hung TT, Liu HC, Chen CH. Massive necrotizing pneumonia with pulmonary gangrene. *Ann Thorac Surg* 2009;87(1):310–311.
8. Reimel BA, Krishnadasen B, Cuschieri J, Klein MB, Gross J, Karmy-Jones R. Surgical management of acute necrotizing lung infections. *Can Respir J* 2006;13(7):369-73