

Management of the complications of pubovaginal sling surgery

Omer Bayrak¹, Burhan Coskun², Murat Dincer³, Kadir Onem⁴, Rahmi Onur⁵; Turkish Urology Academy, Incontinence/Neurourology Study Group

¹Department of Urology, Gaziantep University School of Medicine, Gaziantep, Turkey

²Department of Urology, Uludag University School of Medicine, Bursa, Turkey

³Department of Urology, University of Health Sciences, Bagcilar Training and Research Hospital, Istanbul, Turkey

⁴Department of Urology, Ondokuz Mayıs University School of Medicine, Samsun, Turkey

⁵Department of Urology, Marmara University School of Medicine, Istanbul, Turkey

ABSTRACT

Objective. To present complications of pubovaginal sling surgery (PVS) and their managements. **Methods.** A total of 21 patients who underwent PVS in 4 different tertiary referral centers between June 2014 and May 2016 were reviewed retrospectively. Demographic characteristics of the patients, previous surgical history, daily pad use, Urogenital Distress Inventory (UDI-6) and Incontinence Impact Questionnaire (IIQ) were recorded. Also, the management of the complications were stated. **Results.** The mean age of the patients were 54.9 ± 12.32 (range, 36-76) years. Six (28.5%) patients had a history of previous incontinence surgery and 15 (71.4%) patients were naïve. There were no intraoperative complications. The mean daily pad use was decreased from 4.04 ± 0.95 to 0.95 ± 0.86 ($p=0.0001$). While mean preoperative UDI-6 scores were decreased from 6.66 ± 2.09 to 2.09 ± 1.22 ($p=0.0001$) at postoperative sixth month; preoperative mean IIQ-7 scores decreased from 16.8 ± 1.16 to 5.09 ± 4.21 ($p=0.0001$) at postoperative sixth month. One (4.76%) patient had abdominal hernia at postoperative 2nd year, three (14.28%) patients had an increased post-micturational residual (150-200ml) and two (9.52%) patients had urinary retention. **Conclusion.** Although the efficiency of PVS is high; one should aware of complications. The successful management of the complications will increase efficiency and patient satisfaction.

Eur Res J 2017;3(3):264-268

Keywords: Complication, pubovaginal sling, rectus fascia, stress urinary incontinence

Introduction

Urinary incontinence is an important health problem with a prevalence rate of 15-50% and stress urinary incontinence (SUI) represents the most common type of incontinence in women [1]. Today mid-urethral slings (MUS) are the most preferred method for the surgical treatment of female SUI

Address for correspondence:

Burhan Coskun, MD., Assistant Professor, Uludag University School of Medicine, Department of Urology, Bursa, Turkey

E-mail: coskunburhan52@gmail.com

Received: January 24, 2017; Accepted: May 27, 2017; Published Online: June 1, 2017

worldwide. MUS becomes very popular due to lesser invasive nature of the procedure and higher efficiency. After Food and Drug Administration (FDA) announcement on 2008 and 2011 the interest on MUS replaced with concern either from the patients or physicians. The number of pubovaginal slings (PVS) which have been performed in academic centers found to increased especially FDA notifications regarding mesh [2].

PVS and Burch colposuspension were the former leading surgical procedures for women with SUI. PVS was mainly indicated for intrinsic sphincter deficiency. However, it can be used in all SUI regardless of the underlying pathology [3]. The efficiency of PVS has been largely studied in previous series. In a recent review the success of PVS was found to be between 47% and 90% [4]. Autologous, allograft, xenograft or synthetic materials can be used for PVS. While all of these materials have its own advantages and disadvantages the autologous rectus fascia sling is the most preferred material for PVS [5].

Although PVS is an effective surgical method; complications including urinary retention and voiding difficulties including urgency and urge incontinence can be devastating [3, 6, 7]. In this study we aimed to review complications after autologous rectus fascia PVS and their managements.

Methods

Between June 2014 and January 2016, a total of 21 patients who underwent PVS in four different referral center were investigated retrospectively. All of the patients either had intrinsic sphincter deficiency

(ISD) or recurrent stress urinary incontinence. The patients with mixed urinary incontinence or neurogenic bladder were not included in the study. Urodynamics study was performed to all patients preoperatively, and an abdominal leak point pressure threshold of 60 cm H₂O was considered as an indicator of ISD.

The age, previous surgical history and daily pad use of the patients were recorded. The patients completed "Urogenital Distress Inventory 6 (UDI-6)" and "Incontinence Impact Questionnaire (IIQ-7)" at preoperative and postoperative 6th month. In addition, complications of the PVS surgeries, and management of the complications were stated.

Operation Technique

The patient was placed in lithotomy position and a 18-F Foley catheter was implanted.

1. Graft Retrieval

A 6-7 cm long phannenstiell incision was performed 2 cm above the symphysis pubis for retrieving an autologous fascia. Rectus fascia was marked for to have a graft of 8 cm x 2 cm with transverse or longitudinal incision (Figure 1). Rectus fascia was elevated from one edge, and separated from the underlying rectus muscle with the aid of a scalpel or electrocautery to harvest graft material. The graft material was spread on the sterile drape, and it was cleaned from overlying fat, and perifascial tissues. Fixation sutures were passed through both ends of the graft with 1-0 PDS or 1-0 polypropylene sutures (Figure 2).

2. Vaginal Approach

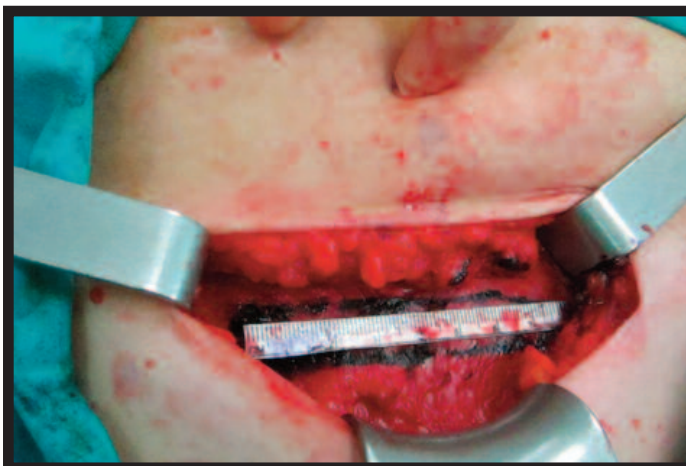

Figure 1. Rectus fascia was marked for to have a graft of 8 cm x 2 cm

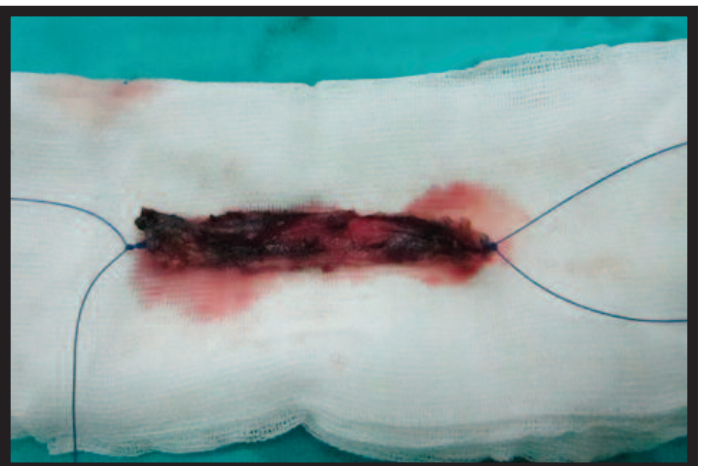

Figure 2. Fixation sutures were passed through both ends of the graft with 1-0 PDS.

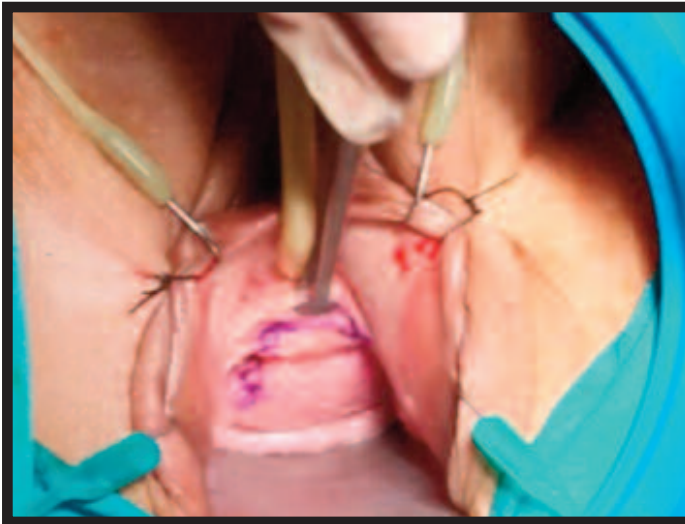


Figure 3. An inverted "U" incision.

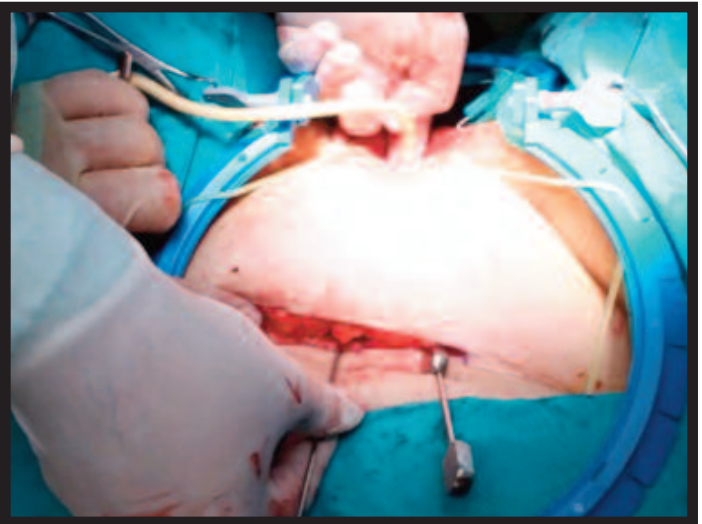


Figure 4. Stamey needles were inserted through abdominal incision, and were brought out of the vaginal incision.

Initially, 0.9% saline was injected into vaginal epithelium to achieve periurethral hydrodistension, and to facilitate dissection of tissues. An inverted U incision was performed so as to advance easily to the urethra, up to the level of bladder neck, endopelvic fascia, and then retropubic space (Figure 3). Immediately below the external meatus was retracted with an Allis clamp, and an incision was made starting from 2 cm below the external meatus up to the vaginal epithelium using a 15 G scalpel. With the aid of Metzenbaum scissors, and Allis clamps, subepithelial layer of vagina was dissected for to create vaginal epithelial flaps.

After creation of adequate-sized lateral flaps, further dissection to the ischiopubic rami was performed which facilitated perforation of endopelvic fascia. The bladder was always completely evacuated so as to prevent perforation of the bladder with Stamey needles. Beneath the ischiopubic ramus, and superior to the dissected area, metzenbaum scissors were held with its tips pointing towards the ipsilateral shoulder, and advanced strictly medially to perforate endovesical fascia. Retropubic space was dissected bluntly with finger and passage between retropubic, and infrapubic spaces was achieved.

3. Placement of PVS

Stamey needles were inserted through abdominal incision, and carefully advanced just underneath the symphysis pubis, then it was passed lateral to the bladder, and brought out of the vaginal incision (Figure 4). After passing the needles through the both incisions, cystoscopy was performed using firstly 30o , and then 70o optical lenses to confirm lack of

inadvertent bladder perforation with needles. Then the sutures which were placed at the edge of the graft were passed through needle holes of Stamey needles, and midpart of the graft was held with a clamp to prevent slipping of the midline of the sling. The sutures were pulled backward together with the needle, and brought out through the inserion points of the needles, and held with hemostatic clamps.

In the area of vaginal dissection, graft material was fixed to the periurethral area with 4-0 polyglycan sutures from two points. Following hemostasis, vaginal incision was closed with 2-0 polyglycan sutures. Then both sutures were pulled up through the abdominal incision. Proximal urethra was inspected with cystoscopy using 30-degree optical lenses to determine if adequate closure was achieved. If adequate closure was realized, then sutures from left, and right side were tied to each other. In most of the cases two fingers could be snugly inserted between the knot, and the rectus fascia, which meant adequate urethral closure. Then abdominal incision was closed, and estrogen containing sponges were placed into vagina.

Statistical Analysis

Average, frequency and percentage values were given as descriptive statistics. SPSS for Windows Version 11.5 (Chicago, Illinois) was used for analyses. The Mann-Whitney U test and chi-squared test were used to determine the difference within groups as for continuous and categorical variables, respectively. A $p < 0.05$ value was accepted as significant.

Results

There was no intraoperative complication. The mean age of the women was 54.9 ± 12.32 (range; 36-76) years. Six (28.5%) patients had a history of previous anti-incontinence surgery and 15 (71.4%) were naïve for surgery. The mean pad use was decreased from 4.04 ± 0.95 to 0.95 ± 0.86 ($p=0.0001$) at postoperative follow up. There was a significant improvement in comparison of preoperative and postoperative UDI-6 and IIQ-7 scores. The mean preoperative UDI-6 score was decreased from 6.66 ± 2.09 to 2.09 ± 1.22 ($p=0.0001$) at postoperative sixth month and the mean preoperative IIQ-7 score was decreased from 16.8 ± 1.16 to 5.09 ± 4.21 ($p=0.0001$) at postoperative sixth month.

Thirteen (62%) patients out of 21 had no complications. One (4.76%) patient had abdominal hernia at postoperative 2nd year and hernia was repaired by a general surgeon. Recurrent SUI was developed in one (4.76%) naïve woman and in one (4.76%) woman with a history of trans obturator tape. Both patients were scheduled for urethral injection. Two (9.52%) patients had urgency incontinence and their symptoms improved after prescription of antimuscarinics.

Three (14.28%) patients had an increased post-micturational residual (PMR) (150-200 ml). In one of them the abdominal sutures were cut at early postoperative period and she was able to void and there was no recurrence for SUI. The other two patients had decreased PMR at the 3rd month follow-up (50-100ml).

Two (9.52%) patients had urinary retention. While one patient was able to void after 5 weeks course catheterization, the other woman managed with clean intermittent catheterization (CIC). Initially this woman underwent urethrolisis. The operation was extremely difficult due to the scar tissue surrounding the bladder neck. She continued to have CIC after failure of urethrolisis. Afterwards she underwent sacral neuromodulation and the frequency of CIC was decreased from 6 to 3 times daily. She was able to void an amount of 150 ml in an obstructive pattern at uroflowmetry. An another course of urethrolisis was planned to the patient but she become pregnant and the sacral neuromodulation was turned off.

Discussion

The surgical outcomes following surgery has been well established in the literature. Due to discrepancies in definition of a successful operation, the success rates varies between 47% and 90% [4]. In the present study the objective success which was defined as no leakage on pelvic examination found as 90.4% and there was a significant improvement in scores of UDI-6 and IIQ-7 when compared preoperatively and postoperatively. While confirmation of no SUI on physical examination is one of the important goals of the operation; patient satisfaction is another important aspect of success. Correction of SUI does not always indicate a good outcome. As an example a woman with a de novo urge incontinence may have even more bother than her previous condition. Therefore, it is essential to achieve good results in all aspects of lower urinary tract symptoms including continence, storage and voiding.

Failure or recurrence of PVS is a very difficult condition and there is no agreement on the next step in the literature [8-12]. Patients may find it difficult to have another major surgery in that situation. We offered urethral injections to our patients with recurrence as a minimal invasive alternative to avoid any further complications.

PVS surgery is prone to produce complications such as retention, dysfunctional voiding, urgency and wound problems. The rate of overall complications is reported between 3% and 46% in most of the large series [8-12]. Also, in the largest series in the literature, Blavias Blaivas and Chaikin [13] reported less than 1% of complications requiring catheterization or urethrolisis. In the present study the overall complication rate was 38%. These complications included abdominal hernia in one, urgency urinary incontinence in two, increased PMR in three and complete urinary retention in two patients. The reported rate of complications can differ in various studies similar to the variations in definition of success. In most of the studies transient retention or increased PMR was not mentioned as a complication. This can be the reason why the overall complication rate is high.

The rectus fascia is the most common autologous material used for PVS. In the present study we only chosen the rectus fascia for sling. Although it is a more convenient way of harvesting fascia than fascia lata, wound infections, seroma or hernia can occur in a rate of 0.8-1% [13, 14]. In our study there are not infectious complications of the rectus fascia. However, in one patient abdominal hernia developed two years

after the surgery and surgical repair was employed by a general surgeon.

Athanopolos *et al.* [12] reported a total complication rate of 29.2% out of 264 patients. The rate of complications was high in sister trial. The complication rates found in this study was in accordance with the other reported series. Of course the surgical experience is the most important factor for complications. While experienced surgeons such as Blaivas and Chaikin [13] reported prolonged retention rates of %1 this can be higher up to in other series. Although PVS has been recognized as a rescue surgery for those with an unsuccessful attempt of incontinence surgery, the majority of our cases were naïve patients. The common reasons for PVS as the primary surgery were: i) surgeons preferences, ii) patient preferences. Today MUS has been the treatment of choice in most of the forms of SUI and PVS is reserved for the recurrent cases. In the present study 71.4%) of the patients were naïve patients for SUI

De novo urgency is one of the frequent complications of PVS surgery. Although the underlying pathology is not fully understood bladder outlet obstruction and nerve damage caused by the sling may have a role in development of de novo urgency [3]. In our series two (9.52%) women of the patients had de novo urgency. This rate is consistent with the other series published [3, 6, 10]. These patients were treated with anticholinergics. Before initiation of the treatment they were checked for PMR and afterwards they were followed up cautiously. The response rate after anticholinergics in de novo urgency. Of course, urinary retention is the one of the most devastating complications of PVS surgery. If necessary urethrolisis should be accomplished ASAP, the delay can result in no a retention but PMR [15].

The autologous PVS can be done either with the rectus fascia or fascia lata. In most of the circumstances rectus fascia is the first choice because of the familiarity of the abdomen anatomy for the urologist. Multi-center contribution to the present study represents one of its strengths. However the small number of patients and limited follow-up are the major drawbacks of this study.

Conclusions

In conclusion, PVS surgery carries increased risk of complications. The risk of complications should be

counterbalanced with the benefits of this surgery. The patients should be informed about the possible complications of this surgery in the long run.

Informed consent

Written informed consent was obtained from the patient for the publication photographs used in this study.

Conflict of interest

The authors disclosed no conflict of interest during the preparation or publication of this manuscript.

Financing

The authors disclosed that they did not receive any grant during conduction or writing of this study.

References

- [1] Anger JT, Weinberg AE, Albo ME, Smith AL, Kim JH, Rodriguez LV, et al. Trends in surgical management of stress urinary incontinence among female Medicare beneficiaries. *Urology* 2009;74:283-7.
- [2] Rac G, Younger A, Clemens JQ, Kobashi K, Khan A, Nitti V, et al. Stress urinary incontinence surgery trends in academic female pelvic medicine and reconstructive surgery urology practice in the setting of the food and drug administration public health notifications. *Neurourol Urodyn* 2017;36:1155-60.
- [3] Mitsui T, Tanaka H, Moriya K, Kakizaki H, Nonomura K. Clinical and urodynamic outcomes of pubovaginal sling procedure with autologous rectus fascia for stress urinary incontinence. *Int J Urol* 2007;14:1076-9.
- [4] Bang SL, Belal M. Autologous pubovaginal slings: back to the future or a lost art? *Res Rep Urol* 2016;8:11-20.
- [5] Bayrak O, Osborn D, Reynolds WS, Dmochowski RR. Pubovaginal sling materials and their outcomes. *Turk J Urol* 2014;40:233-9.
- [6] Cross CA, Cespedes RD, English SF, McGuire EJ. Transvaginal urethrolisis for urethral obstruction after anti-incontinence surgery. *J Urol* 1998;159:1199-201.
- [7] Sarver R, Govier FE. Pubovaginal slings: past, present and future. *Int Urogynecol J Pelvic Floor Dysfunct* 1997;8:358-68.
- [8] Albo ME, Richter HE, Brubaker L, Norton P, Kraus SR, Zimmern PE, et al. Burch colposuspension versus fascial sling to reduce urinary stress incontinence. *N Engl J Med* 2007;356:2143-55.
- [9] Hou JC, Lemack GE. The role of fascial slings in the treatment of stress urinary incontinence in women: a 2013 update. *Curr Urol Rep* 2013;14:247-52.
- [10] Chaikin DC, Rosenthal J, Blaivas JG. Pubovaginal fascial sling for all types of stress urinary incontinence: long-term analysis. *J Urol* 1998;160:1312-6.
- [11] Cross CA, Cespedes RD, McGuire EJ. Our experience with pubovaginal slings in patients with stress urinary incontinence. *J Urol* 1998;159:1195-8.
- [12] Athanasopoulos A, Gyftopoulos K, McGuire EJ. Efficacy and preoperative prognostic factors of autologous fascia rectus sling for treatment of female stress urinary incontinence. *Urology* 2011;78:1034-8.
- [13] Blaivas JG, Chaikin DC. Pubovaginal fascial sling for the treatment of all types of stress urinary incontinence: surgical technique and long-term outcome. *Urol Clin North Am* 2011;38:7-15.
- [14] Morgan TO, Jr., Westney OL, McGuire EJ. Pubovaginal sling: 4-year outcome analysis and quality of life assessment. *J Urol* 2000;163:1845-8.
- [15] South MM, Wu JM, Webster GD, Weidner AC, Roelands JJ, Amundsen CL. Early vs late midline sling lysis results in greater improvement in lower urinary tract symptoms. *Am J Obstet Gynecol* 2009;200:564.e1-5.