

Left atrial myxoma combined with coronary artery disease in an elderly patient

Gündüz Yümün, Selami Gürkan, Okan Donbaloğlu

Department of Cardiovascular Surgery, Namık Kemal University School of Medicine, Tekirdağ, Turkey

ABSTRACT

Cardiac myxoma associated with coronary artery disease is a rare pathology in an elderly patient. Herein we present an 81-year-old woman undergoing simultaneous surgical treatment for left atrial myxoma combined with coronary artery disease. The postoperative course of the patient was uneventful. The initial removal of mass should be performed to prevent systemic embolization of tumor fragments.

Eur Res J 2018;4(2):129-131

Keywords: Left atrial mass, coronary artery disease, elderly

Introduction

Atrial myxomas are accounting for nearly half of primary cardiac tumors in adults [1]. Approximately 75-90% of cardiac myxomas are located in the left atrium, mainly adhered to the atrial septum near the fossa ovalis [2, 3]. In most cases they encountered in female patients with 40-60 years old [1]. The size of the myxoma is directly proportional to the severity of the patient's symptoms [4]. Coexistence of coronary artery disease and myxoma is a rare condition and, it is reported in a limited number of case reports [5-8]. We describe a rare case with simultaneous left atrial myxoma and coronary artery disease in an elderly woman with shortness of breath and chest pain.

Case Presentation

An 81-year-old woman admitted to hospital with shortness of breath and chest pain. Upon physical

examination, the patient had a heart rate of 78 beats/min, and a regular blood pressure of 170/70 mmHg. In the clinical history, she had undergone coronary angiography 3 years ago and coronary artery disease had been detected. There was no previous echocardiography report.

The systemic examination of the patient was normal. The electrocardiogram was also normal. Echocardiographic evaluation identified left ventricular apical akinesis with an ejection fraction of 45% and showed a left atrial mass 38×32 mm in sizes attached to the interatrial septum of the left atrium without obstruction.

Coronary angiography showed plaques with non-critical stenosis in the left circumflex coronary artery, an ostial stenosis of 90% of the right coronary artery, but 90% stenosis at the proximal portion of the left anterior descending coronary artery (Figure 1).

After general anesthesia surgery was performed via a median sternotomy. The aorta, and superior and inferior venae cava were cannulated, and

Address for correspondence:

Gündüz Yümün, MD., Associate Professor, Namık Kemal University School of Medicine, Department of Cardiovascular Surgery, Tekirdağ, Turkey.

E-mail: gunduzyumun@gmail.com

Received: October 23, 2017; Accepted: November 25, 2017; Published Online: December 1, 2017

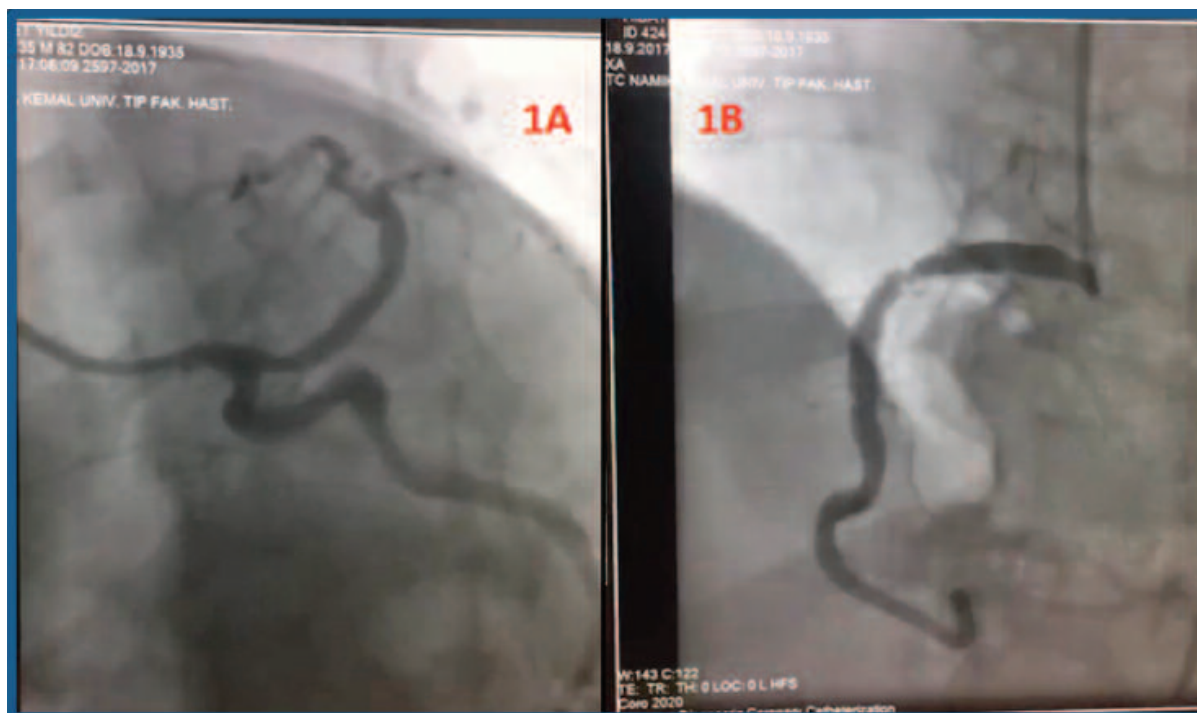


Figure 1. Coronary angiography shows demonstrating severe stenosis in the left anterior descending coronary artery (A) and the right coronary artery (B).

cardiopulmonary bypass with moderate hypothermia (28-30°C) was instituted. To minimize the risk of developing perioperative embolism the heart was gently handled during the operation. First the left atrial mass excised via interatrial groove approach (Figure 2). Excision of the tumor was performed with its pedicle originated from the left side of the atria. We performed coronary artery bypass grafting after the closure of the left atriotomy. For coronary revascularization of left descending coronary artery the internal thoracic artery was used and a saphenous

vein graft anastomosed to aorto-right coronary position. The postoperative course was uneventful without any complication.

Discussion

We have presented a rare case of concomitant atherosclerotic coronary artery disease and left atrial myxoma. Moreover, this patient was the oldest patient

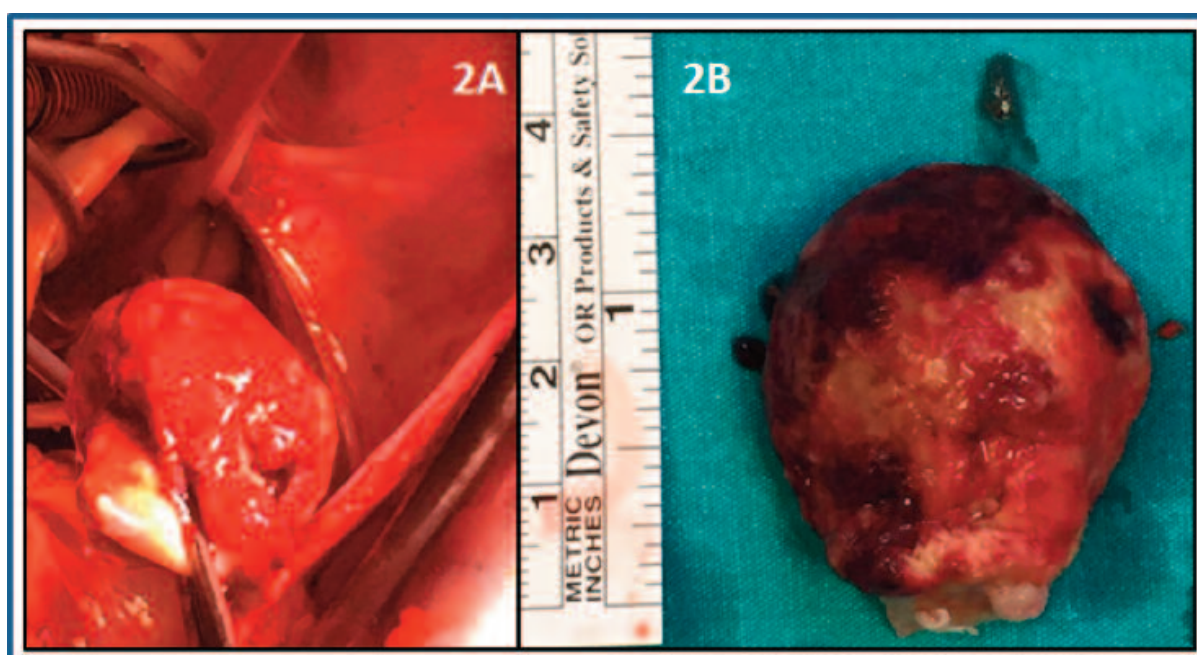


Figure 2. Appearance of the atrial mass during surgical excision (A). Macroscopic view of the surgically removed myxoma (B).

with coronary artery disease associated myxoma according to literature review. Atrial myxomas are the most common primary heart tumors [2, 3]. However, the incidence of atrial myxomas ranges between 0.5 and 1 per million of population/year and mean age of presentation has been reported between 40 to 60 years [1].

Left atrial myxoma may or may not produce characteristic findings on physical examination. The myxoma symptoms depend on mitral valve obstruction or distal organ embolization [4]. Embolization is generally seen in central nervous system. But other organs such as the liver, spleen, kidney, retina, coronary vessels, and distal arterial tree can be affected [4]. Chest pain and dyspnea were the major symptoms of the patient. Clinical findings were thought to be the result of partial cardiac obstruction in addition to coronary artery disease. In case of acute coronary syndromes and left heart myxoma, coronary embolization should always be considered [5]. The incidence of coronary embolization of myxomas is 0.06%. There was no evidence of major distal embolism in our patient. She had angina and shortness of breath at the same time. So we decided to operation because of clinical deterioration.

The prevalence of coronary atherosclerotic disease in patients with myxoma ranges between 20.3% and 36.6% [6-9]. In this report the patient had coronary artery disease according to coronary angiography 3 years ago. But myxoma not reported in previous echocardiography note.

Conclusions

Coronary angiography is required in elderly patients who will undergo other cardiac operations

because of the risk of synchronous coronary artery disease. Similarly, echocardiography is also required in patients with coronary artery disease, because of the risk of synchronous cardiac lesion, as seen in our case.

Informed consent

Written informed consent was obtained from the patient for the publication of this case report.

Conflict of interest

The authors declared that there are no potential conflicts of interest with respect to the research, authorship, and/or publication of this article.

References

- [1] Bhan A, Mehrotra R, Choudhary SK, Sharma R, Prabhakar D, Airan B, et al. Surgical experience with intracardiac myxomas: long-term follow-up. *Ann Thorac Surg* 1998;66:810-3.
- [2] Moyssakis I, Anastasiadis G, Papadopoulos D, Margos P, Votteas V. Second recurrence of cardiac myxoma in a young patient: a case report. *Ann Thorac Surg* 2005;101:501-2.
- [3] Toktaş F, Yavuz Ş, Özsin KK, Sanrı US, Türk T, Göncü MT. Cardiac myxomas: an analysis of 39 patients. *Eur Res J* 2017;3:227-33.
- [4] Nurözler F, Tandoğan A, Yamak B. [Huge left atrial myxoma with minimal symptoms: case report]. *Turk Gogus Kalp Dama* 2003;11:52-3. [Article in Turkish]
- [5] Fang BR, Chang CP, Cheng CW, Yang NI, Shieh MC, Lee N. Total detachment of cardiac myxoma causing saddle embolization and mimicking aortic dissection. *Jpn Heart J* 2004;45:359-63.
- [6] Kocaturk H, Karaman A, Bayram E, Çolak MC, Yurtman V. Left atrial myxoma and concomitant atherosclerotic coronary artery disease. *Eurasian J Med* 2009;41:202-4.
- [7] Erdil N, Ates S, Cetin L, Demirkilic U, Sener E, Tatar H. Frequency of left atrial myxoma with concomitant coronary artery disease. *Surg Today* 2003;33:328-31.
- [8] Yavuz S, Toktas F, Eris C, Ata Y, Turk T, Goncu T. Left atrial mass in a patient with previous coronary artery bypass grafting. *Journal-CVS* 2014;2:7-9.
- [9] Gismondi RA, Kaufman R, Correa GA, Nascimento C, Weitzel LH, Reis JO, et al. [Left atrial myxoma associated with obstructive coronary artery disease]. *Arq Bras Cardiol* 2007;88:e1-3. [Article in Portuguese]