

Journal of Surgery and Medicine

e-ISSN: 2602-2079

A forgotten approach after cardiac arrest due to acute myocardial infarction: Neuroprotective therapeutic hypothermia

Akut miyokard infarktüsüne bağlı kardiyak arrest sonrası unutulmuş yaklaşım: Nöroprotektif terapötik hipotermi

Abdullah Özçelik¹, Yakup Alsancak¹, Ahmet Seyfeddin Gürbüz¹, Abdullah İçli¹, Ahmet Soylu¹

¹ Necmettin Erbakan University, Meram
Medicine Faculty Hospital, Division of
Cardiology, Konya, Turkey

Abstract

In patients with spontaneous circulation after cardiopulmonary resuscitation, therapeutic hypothermia is defined as the reduction of body temperature to 32-34 °C within the first 4-6 hours for neuroprotective purposes and to be maintained at this level for 12-24 hours after reaching the target temperature. Therapeutic hypothermia has been practiced since the 1940s. The aim of therapeutic hypothermia is to reduce cerebral edema, convulsive activity, metabolic demand and associated complications by providing low body heat. Therapeutic hypothermia is applied to increase life expectancy and quality of life. In out-of-hospital cardiac arrest, should be performed in comatose patients where initial rhythm is ventricular fibrillation and spontaneous circulation is returned. Herein, we present a 44 years old patient who had an aborted sudden cardiac death due to acute myocardial infarction and performing cardiopulmonary resuscitation for 30 minutes and discharged after 6 days with a successful therapeutic hypothermia.

Keywords: Cardiac arrest, Therapeutic hypothermia, External cooling

Öz

Kardiyopulmoner resüstasyon sonrası spontan dolaşım sağlanan hastalarda, nöroprotektif amaçlı ilk 4-6 saat içinde vücut ısısının 32-34 °C'ye kadar indirildiği ve hedef ısıya ulaşıldıktan sonra 12-24 saat bu düzeyde tutulmasına terapötik hipotermi denir. Terapötik hipotermi 1940'lardan bu yana uygulanmaktadır. Terapötik hipotermi amacı, düşük vücut ısısı sağlayarak serebral ödem, konvülsiyon aktivitesi, metabolik talebi ve bunlarla ilgili gelişecek komplikasyonları azaltmaktır. Terapötik hipotermi yaşam beklentisi ve hayat kalitesini artırmak için uygulanır. Hastane dışı kardiyak arrestlerde başlangıç ritmin ventriküler fibrilasyon olduğu ve spontan dolaşımın geri döndüğü komatöz hastalarda yapılmalıdır. Burada, akut miyokard enfarktüsü nedeniyle ani kardiyak ölümlü sonuçlanan ve 30 dakika süreyle kardiyopulmoner resüstasyon uygulanan ve 6 gün sonra başarılı bir terapötik hipotermi sonrası taburcu edilen 44 yaşında bir hasta sunuyoruz.

Anahtar kelimeler: Kardiyak arrest, Terapötik hipotermi, Eksternal soğutma

Introduction

Cardiovascular diseases are the most common cause of death in the world and in our country. The most important problem encountered after spontaneous circulation in cardiopulmonary resuscitation (CPR) patients is poor survival of the neurological condition and deterioration of prognosis, decrease of life quality and life expectancy. The mortality rate in out-of-hospital cardiac arrest in USA is as low as 65-95% and the rate of neurological sequelae recovery in survivors is as low as 10-20% [1]. The most common cause of death in out-of-hospital cardiac arrest is neurological damage. Neurological damage also contributes to mortality in in-hospital cardiac arrest [2]. Hypothermia in resuscitation is a topic that is being discussed so much today, to ensure that patients recover neurologically after resuscitation, to try to improve their life expectancy and quality of life. Patient with spontaneous circulation after CPR has been administered is called therapeutic hypothermia to maintain body temperature at 32-34°C within the first 4-6 hours to achieve a successful neurological reversal and 12-24 hours when the target temperature is reached [3]. Hyperthermia is an expected condition after arrest and worsens neurological outcomes [4]. Therapeutic hypothermia improves neurological outcomes when combined with standard post-resistive maintenance [5].

Corresponding author / Sorumlu yazar:

Abdullah Özçelik

Adress: Necmettin Erbakan Üniversitesi, Meram
Tıp Fakültesi Hastanesi, Kardiyoloji kliniği,
Meram, Konya, Türkiye
e-Mail: drabdullahozcelik@gmail.com

Informed Consent: The author stated that the
written consent was received from the patient who
was presented in this study.

Hasta Onamı: Yazar çalışmada sunulan hastadan
yazılı onam alındığını ifade etmiştir.

Conflict of Interest: No conflict of interest was
declared by the authors.

Çıkar Çatışması: Yazarlar çıkar çatışması
bildirmemişlerdir.

Financial Disclosure: The authors declared that
this study has received no financial support.

Finansal Destek: Yazarlar bu çalışma için finansal
destek almadıklarını beyan etmişlerdir.

Previous presentation: Presented in the 33rd
Internationally Participated Turkish Cardiology
Congress, on 5-8 October 2017, in Antalya,
Turkey.

Received / Geliş tarihi: 01.12.2017
Accepted / Kabul tarihi: 27.01.2018
Published / Yayın tarihi: 01.02.2018

Copyright © JOSAM



How to cite / Atf için: Özçelik A, Alsancak Y, Gürbüz AS, İçli A, Soylu A. A forgotten approach after cardiac arrest due to acute myocardial infarction: Neuroprotective therapeutic hypothermia. J Surg Med. 2018;2(1):32-34.

Herein, we aimed to draw attention to therapeutic hypothermia with present a 44 years old patient who had an aborted sudden cardiac death due to acute myocardial infarction and performing CPR for 30 minutes and discharged after 6 days with a successful therapeutic hypothermia.

Case Presentation

A 44-year-old male patient with unknown systemic disease has found by emergency team after sudden loss of consciousness with cardiac arrest at work. A cardiac rhythm was provided after 30 minutes of CPR. The patient brought to the emergency service, because of electrocardiogram compatibility with the acute anterior MI, the patient was taken immediately to the coronary angiography laboratory. Coronary angiography showed, total occlusion of left anterior descending coronary artery (LAD) after first diagonal artery, first obtuse marginalis (OM1) with acute severe thrombotic, with normal circumflex coronary artery and right coronary artery are normal (Figure 1A-B). A drug-coated stent was immediately implanted for proximal LAD lesion (Figure 1C). Then, due to the patient was in the shock table, drug-coated stents were implanted in the same procedure to the CX OM1 lesion (Figure 1D). The patient's blood pressure improved after primary coronary intervention, and then he was taken into coronary intensive care unit. Patient was mechanically ventilated and had no painful stimulus. Pupillary fixation, no brainstem reflexes were obtained and the bilateral basal skin reflex was unresponsive. Glasgow Coma Score was detected as 3. 24 hours of sedation and therapeutic hypothermia was scheduled for the patient with involuntary contractions. External cooling was performed in order to avoid the table of pulmonary edema due to the presence of acute myocardial infarction and a 25% ejection fraction in the echocardiography. Hypoxic brain damage was defined by neurological department and mannitol was initiated in the direction of neurology. Brain computed tomography (CT), brain diffuse magnetic resonance (MR) and electroencephalography (EEG) were planned. Brain CT and diffusional MR were reported with in normal range. EEG was consistent with the presence of ischemic hypoxic encephalopathy and focal epileptic activity. At the end of the 24-hour period, the patient, who had been warmed up gradually and was sedated, was extubated after 48 hours due to the consciousness opening. The patient was a conscious normal and co-operative patient, and neurology was consulted again because of short-term episodes of consciousness change. A neurologically evaluated patient was offered antiepileptic drug and polyclinic control. In the control echocardiography, the ejection fraction was found to be 35% and the major valve pathology was not observed. On the 8th day of follow-up, the patient's conscious, orientation, motor and sensory examination were normal. The patient was discharged with a planned cardiac rehabilitation program.

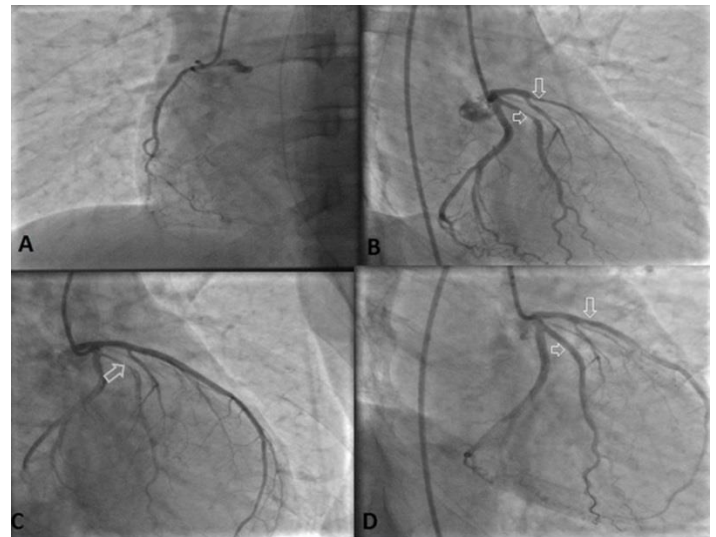


Figure 1: A- Right coronary artery without any stenosis B –A totally occluded left anterior descending artery and obtuse marginal coronary artery with severe thrombotic stenosis (arrows), C-Left anterior descending coronary artery after stent implantation (arrow) D- Obtuse marginal coronary artery after stent implantation without lesion (arrow)

Discussion

Therapeutic hypothermia has been practiced since the 1940s. Initial experiments had been carried out at low temperatures (<30 °C). It requires serious intensive care follow-up with the emergence due to many side effects at low temperatures. When the central temperature drops below 32°C, fatal arrhythmias and bradycardias can develop due to a decrease in the depolarization of the cardiac message cells [1]. In the 1990s, brain protection could not be adequately maintained with pharmacological agents, causing hypothermia after cardiac arrest to resurface [6]. Between 1980 and 1990 animal experiments and small clinical trials showed that less side effects were observed in 32-35°C [7]. In recent years, studies on this subject have begun to increase. We also followed the body temperature to 32-36 °C when the patient was hypothermic.

The patient with the suitable indication with spontaneous circulation after cardiopulmonary resuscitation has been administered should be given 12-24 hours (mean 18 hours) after the body temperature has been lowered to 32-34 °C within the first 4-6 hours to achieve a successful neurological reversal, the process of keeping it at this level is called therapeutic hypothermia. The aim of therapeutic hypothermia is to reduce cerebral edema, convulsive activity, metabolic demand and associated complications by providing low body heat. Effected by deceleration in dexterous enzymatic reactions, inhibition of free radical reactions, protection of lipoprotein membrane flow, reduction in oxygen demand, reduction in intracellular acidosis, inhibition of synthesis, release and uptake of excitatory neurotransmitters [8]. Our patient underwent therapeutic hypothermia at the 3rd hour of cardiac arrest and continued for 24 hours. Then the patient was gradually heated.

Therapeutic hypothermia is a useful therapeutic approach for the protection of the brain and other organs in patients with coma when spontaneous circulation returns. It is applied to increase the quality of life and life expectant. In out-of-hospital cardiac arrests, initial rhythm ventricular fibrillation (VF) should be performed in comatose patients returning spontaneous circulation, any initial rhythm after in-hospital

arrest, pulseless electrical activity outside the hospital, or in adult comatose patients with asystole and spontaneous circulation returned. Patients to whom therapeutic hypothermia can be administered should be started within 5-15 minutes after CPR collapse, CPR lasting for 60 minutes, return to normal sinus rhythm after spontaneous circulation, mean arterial pressure (MAP) >60 mmHg and/or systolic arterial pressure (SAP) >90 mmHg, eyes spontaneously closed, Glasgow coma scales below 8. Given these strict criteria, only 10% of cases can be applied. The patient under 18 years of age, be pregnant, have an MAP <60 mmHg and/or SAP <90 mmHg, have coagulopathy (seeing for warfarin treatment) or thrombocytopenia, hypothermic for the patient after cardiac arrest (body temperature <30°C) (drug overdose, head trauma, stroke, status epilepticus), terminal illness, uncontrolled arrhythmia in the patient is contraindicated for the application of therapeutic hypothermia [9-10]. Active control of post-arrhythmic body temperature should be achieved as soon as possible and hypothermia should be actively controlled even in patients who are mildly hypothermic at the time of admission [11]. Although hypothermia is provided by various methods, these methods do not have the advantages of each other, and intravenous infusion of cold fluid and simultaneous surface cooler are the most preferred methods. During the therapeutic hypothermia, the body core temperature must be constantly monitored. The gold standard method is central venous heat measurement. The reheating must be done in degrees not exceeding 0.5°C /hour. Otherwise, rapid heating can cause electrolyte abnormalities (hyperkalemia), brain edema, convulsions and other problems. We used to therapeutic hypothermia because of the absence of an out-of-hospital asystole patient who returned spontaneous circulation and an adult comatose patient. External cooling was applied to avoid volume load and pulmonary edema due to poor cardiac systolic function.

Such patients need a multidisciplinary approach by a team consisting of cardiology, anesthesia, and neurologist to ensuring them benefit at the highest level. Cerebral damage after aborted cardiac arrest is an important cause of morbidity and mortality. In recent years, although therapeutic hypothermia has been reported to be useful in cardiac arrest cases due to non-VF rhythm problems, it is suggested that good prognosis rates are as low as 7-12% after therapeutic hypothermic application in these cases. Although the positive effect of hypothermia treatment on neurological prognosis, it is still not routinely applied [12]. Despite the need for new large randomized clinical trials, we wanted to draw attention to the fact that therapeutic hypothermia may have promising results in non-VF cardiac arrest cases such as asystole and that therapeutic hypothermia should be used more widely.

References

1. Polderman KH. Induced hypothermia and fever control for prevention and treatment of neurological injuries. *Lancet*. 2008;371(9628):1955-69.
2. Laver S, Farrow C, Turner D, Nolan J. Mode of death after admission to an intensive care unit following cardiac arrest. *Intensive Care Med*. 2004;30:2126-8.
3. Holzer M, Cerchiari E, Martens P, Roine R, Sterz F, Eisenburger P, et al. Mild therapeutic hypothermia to improve the neurologic outcome after cardiac arrest. *N Engl J Med*. 2002;346(22):1756.

4. Gebhardt K, Guyette FX, Doshi AA, Callaway CW, Rittenberger JC, Post Cardiac Arrest Service. Prevalence and effect of fever on outcome following resuscitation from cardiac arrest. *Resuscitation*. 2013;84:1062.
5. Arrich J, Holzer M, Havel C, Müllner M, Herkner H. Hypothermia for neuroprotection in adults after cardiopulmonary resuscitation. *Cochrane Database Syst Rev*. 2012;9:CD004128.
6. Wright WL, Geocadin RG. Postresuscitative intensive care: Neuroprotective strategies after cardiac arrest. *Semin Neurol*. 2006;26:396-402.
7. Bailitz J, Hansen M, Nelson M. Therapeutic Hypothermia in the Emergency Department .*The Practical Journal of Emergency Physicians. Emergency Medicine Reports*. 2009;30(20):14.
8. Busto R, Globus MY, Dietrich WD, Martinez E, Valdes I, Ginnberg MD. Effect of mild hypothermia on ischemia-induced release of neurotransmitters and free fatty acids in rat brain. *Stroke*. 1989;20:904-10.
9. Hypothermia after Cardiac Arrest Study Group; Holzer M. Mild therapeutic hypothermia to improve the neurologic outcome after cardiac arrest. *N Engl J Med*. 2002;346:549-56.
10. Bernard SA, Gray TW, Buist MD, Jones BM, Silvester W, Gutteridge G, et al. Treatment of comatose survivors of out-of-hospital cardiac arrest with induced hypothermia. *N Engl J Med*. 2002;346:557-63.
11. Nielsen N, Wetterslev J, Cronberg T, Erlinge D, Gasche Y, Hassager C, et al. Targeted Temperature Management at 33°C versus 36°C after Cardiac Arrest. *N Engl J Med*. 2013;369:2197.
12. Bernard S. Hypothermia after cardiac arrest: Expanding the therapeutic scope. *Crit Care Med*. 2009;37:S227-33.