

# Primary Cutaneous T-Cell Lymphoma in Children: Report of Two Cases

## Çocuklarda Primer Kutanöz T- Hücreli Lenfoma: İki Olgu Sunumu

Derya ÖZYÖRÜK<sup>1</sup>, Suna EMİR<sup>1</sup>, Hacı Ahmet DEMİR<sup>1</sup>, Esra KARAKUŞ<sup>2</sup>, Cengiz BAYRAM<sup>1</sup>, Bahattin TUNÇ<sup>1</sup>

<sup>1</sup>Ankara Children's Hematology and Oncology Hospital, Department of Pediatrics, Division of Pediatric Oncology, Ankara, Turkey

<sup>2</sup>Ankara Children's Hematology and Oncology Hospital, Department of Pathology, Ankara, Turkey



### ABSTRACT

Primary cutaneous lymphomas in children are rare and constitute a heterogeneous group in regard to histological subtype, clinical course and prognosis. Here, we present the clinical characteristics and outcomes of two children with primary cutaneous lymphoma with different histopathologic subtypes. They had been diagnosed as a skin abscess initially but had not responded to systemic antibiotherapy and dressing. After a biopsy and metastatic work up, one patient was diagnosed as primary cutaneous peripheral T-cell lymphoma, unspecified, and the other as primary cutaneous CD30 positive ALK negative anaplastic large cell lymphoma.

**Key Words:** Cutaneous anaplastic large cell lymphoma, Peripheral T-cell lymphoma, Primary cutaneous lymphoma

### ÖZET

Primer kutanöz lenfomalar çocukluk çağında çok nadir olup histolojik alt tip, klinik seyir ve prognoz bakımından farklılık gösterirler. Burada farklı histopatolojik özelliklere sahip iki primer kutanöz lenfoma olgusu sunulmaktadır. Her iki olgunun ortak özelliği sistemik antibiyotik ve pansuman tedavilerine yanıt vermeyen cilt apsesi ile başlamış olmalarıydı. Biyopsi ve evreleme çalışmalarından sonra bir olgu primer kutanöz periferik T hücreli lenfoma, tanımlanamayan, diğer olgu ise primer kutanöz CD30 pozitif ALK negatif anaplastik büyük hücreli lenfoma tanısı aldı

**Anahtar Sözcükler:** Kutanöz anaplastik büyük hücreli lenfoma, Periferik T hücreli lenfoma, Primer kutanöz lenfoma

### INTRODUCTION

The skin involvement may be a primary or secondary manifestation of non-Hodgkin lymphoma. The primary cutaneous lymphomas are divided into two groups as primary cutaneous T and B-cell lymphomas (1,2). In childhood, these are generally T-cell related and constitute a heterogeneous group in regard to histological subtype, clinical course and prognosis (2-4). Primary cutaneous T-cell lymphomas are lymphoproliferative diseases characterized by a clonal expansion of mature post-thymic T-cells that infiltrate the skin (4). The cutaneous T-cell lymphomas are divided into six different histological subtypes: mycosis fungoides and variants, Sézary syndrome, primary cutaneous CD30-positive lymphoproliferative disorders, subcutaneous panniculitis-like T-cell lymphoma, extranodal natural killer (NK)/T-cell lymphoma-nasal-type, and primary cutaneous peripheral T-cell lymphoma, unspecified (2-6). The primary cutaneous lymphomas are rare in childhood and there is limited data in the literature. Here, we present the clinical characteris-

tics and outcome of two children with primary cutaneous T-cell lymphoma presenting with similar clinical presentation but different histopathologic subtypes.

### CASE 1

A 2- year-old male presented with an erythematous and ulcerated mass on the left side of the face. The lesion had started after a trauma on his face and progressively enlarged during treatment with antimicrobial agents and dressings. No lymphadenopathy or organomegaly was observed on physical examination. However, a huge erythematous mass of 6x6 cm in diameter on the left of the face and scattered multiple subcutaneous nodules of various size from 0.5 to 2 cm were observed on the patient's upper and lower extremities (Figure 1A). Laboratory analyses showed normal complete blood count and serum chemistry values. Peripheral blood smear revealed no

atypical lymphocytes. The biopsy of the subcutaneous nodule in the right leg showed nodular and diffuse infiltrates with mostly medium-sized and somewhat large pleomorphic atypical cells extending from the superficial dermis to subcutaneous fat. Immunohistochemistry revealed that these atypical cells were positive for CD 45, CD3, CD 5, CD 8 and negative for ALK, CD30, EMA, CD4, CD56, LMP1. Histopathologic examination and immunohistochemical stains were interpreted as peripheral T-cell lymphoma, unspecified (Figure 1B). A metastatic work-up including computed tomography scan of the chest and abdomen, bone marrow, and cerebrospinal fluid examination demonstrated no evidence of involvement other than the skin. The patient was treated with the LMT-89 chemotherapy regimen that consists of vincristine, doxorubicin, prednisone, methotrexate, and 6-mercaptopurine for one year. Follow-up physical examinations and imaging procedures showed no evidence of disease. The patient still remains in complete remission more than three and a half years after the chemotherapy.

## CASE 2

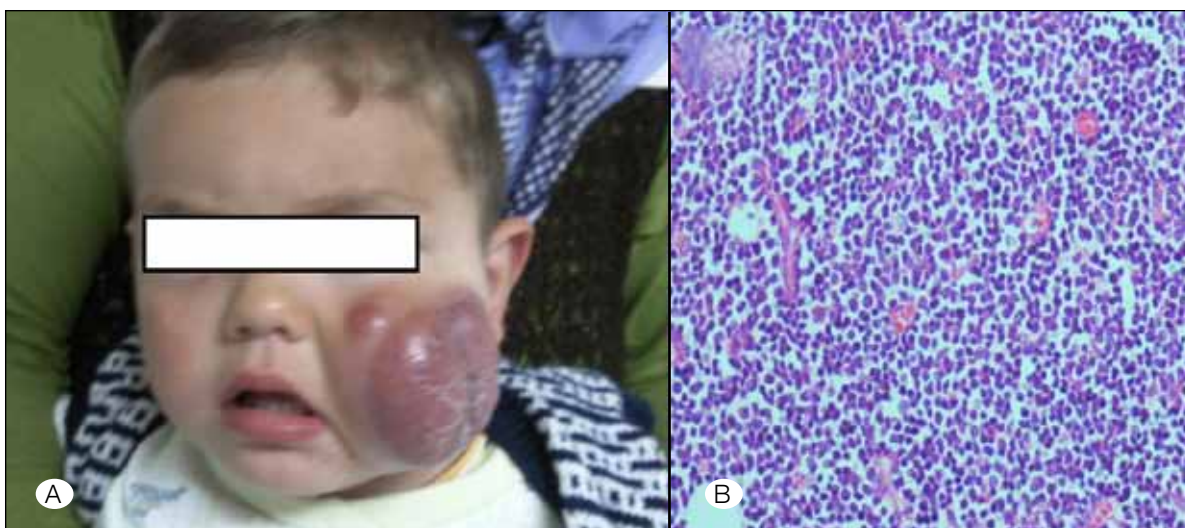
A 6-year-old male was referred to our clinic because of an erythematous and ulcerated skin nodule that was localized in the epigastric region of the abdomen and was progressively enlarging despite antibiotic therapy. He had no complaint of fever, weight loss, or night sweats. Physical examination revealed an annular erythematous and ulcerated mass in the epigastric quadrant of the abdomen measuring 4.5x4 cm in diameter (Figure 2A). There were no lymphadenopathies or hepatosplenomegaly. The complete blood count and serum chemistry values were within normal limits. Abdominal and thoracic computed tomographies were negative for extracutaneous involvement other than a mass that invaded the dermis and subcutaneous structures in the epigastric region. Incisional biopsy of the lesion showed dense infiltrates of non-epidermotropic, large and irregularly-shaped lymphocytes with hyperchromatic nuclei and

mitoses extending from the superficial dermis to subcutaneous fat. Immunohistochemistry revealed that these atypical cells were positive for CD30, CD 2, CD8 and EMA and negative for ALK, CD15, CD20, ALK and LMP-1 (Figure 2B). Clinical, histopathological and immunohistochemical findings were consistent with CD30 positive anaplastic large cell lymphoma. The staging evaluation showed no evidence of extracutaneous involvement. The patient was treated with the anaplastic large cell lymphoma 99 protocol that consists of vincristine, doxorubicin, prednisone, methotrexate and 6-mercaptopurine. The large mass disappeared with minimal scar tissue after 3 cycles. Scar tissue was resected and pathology investigation revealed necrosis and fibrotic material. The patient still remains in complete remission more than one and a half years after the chemotherapy and surgery.

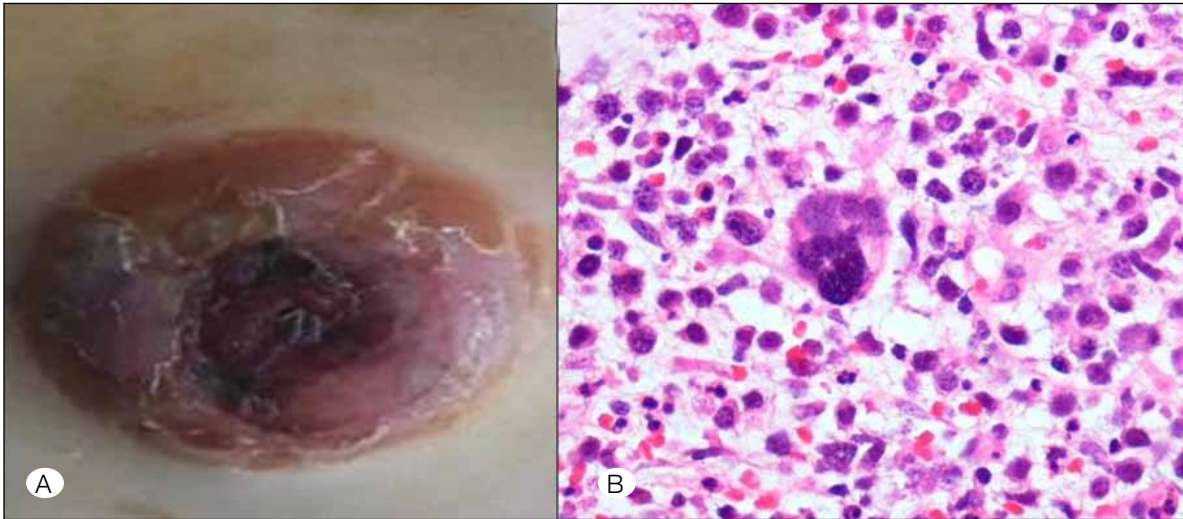
## DISCUSSION

Differentiating primary cutaneous lymphoma from systemic malignant lymphomas involving the skin is very important as they often have different clinical behaviour, prognosis and therapeutic approaches (2). We did not find any evidence of extracutaneous involvement with a metastatic work-up in the current cases.

Primary cutaneous peripheral T-cell lymphoma represents a phenotypically and prognostically heterogeneous group of cutaneous T-cell lymphomas that do not fit into any of well-defined subtypes. These include primary cutaneous CD4-positive small/medium T-cell lymphoma, primary cutaneous CD8-positive aggressive epidermotropic T-cell lymphoma, and primary cutaneous gamma/delta T-cell lymphoma (6). There is limited data regarding primary cutaneous peripheral T-cell lymphoma, unspecified, in children. In adults, Bekkenk et al. (7) evaluated that the clinicopathologic and immunophenotypic features of 82 patients with a CD30-peripheral T-cell lymphoma, unspecified, presenting in the skin and concluded that they



**Figure 1:**  
**A)** A skin abscess of patient who diagnosed with primary cutaneous peripheral T-cell lymphoma, unspecified at initial. **B)** The medium-sized and large pleomorphic atypical cells with hyperchromatic nuclei (HE, X400) of primary cutaneous peripheral T-cell lymphoma, unspecified.

**Figure 2:**

**A)** A skin abscess of patient who diagnosed with primary cutaneous anaplastic large cell lymphoma at initial. **B)** Large and irregularly shaped lymphocytes with hyperchromatic nuclei (HE, x400) of primary cutaneous anaplastic large cell lymphoma.

have an unfavorable prognosis irrespective of the presence or absence of extracutaneous disease at the time of diagnosis. On the other hand, they determined that cases with the CD3<sup>+</sup>CD4<sup>+</sup>CD8<sup>-</sup> phenotype and presenting with solitary or localized skin lesions have favorable prognosis as a new finding (7). Due to its rarity in children, there is no consensus about the management and treatment of primary cutaneous peripheral T-cell lymphoma, unspecified. The present case was treated with a systemic chemotherapy regimen successfully.

Although primary nodal CD30 positive anaplastic large cell lymphoma is common in childhood and adolescence, primary cutaneous CD30 positive lymphomas are rare in children. Primary cutaneous anaplastic large cell lymphoma is regarded by the WHO as a separate disease entity and belongs to the spectrum of primary cutaneous CD30 positive lymphoproliferative disorders (8). The characteristic feature of primary cutaneous ALCL is the presence of solitary or multiple red skin lesions that have a tendency to ulcerate, similar to our case. There are cases similar to our second patient treated with systemic chemotherapy in the literature. Ju et al. (9) reported a 7-year-old female with cutaneous ALCL. She had a boil-like mass located in the axillary region and was treated with five cycles of systemic chemotherapy. Tomaszewski et al. (10) reported that they used systemic chemotherapy consisting vincristine, cyclophosphamide, adriamycin, prednisolone in three cases with primary cutaneous ALCL. Daar et al. (11) reported a 15-year-old male with cutaneous ALCL and they preferred to use systemic chemotherapy.

In conclusion, these two cases were presented because of the rarity and similar clinical findings at diagnosis in childhood.

## REFERENCES

1. Fink-Puches R, Chott A, Ardigo M, et al. The spectrum of cutaneous lymphomas in patients less than 20 years of age. *Pediatr Dermatol* 2004;21:525-33.
2. Willemze R, Hodak E, Zinzani PL, Specht L, Ladetto M. Primary cutaneous lymphomas: ESMO Clinical Practice Guidelines for diagnosis, treatment and follow-up. *Ann Oncol* 2013;(24 Suppl 6): 149-54.
3. Querfeld C, Guitart J, Kuzel TM, Rosen ST. Primary cutaneous lymphomas: A review with current treatment options. *Blood Rev* 2003;17:131-42.
4. Oliveira MC, Pereira LB, Rodrigues PC, Sampaio KC, Oliveira BM, Viana MB. Initial cutaneous manifestation of lymphomas in children. *An Bras Dermatol* 2011;86:799-802.
5. Windsor R, Stiller C, Webb D. Peripheral T-cell lymphoma in childhood: Population-based experience in the United Kingdom over 20 years. *Pediatr Blood Cancer* 2008;50:784-7.
6. Hung TY, Lin YC, Sun HL, Liu MC. Primary cutaneous anaplastic large cell lymphoma in a young child. *Eur J Pediatr* 2008;167: 111-3.
7. Bekkenk MW, Vermeer MH, Jansen PM, van Marion AM, Canninga-van Dijk MR, Kluijn PM, et al. Peripheral T-cell lymphomas unspecified presenting in the skin: Analysis of prognostic factors in a group of 82 patients. *Blood* 2003;102:2213-9.
8. Kumar S, Pittaluga S, Raffeld M, Guerrero M, Seibel NL, Jaffe ES. Primary cutaneous CD30-positive anaplastic large cell lymphoma in childhood: Report of 4 cases and review of the literature. *Pediatr Dev Pathol* 2005;8:52-60.
9. Ju E, Adigun C, Dunphy C, Gold S, Morrell DS. Anaplastic large cell lymphoma: An unusual presentation in a 7-year-old girl. *Pediatr Dermatol* 2012;29:498-503.
10. Tomaszewski MM, Moad JC, Lupton GP. Primary cutaneous Ki-1(CD30) positive anaplastic large cell lymphoma in childhood. *J Am Acad Dermatol* 1999;40:857-61.
11. Daar G, Küpeli S, Yalçın B, Kesik V, Orhan D, Buyukpamukçu M. Primary cutaneous anaplastic large cell lymphoma. *Pediatr Hematol and Oncol* 2010; 27:558-63.