

Fifteen-year treatment of metastatic thyroid medullary carcinoma: a case report

Ozen Oz Gul¹, Soner Cander², Pinar Sisman¹, Erdinc Erturk¹, Canan Ersoy¹

¹Department of Endocrinology and Metabolism, Uludag University Medical School, Bursa, Turkey

²Department of Endocrinology and Metabolism, Bursa Yuksek Itisas Training and Research Hospital, Bursa, Turkey

ABSTRACT

Although very rare, medullary thyroid carcinoma (MTC) is the most aggressive in differentiated thyroid malignancies. We report a 48-year-old male patient with the diagnosis of MTC, who was monitored for fifteen years and showed no serious adverse events due to long-term chemotherapy. Total thyroidectomy, neck dissection, retrosternal nodule excision and pericardiectomy were performed, and radiotherapy was applied to the neck area. Due to progressive metastatic disease cyclophosphamide, dacarbazine, and vincristine were administered. He tolerated chemotherapy well, and no severe systemic side effects were detected. He died due to multi-organ failure after fifteen years of diagnosis. The only curative treatment is surgery in MTC, however; radiotherapy, chemotherapy, and embolization may be used for patients for whom surgery cannot be performed. Although success rates of systemic chemotherapy are low, it is a treatment option in the progressive metastatic disease.

Eur Res J 2015;1(3):160-164

Keywords: Medullary thyroid carcinoma; metastatic; chemotherapy; thyroid cancer

Introduction

Medullary thyroid carcinoma (MTC) accounts for 5 to 10% of all thyroid malignancies and shows more aggressive progression than papillary and follicular carcinomas. Average age is approximately 50 years and it is reported that the disease is slightly more common in women. Although the most common initial complaint is painless swelling on

the neck, dysphagia, dysphonia and dyspnea may also be seen. It is reported that 75% of MTC cases are sporadic and 25% are familial (multiple endocrine neoplasia type 2A or 2B or isolated familial medullary thyroid cancer).

While Ret proto-oncogene mutation is detected in more than 95% of familial medullar cancers, Ret

Address for correspondence:

Ozen Oz Gul, MD, Department of Endocrinology and Metabolism, Uludag University Medical School, Bursa, Turkey

Email: drozenoz@gmail.com

Received: 26.07.2015; Accepted: 18.09.2015; Published Online: 04.11.2015

somatic mutation is detected in 40 to 70% of cases in sporadic medullary thyroid carcinoma [1-3]. Calcitonin, calcitonin gene-related peptide (CGRP), carcinoembryonic antigen (CEA) and serotonin are released from tumor tissue. Calcitonin is the most specific circulating and immunohistochemical marker for MTC, widely employed for diagnostic purposes [2, 3]. Calcitonin is increased in all the cases of clinically palpable MTC; however, in smaller tumors and C-cells hyperplasia. Patients with MTC should be followed postoperatively with periodic measurement of serum markers such as calcitonin and CEA that indicate residual disease. If a patient has a persistently elevated serum calcitonin concentration after total thyroidectomy and regional node dissection, neck ultrasound, CT, MRI and/or PET should be done. Over all survival rates in MTC can be favorable, with a mean survival of 75 - 85% at 10 years [4]. MTC is most aggressive in patients with MEN 2 B, less aggressive in sporadic type, and least aggressive in MEN 2A and familial MTC. This disease usually follows an indolent course even at the stage of distant spread. Some patients with distant metastases may not survive years without systemic treatment. Although the primary treatment is surgery, other treatment options such as embolization, radiotherapy and chemotherapy are available for patients who have local relapse, distant metastasis, or those who cannot be operated. Systemic chemotherapy may be used in patients who have diffuse metastasis, progressive disease and those for whom there is no curative surgical option. Common chemotherapy protocols include single administration of doxorubicin, single administration of cisplatin, dacarbazine-5-fluorouracil in combination, doxorubicin-cisplatin combination, cyclophosphamide-vincristine-dacarbazine, and a combination of doxorubicin-5-fluorouracil-etoposide-cyclophosphamide. Toxicity rates of these treatments are low and response rates do not exceed 20% [1, 2].

Case Presentation

A 48-year-old male patient presented to our clinic due to swelling on the neck, which first appeared in 1994. The patient had diarrhea and systemic examination revealed multiple nodules in the thyroid

gland. A fine needle aspiration (FNA) biopsy of the thyroid was malign; the patient was therefore referred to surgery. As the frozen section result indicated MTC, total thyroidectomy, neck dissection, retrosternal nodule excision were performed the patient. Microscopically, these tumors consist of sheets of cells separated by a pink-staining substance that stains with Congo red. Cervical exploration and sternotomy were performed, but a residual tumor was detected 3 months after the operation. There was no abnormal elevation of serum calcitonin level; 32 sessions, including cyclophosphamide, dacarbazine, and vincristine, were administered between 1995 and 1998. Local relapse was detected in 1998 and radiotherapy was applied to the neck area. No recurrence or relapse was observed in the patient Between 1998 and 2002. During this period, we didn't apply any treatment to the patient. Due to increased serum calcitonin levels in 2002, 6 more courses of chemotherapy were administered to the patient; pericardiectomy was performed due to pericardial MTC invasion in 2004. Cervical lymph node dissection in 2005 and cervical dissection in 2006 were performed due to local relapse. In 2006, multiple and different size of paratracheal, bilateral hilar, retrosternal, infraclavicular, right axillary lymph node metastases were detected and the patient was re-evaluated by chest surgery. The operation was found inappropriate and the patient was taken into the chemotherapy program again, but this was subsequently discontinued due to failure in general status and cachexia (Figure 1). After improvement in patient's condition we decided to continue with the chemotherapy and a total of 85 courses of same chemotherapy were administered until 2009. Thus, the 32 cycle of cyclophosphamide, dacarbazine, and vincristine, were administered between 1995 and 1998. In 2002, 6 cycle of chemotherapy were applied. Forty-seven cycle of chemotherapy were administered between 2006 and 2009. The patient tolerated chemotherapy well during this period and no severe systemic side effects were detected. Chemotherapy was terminated due to side effects such as medication resisted nausea-vomiting in 2009. The patient died due to multi-organ failure 8 months after discontinuation of the treatment.

Discussion

Generally, the initial complaint prompting hospital visit is the existence of a thyroid nodule or cervical lymphadenopathy. However, dysphonia, dysphagia and dyspnea which are developed due to local invasion may be the reason for the first application; and far metastases are detected in 10 to 15 % of patients at the moment of diagnosis [3]. Cervical lymph node involvement is common, and it is reported that involvement of central and ipsilateral lymph nodes are more common compared to other lymph sites. It is also reported that lymph node involvement at the moment of diagnosis is approximately 50% in MTC. Contralateral and mediastinal lymph node involvement reach up to

50 to 60% in cases of local invasive disease [2, 5]. MTC distant metastases are frequently observed in mediastinum, lung, liver, abdominal lymph nodes and bone. Cervical and mediastinal lymph node metastasis were detected in our patient at the time diagnosis.

Primary treatment of MTC is surgical. The purpose in the initial surgery should be to remove all tumor tissues and lymph nodes due to increased risk of complication in subsequent surgeries. High calcitonin and CEA levels postoperatively may indicate metastasis and should be evaluated. If metastases are large and located in areas that are easy to remove, they should be removed surgically

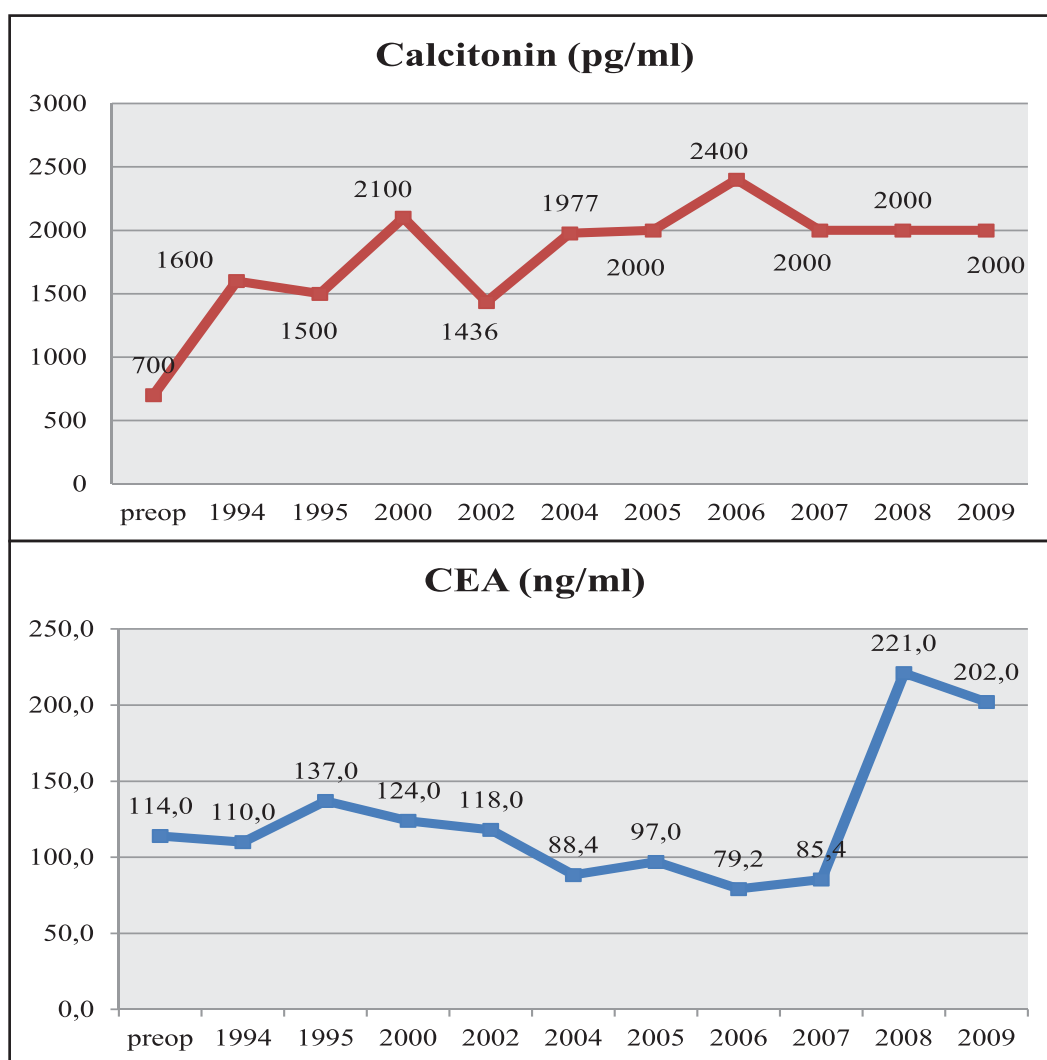


Figure 1. Calcitonin and CEA levels by year

[5, 6]. Other treatment options, such as radiation treatment, chemotherapy and embolization, are applied for patients for whom surgery is not an option [7, 8].

MTC generally progresses slowly and it is considered that the course of the disease is even slower with distant metastasis [8]. Typical survival rates are not known in metastatic MTC, due to insufficient number of studies and patients with MTC, and the non-homogenous distribution of the patients who were involved in those studies. Prognosis and treatment effectiveness are largely related to the tumour stage [9]. Early diagnosis is essential in patients with MTC, in order to obtain the best cure rate. Chemotherapy is recommended for a small proportion of the patients who have rapid, progressive metastatic disease and digress from natural progress of MTC [8]. Success rates of cytotoxic chemotherapy are quite low in metastatic MTC and rates varying between 2 and 25% are reported [8]. Doxorubicin has been the most frequently reported agent with a response rate probably not higher than 15-20%, all responses being partial and transient and with high toxicities [8]. Combination of doxorubicin with other drugs such as cisplatin [10], or streptozocin [11] did not increase the response rate. Many regimens have been tried in systemic chemotherapy, including a combination of cyclophosphamide, vincristine and dacarbazine; Wu *et al.* [12] reported on seven patients with progressive MTC who were treated by this combination. Calcitonin and CEA were measured regularly before the treatment and until detection of progression of the disease. That the study reported partial response in 2 patients who were followed-up for 14 and 29 months; partial biochemical response in 1 patient who was followed for 9 months, stable disease in 1 patient who was followed for 14 months and progressive disease in 3 patients throughout the study period. It was emphasized that chemotherapy was well tolerated in general, but efficacy was intermediate [12]. The amount of number of chemotherapy is not known in metastatic MTC, due to insufficient number of studies and patients with MTC. The alternating therapies using 5-fluorouracile-streptozosine and 5-fluorouracile-dacarbazine have been used. Select

tyrosine kinases inhibitors have been of interest for the treatments of advanced MTC, given the oncogenic role of mutations in the tyrosine kinase RET, as well as the contributory roles of tyrosine kinases in growth factor receptors such as VEGFR [13]. These drugs partially inhibit multiple kinases and often affect multiple signaling pathways. So availability of effective tyrosine kinases inhibitors (TKIs; vandetanib, cabozantinib, etc) is changing the standard approach in MTC, further limiting the role of cytotoxic agents [14]. Thus, there is a trend toward using traditional cytotoxic agents as a salvage therapy in MTC or reserved for patients who are unable to participate in clinical trials or have failed or cannot tolerate kinase inhibitors. TKIs as first line therapy but these drugs are only available after systemic cytotoxic treatment in Turkey with special permission. Because of our clinical experience is much more in the combination of cyclophosphamide, vincristine and dacarbazine, we treated our patient with this combination therapy.

Our case of metastatic disease showed stable progression and we did not observe any severe toxicity due to medication.

In another study, no response was seen with a single chemotherapeutic agent and alternating therapies using 5-fluorouracile-streptozosine and 5-fluorouracile-dacarbazine were administered to 20 metastatic patients every 3 weeks [15]. On average, 5-fluorouracile-streptozosine was applied 4 times and 5-fluorouracile-dacarbazine was applied 5 times. Partial response was observed in 3 patients, stable disease in 11 patients and progressive disease in 6 patients. Since severe medication side effects were not observed, emphasis was placed on preference for regimens including medications used in this treatment. We also applied combination therapy including dacarbazine with our patient. The disease showed stable progression with this treatment over a period of 15 years.

Toxicity and side effects are important factors which limit the long-term use of chemotherapeutic medications [14-16]. Cyclophosphamide is an alkylating agent, the most important side effect of which is cardiotoxicity (such as congestive heart failure, cardiac necrosis, and pericardial tamponade). Cardiotoxicity is especially observed in high dose

or long term treatments and the risk for cardiotoxicity increases when used with other alkylating agents. Additional side effects include nausea, vomiting, alopecia, hemorrhagic cystitis, bone marrow suppression, hepatotoxicity, flushing, inappropriate ADH syndrome, hyponatremia, and secondary malignancy. Vincristine is a vinca alkaloid, the most important side effect of which limits its use is peripheral neuropathy. Although this side effect is more common when it is used in patients over 40 years and in repetitive doses, it was also reported after a single dose. Dacarbazine is also an alkylating agent, of which the most important side effect is myelosuppression. We used combination treatment including cyclophosphamide (750 mg/m²), vincristine (1.4 mg/m²) and dacarbazine (600 mg/m²) every 3 weeks. Intermittently, 85 courses were administered to our patient and no severe side effects were observed except slight nausea, vomiting and mild myelosuppression. Cardiology consultation was requested for cardiotoxicity and physical examination, ECG and ECHO examination results of the patient were reported to be normal. The patient also evaluated for peripheral neuropathy and neurological examination and ENMG were found to be normal.

Metastatic thyroid medullar carcinoma is a type of malignancy for which current treatments are unsuccessful; therefore, new treatment options are being developed. The use of systemic chemotherapies is limited due to toxicities, side effects and limited success rates. However, chemotherapy may prolong survival for appropriate patients whose progressive disease cannot be controlled by surgical treatment.

Informed Consent

Written informed consent was obtained from the patient for the publication of this case report.

Competing interests

The authors declare that they have no competing interests with respect to the authorship and/or publication of this article.

References

- [1] de Groot JW, Links TP, Plukker JT, Lips CJ, Hofstra RM. RET as a diagnostic and therapeutic target in sporadic and hereditary endocrine tumors. *Endocr Rev.* 2006 Aug;27(5):535-60.
- [2] Brandi ML, Gagel RF, Angeli A, Bilezikian JP, Beck-Peccoz P, Bordi C, et al. Guidelines for diagnosis and therapy of MEN type 1 and type 2. *J Clin Endocrinol Metab.* 2001 Dec;86(12):5658-71.
- [3] Kouvaraki MA, Shapiro SE, Perrier ND, Cote GJ, Gagel RF, Hoff AO, et al. RET proto-oncogene: a review and update of genotype-phenotype correlations in hereditary medullary thyroid cancer and associated endocrine tumors. *Thyroid.* 2005 Jun;15:531-44.
- [4] Moley J. Medullary thyroid carcinoma: management of lymph node metastases. *J Natl Compr Canc Netw.* 2010 May;8(5):549-56
- [5] Moley JF, DeBenedetti MK. Patterns of nodal metastases in palpable medullary thyroid carcinoma: recommendations for extent of node dissection. *Ann Surg.* 1999 Jun;229(6):880-7; discussion 887-8.
- [6] Cohen MS, Moley JF. Surgical treatment of medullary thyroid carcinoma. *J Intern Med.* 2003 Jun;253(6):616-26.
- [7] Meijer JA, Bakker LE, Valk GD, de Herder WW, de Wilt JH, Netea-Maier RT, et al. Radioactive iodine in the treatment of medullary thyroid carcinoma: a controlled multicenter study. *Eur J Endocrinol.* 2013 Apr 15;168(5):779-86.
- [8] Orlandi F, Caraci P, Mussa A, Saggiorato E, Pancani G, Angeli A. Treatment of medullary thyroid carcinoma: an update. *Endocr Relat Cancer.* 2001 Jun;8(2):135-47.
- [9] Saad MF, Ordonez NG, Rashid RK, Guido JJ, Hill CS Jr, Hickey RC, et al. Medullary carcinoma of the thyroid. A study of the clinical features and prognostic factors in 161 patients. *Medicine (Baltimore).* 1984 Nov;63(6):319-42.
- [10] Shimaoka K, Schoenfeld DA, DeWys WD, Creech RH, DeConti R. A randomized trial of doxorubicin versus doxorubicin plus cisplatin in patients with advanced thyroid carcinoma. *Cancer.* 1985 Nov 1;56(9):2155-60.
- [11] Kelson DP, Cheng E, Kemeny N, Magill GB, Yagoda A. Streptozotocin and adriamycin in the treatment of APUD tumors (carcinoid, islet cell and medullary carcinoma of the thyroid). *Proc Am Assoc Cancer Res.* 1982;13:111.
- [12] Wu LT, Averbuch SD, Ball DW, de Bustros A, Baylin SB, McGuire WP 3rd. Treatment of advanced medullary thyroid carcinoma with a combination of cyclophosphamide, vincristine, and dacarbazine. *Cancer.* 1994 Jan 15;73(2):432-6.
- [13] Nikiforova MN, Nikiforov YE. Molecular genetics of thyroid cancer: implications for diagnosis, treatment and prognosis. *Expert Rev Mol Diagn.* 2008 Jan;8(1):83-95.
- [14] Zhang J, Yang PL, Gray NS. Targeting cancer with small molecule kinase inhibitors. *Nat Rev Cancer.* 2009 Jan;9(1):28-39.
- [15] Schlumberger M, Abdelmoumene N, Delisle MJ, Couette JE, Group d'Etude des Tumeurs a' Calcitonine (GETC). Treatment of advanced medullary thyroid cancer with an alternating combination of 5 FU-streptozocin and 5FU-dacarbazine. *Br J Cancer.* 1995 Feb;71(2):363-5.
- [16] Deutschbein T, Matuszczyk A, Moeller LC, Unger N, Yuce A, Lahner H, et al. Treatment of advanced medullary thyroid carcinoma with a combination of cyclophosphamide, vincristine, and dacarbazine: a single-center experience. *Exp Clin Endocrinol Diabetes.* 2011 Oct;119(9):540-3.