

**Case Report / Olgu Sunusu**

**Giant lipoma in an unusual location: a case report**  
**Sıradışı Yerleşimli Dev Lipoma: Olgu Sunumu**

Mehmet Sabri Balık<sup>1</sup>, Adem Erkut<sup>1</sup>, Yılmaz Güvercin<sup>1</sup>, Recep Bedir<sup>2</sup>, Başar Erdivanlı<sup>3</sup>

<sup>1</sup>Department of Orthopaedic and Traumatology, Medical Faculty, Recep Tayyip Erdoğan University, Rize, Turkey..

<sup>2</sup>Department of Pathology, Medical Faculty, Recep Tayyip Erdoğan University, Rize, Turkey..

<sup>3</sup>Department of Anesthesiology and Reanimation, Medical Faculty, Recep Tayyip Erdoğan University, Rize, Turkey.

**Corresponding Author:**

Dr. Mehmet Sabri Balık

**Address :** Department of Orthopaedic and Traumatology, Medical Faculty, Recep Tayyip Erdoğan University, Rize, Turkey..

**E-mail:**

sabribalik@yahoo.com

**Phone:** 0 505 823 19 43

**Başvuru Tarihi/Received :**

02-02-2014

**Kabul Tarihi/Accepted:**

13-06-2014

**ÖZET**

Biz deltoid altında yerleşimi nadir olan lipoma olgusunu sunduk. Lipomanın bu bölgede yerleşimi nadir olduğu için eksizyon öncesi diğer yumuşak doku kitlelerinden ayırım için biopsi yapılmalı. Kitlenin aksiler sinir ile yakın ilişkisi nedeni ile deltoid kasın akromiona yapışma yerinden ayrılması güvenli ve geniş bir yaklaşım sağlamaktadır. İlaveten kitle etkisiyle elonge olup tonusu azalan deltoid liflerinin tonusunu tekrar sağlamak için güvenli bir yaklaşımdır.

**Anahtar Kelime:** Dev lipoma, omuz, parostela lipoma

**ABSTRACT**

Lipomas are common in subcutaneous tissues. Main complication of lipomas are pain and cosmetic defects. We present a case of lipoma located below the deltoid muscle. This is a very unusual location, hence a biopsy was needed for the differential diagnosis. Serious complications may occur due to proximity to the axillary nerve. Due to mass effect of the lipoma, deltoid muscle fibers were elongated and lost their tonus. To remove the lipoma safely, we separated the deltoid muscle from the acromial origin, and shortened the deltoid muscle fibers to restore their tonus.

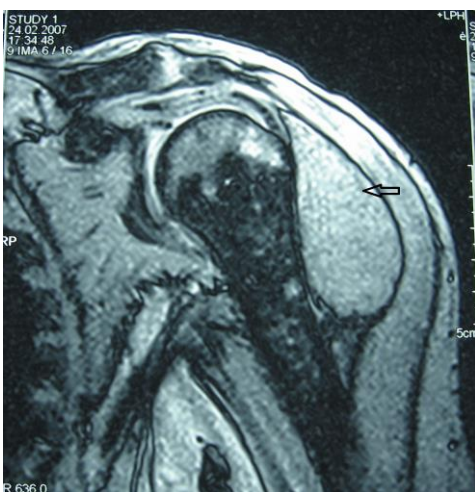**Key words:** Giant lipoma, shoulder, parosteal lipoma

## INTRODUCTION

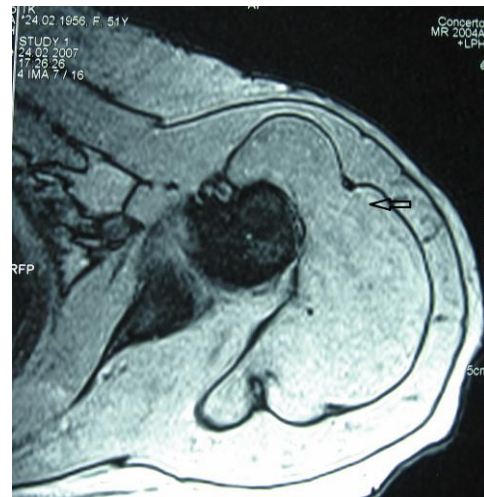Lipomas are common, mesenchymal tumours, originating from mature adipose tissue. They are classified as superficial and deep according to their localizations. Subcutaneous lipomas are common, and located in the subcutaneous tissue. Deep lipomas are rare, and may occur in deeper tissues. Lipomas may be defined by their locations such as intramuscular, or paraosteal. Lipomas greater than 5 cm in diameter are classified as giant lipomas (1, 2). Giant lipomas may become symptomatic, if they exert mass effect onto the neighbour tissues. Treatment in this case is surgical excision (3, 4). Surgical technique should be chosen according to lipoma's location.

## CASE

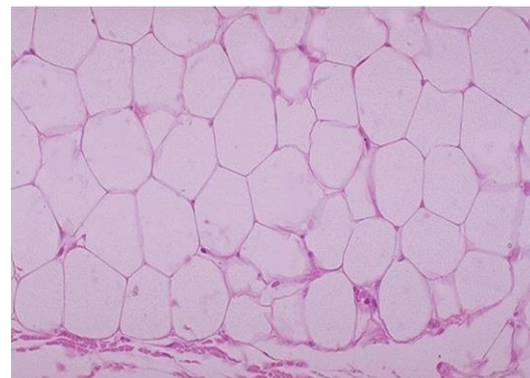
51 years-old female presented to our outpatient clinic due to a mass on the posterior side of the right upper shoulder. The mass was present since 4 years, and grew steadily. Physical examination showed a soft, painless, mobile mass (10x15x7 cm), extending from anterior side of the right shoulder to the posterior side, along the lateral side. Laboratory values and plain shoulder x-ray were normal. Magnetic resonance imaging (MRI) of the shoulder showed a mass below the deltoid muscle, pre-diagnosed as a lipoma (**Figure 1**).



The mass was very proximal to the axillary nerve. To rule out malignancy, we performed an incisional biopsy with local anesthesia. Pathological examination revealed a lipoma, and surgical excision was planned. During surgery, the deltoid muscle was separated by a blunt dissection. After the mass was excised (**Figure 2**),



the elongated deltoid muscle fibers were shortened and repaired. Histopathologic examination confirmed the diagnosis of lipoma (**Figure 3**). Post-operative follow-ups were uneventful.



## DISCUSSION

Lipomas are soft, elastic, painless masses, which grow very slowly. Compression of proximal soft tissues or neurovascular tissues, or local expansion may cause local pain (5,6).

Lipomas may extend to subacromial area, and cause glenohumeral subluxation (6). In our case, the mass was in the subacromial area but there was no sign of joint instability. Shoulder movement was normal. There was no complaint of pain, or sensory defects. Our patient's sole complaint was the cosmetic defect.

Lipomas are hard to differentiate from other soft tissue masses with clinical features only. Diagnosis should be supported by radiological or histological findings. Differentiating liposarcoma from a lipoma is very important and requires histopathological examination. Lipoblast on histopathological examination is the main clue of liposarcoma. However, low-grade, well-differentiated liposarcomas (sometimes called atypical lipomatous tumour) are difficult to differentiate from lipomas. Well-differentiated liposarcomas show variable numbers of vacuolated lipoblasts with atypical nuclei, low cellularity, and rare mitotic figures. Such liposarcomas are a subgroup, which are local recurrent, but do not metastasize, differentiate well, and sometimes transform into de-differentiated phenotype. High-grade liposarcomas show increased cellularity and mitotic activity (typical or atypical), multi-vacuolated big lipoblasts, distinct pleomorfizm and necrosis (7).

It is recommended that malignancy should be considered in soft tissue masses greater than 5 cm in diameter (2, 8). Computed tomography is useful to identify tumour location and infiltration of the neighbour tissues. Also, density of the mass may help to differentiate a malign tumour from a benign one. However, degeneration, bleeding or necrosis may confuse the clinician (9). Magnetic resonance imaging is a popular imaging modality to identify tumour location and possible infiltration of the neighbour tissues. Lipomas show hyperintensity in magnetic resonance imaging studies (10).

Extracting subdeltoid tumours is difficult due to axillary nerve injury risk. If the

subdeltoid mass is large and close to the axillary nerve, subdeltoid approach provides a wide view and field to the surgeon. This technique may prevent axillary nerve injury. Also, it allows incision and repair of the elongated deltoid muscle fibers (11).

In conclusion, lipoma should be considered in the differential diagnosis of subdeltoid soft tissue masses. Separating the fibers of the deltoid muscle from the acromion may prevent axillary nerve injury.

### Conflict of interests

The authors have no conflict of interest to declare.

### REFERENCES

1. Liu DR, Li C, Chen L. Management of giant intermuscular lipoma of hips: A case report and review of literature. *Mol Clin Oncol*. 2013;1(2):369-372.
2. Weiss Sw, Goldblum JR. Bening Lipomatous tumors. In: Enzinger and Weiss' s soft tissue tumors. 4th edition. St.Louis: Mosby, 2001, 571-639.
3. Silistrelı OK, Durmuş EU, Ulusal BG, Oztan Y, Görgü M. What should be the treatment modality in giant cutaneous lipomas? Review of the literature and report of 4 cases. *Br J Plast Surg*. 2005;58(3):394-398.
4. Elbardouni A, Kharmaz M, Salah Berrada M, Mahfoud M, Elyacoubi M. Well-circumscribed deep-seated lipomas of the upper extremity. A report of 13 cases. *Orthop Traumatol Surg Res*. 2011;97(2):152-158.
5. Rohrbough JT, Jobe CM. Subdeltoid lipoma presenting as subluxation of the glenohumeral joint. *J Shoulder Elbow Surg*. 1995;4:225-227.
6. Rosai J, Akerman M, Dal Cin P, DeWever I, Fletcher CD, Mandahl N, et al. Combined morphologic and karyotypic study of 59 atypical lipomatous tumors. Evaluation of their relationship and differential diagnosis with other adipose tissue tumors (a report of the CHAMP StudyGroup). *Am J SurgPathol*. 1996;20:1182-1189.
7. Johnson CJ, Pynsent PB, Grimer RJ. Clinical features of soft tissue sarcomas. *Ann Roy Coll Surg Eng*. 2001;83:203-205.
8. Pettersson H, Hamlin DJ, Mancuso A, Scott KN. Magnetic resonance imaging of the musculoskeletal system. *Acta Radiol Diagn (Stockh)*. 1985;26:225-234.
9. Drevelegas A, Pilavaki M, Chourmouzi D. Lipomatous tumors of soft tissue: MR appearance with histological correlation. *Eur J Radiol*. 2004;50(3):257-267.
10. Tamai K, Osada D, Mori K, Takizawa K, Hamada J, Saotome K. Subdeltoid approach for removal of large soft-tissue lesions beneath the deltoid muscle: report of two cases. *J Shoulder Elbow Surg*. 2003;12:520-523