



Case Report

J. Exp. Clin. Med., 2020; 37(1): 17-19  
doi: 10.5835/jecm.omu.37.01.004



## A rare cause of fever in the emergency department

Pınar Henden<sup>a</sup>, Özgür Levent Yamanlar<sup>b</sup>, Latif Duran<sup>b\*</sup>, Celal Katı<sup>b</sup>, Hızır Ufuk Akdemir<sup>b</sup>

<sup>a</sup> Emergency Service, Çorum Education and Research Hospital, Çorum, Turkey

<sup>b</sup> Department of Emergency Medicine, Faculty of Medicine, Ondokuz Mayıs University, Samsun, Turkey

### ARTICLE INFO

### ABSTRACT

#### Article History

Received 26 / 12 / 2019  
Accepted 21 / 01 / 2020  
Online Published 23 / 03 / 2020

#### \* Correspondence to:

Latif Duran  
Department of Emergency Medicine,  
Faculty of Medicine,  
Ondokuz Mayıs University  
Samsun, Turkey  
e-mail: mdllduran@gmail.com

#### Keywords:

Falciparum  
High fever  
Malaria  
Travelling history

Fever is one of the most frequent reasons for application to emergency service. Inflammatory diseases may vary from short-termed and self-limiting to serious conditions that may cause hospitalization at intensive care unit or death. Malaria is a disease with high mortality. We have aimed to submit a malaria case who has applied to emergency due to high fever and conscious change. A 52 years old male patient was brought to emergency by his relatives due to fever, headache, cold-shivering, conscious change at the periods with high fever. It was learnt that the patient had returned to Turkey 10 days ago from Africa where he had lived for the last six months. Systemic examination was normal and no organomegaly or icterus was observed in the patient. In thick smearing preparation, malaria forms were observed and in the thin smearing preparation, more than one ring-form gametocytes were observed and thus Plasmodium falciparum diagnosis was considered. Atovaquone/Proguanil 1x1 gr (3 days) treatment was started for the patient and he was hospitalized in the infections service. For the patients applied to emergency with high fever, travelling history should be investigated, malaria should be considered and early treatment should be started.

© 2020 OMU

### 1. Introduction

Fever is one of the most frequent reasons for application to emergency service. Inflammatory diseases may vary from short-termed and self-limiting to serious conditions that may cause hospitalization at intensive care unit or death (Knott et al., 2004). Malaria is a disease with high mortality that should be considered among the infection emergencies in the patients applied with fever and travelled to abroad (Malaria report, 2015). Malaria is a parasitic disease causing an illness in approximately 250-500 millions of people annually in tropical countries and causing the death of approximately more than 1 million people per year (Fairhurst et al.,

2010). Malaria parasites causing infections in humans are Plasmodium vivax, ovale, falciparum and malaria. Among these four species, the most severe clinical pictures and deaths are seen in the malaria caused by Plasmodium falciparum (Fairhurst et al., 2010). In our country, malaria cases caused by Plasmodium vivax are frequently seen, Plasmodium falciparum malaria is more common the people having a traveling history to abroad (Çelikbaş et al., 2006). We have aimed to submit a malaria case who has applied to emergency due to high fever and altered consciousness and traveled overseas.

## 2. Case

A 52 years old male patient had brought to emergency service by his relatives due to fever, headache, cold-shivering, altered conscious at the periods with high fever. The patient had no previous illnesses and it was specified that his complaints had started five days ago and increased gradually. It was learnt that the patient had returned to Turkey 10 days ago from Africa where he had lived for the last six months.

The general status of the patient was moderate, conscious but prone to sleep, partially cooperated and oriented. Blood pressure was 150/90 mm Hg, heart rate (HR) was 110/min, temperature was 39° C and respiration rate was 26/min. Systemic examination was normal and no organomegaly or icterus was observed in the patient. Neurological examination of the patient was evaluated as normal. In the laboratory examinations, hemoglobin was observed as 12.2 g/dL; hematocrit 35.6; thrombocyte 23.000 /mm<sup>3</sup>; C-reactive protein (CRP) as 195 mg/L; total bilirubin 2.23 mg/dL; direct bilirubin 1.48 mg/dL; aspartate amino-transferase (AST) 69 IU/L; alanine amino-transferase (ALT) 34.6 IU/L; lactate dehydrogenase (LDH) 607 IU/L; glucose 146 mg/dL; blood urea nitrogen (BUN) 34.5 mg/dL; creatinine 0.64 mg/dL; total protein 4.8 mg/dL; albumin 2.80 mg/dL. Urinary examination of the patient was normal.

No pathology was observed in computerized brain tomography (CBT) and diffusion magnetic resonance

(MRI) imaging technique in the patient. Due to the failure to explain the clinic of the laboratory results and radiologic images of the patient and the history of travel to a risky area; the pre-diagnosis of malaria was considered for the patient. Blood samples were prepared from the patient via thick drop and thin smearing technique. These samples were stained in the parasitology laboratory according to the Giemsa staining procedure and then they were examined under a light microscope. In thick smearing preparation, malaria forms were observed and in the thin smearing preparation, more than one ring-form gametocytes were observed and thus *Plasmodium falciparum* diagnosis was considered (Fig. 1).

Atovaquone/Proguanil 1x1 gr (3 days) treatment was started for the patient and he was hospitalized in the infections service. Fever of the patient was regressed on the third hospitalization day, his conscious was returned to normal and he was mobilized. At the end of the third day, doxycycline treatment was started. The patient was discharged on the 10<sup>th</sup> day with recommendations after his treatment was completed.

## 3. Discussion

Malaria is prevalently seen in tropical and subtropical areas and it causes illness in approximately 250-500 millions of people in a year and also causes the death of more than 1 million people per year (Fairhurst et al., 2010). Today travelling to various regions in the world due to tourism and employment is frequent and malaria is one of the inflammatory diseases especially seen after travelling to sub-Saharan Africa and tropical areas (Bozkurt et al., 2013). When the travel histories of our patient are inspected, it was learnt that he had spent his last six months in Gabon, Africa. The patient had specified that while he was working in Gabon, some of his friends had inflammatory diseases with similar complaints. According to the data of World Malaria Report 2015, Gabon is an endemic region for falciparum malaria (Ülçay et al., 2014). The malaria parasites causing infections in humans are *P. vivax*, *P. ovale*, *P. falciparum*, *P. malaria* and *P. falciparum* causes the most serious clinic (Celikbaş et al., 2006). Although *P. vivax* is most frequently seen in our country and in the world, *P. falciparum* can also be seen in the people who have travelled to the endemic regions (Celikbaş et al., 2006). Like other malaria types, *Falciparum* malaria starts with headache, asthenia, cold, shivering and sweating. In falciparum malaria, periodical fever is seen once every 72 hours and mostly it progresses with irregular intermittent fever (Parlak et al., 2013). In case early and correct treatment is not applied in this malaria type, mortality may occur besides various complications thus early diagnosis is of great importance. Thus malaria diagnosis should be considered for the patients who have applied to emergency with fever complaint, the

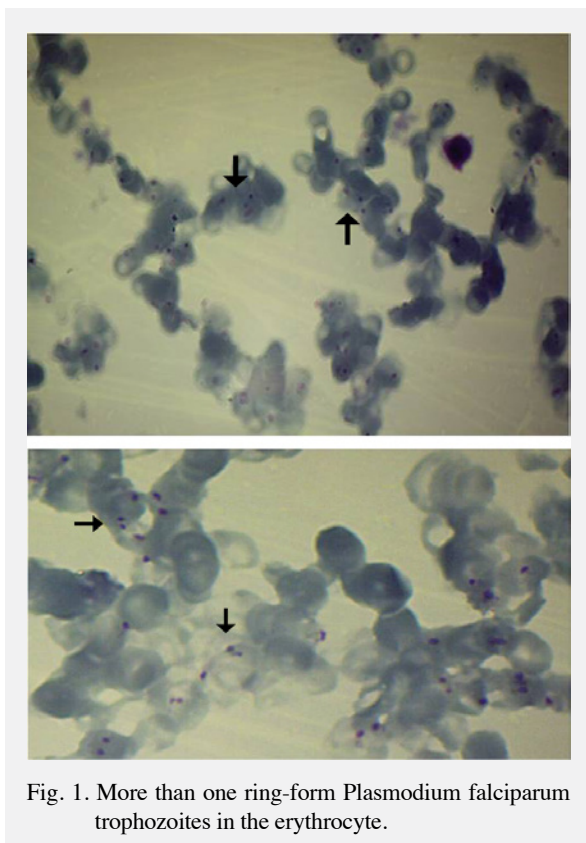


Fig. 1. More than one ring-form *Plasmodium falciparum* trophozoites in the erythrocyte.

travelling history of the patient should be investigated for early diagnosis and required examinations should be done. In our case, fever, headache and conscious change are present and fever is observed at irregular periods. The patient had applied to various doctors within the last five days due to fever but diagnosis could not be made because malaria is eluded.

In malaria, physical examination findings such as the symptoms are non-specific and most frequently splenomegaly and hepatomegaly are seen. In the laboratory findings, elevated anemia, thrombocytopenia, liver function tests disorders, bilirubin and lactic dehydrogenase enzyme may be seen (World malaria report, 2015). In our case, hepatosplenomegaly is not present and thrombocytopenia (23000/mm<sup>3</sup>), elevated bilirubin (total bilirubin 2.23 mg/dL, direct bilirubin 1.48 mg/dL), elevated LDH (607 IU/L) are specified.

Malaria diagnosis can be done via various methods and thin smearing and thick drop blood preparations are one of the diagnosis methods that are very simple and responding very quickly. In *P. falciparum*

malaria, only young trophozoite, more than one ring-form and banana-type gametocyte forms are seen in peripheral blood (Moody, 2002). In our case, diagnosis was made by observing more than one ring-form and gametocytes in one erythrocyte. Atovaquone/Proguanil 1x1gr treatment for three days and then doxycycline treatment for 7 days is given upon contacting to the infectious diseases branch of the Directorate of Health. During the treatment, fever of the patient has regressed on the 3<sup>rd</sup> day, his consciousness was restored and he was mobilized. After a total of 10-day treatment, the patient was discharged by recommending a polyclinic follow-up.

Malaria is an important disease that responds well to the treatment and that may progress mortally when no treatment is applied and early diagnosis and early treatment are very important. For the patients applied to emergency with high fever, travelling history should be investigated, malaria should be considered and early treatment should be started.

## REFERENCES

- Bozkurt, S., Kökoğlu, Ö., Okumuş, M., İnci, M., Güler, S., 2013. Malaria: A disease that should not be forgotten in emergency service; case report. *Tr. J. Emerg. Med.* 13, 182-185.
- Celikbas, A.K., Ergönül, O., Baykam, N., Eren, S., Güven, T., Dokuzoguz, B., 2006. Malaria in Turkey and 14 years of clinical experience. *Mikrobiyol. Bul.* 40, 237-243.
- Fairhurst, R.M., Wellems, T.E., 2010. *Plasmodium species (Malaria)*. In: Mandell GL, Bennett JE, Dolin R, editors. *Principles and practice of infectious diseases*. 7<sup>th</sup> ed. Philadelphia: Churchill Livingstone; 3437-3462.
- Knott, J.C., Tan, S.L., Street, A.C., Bailey, M., Cameron, P., 2004. Febrile adults presenting to the emergency department: Outcomes and markers of serious illness. *Emerg. Med. J.* 21, 170-174.
- Parlak, E., Ertürk, A., Çayır, Y., Parlak, M., 2013. Four Malaria-Import patterns: Sporadic region. *Turkiye Parazitol. Derg.* 37, 161-164.
- Moody, A., 2002. Rapid diagnostic tests for malaria parasites. *Clin. Microbiol. Rev.* 15, 66-78.
- Ulçay, A., Karaahmetoğlu, G., Turhan, V., Erdem, H., Acar, A., Oncul, O., Gorenek, L., 2014. The management of therapeutic failure in a falciparum malaria patient under oral arthemether lumefantrine therapy. *Turkiye Parazitol. Derg.* 38, 61-67.
- World Malaria Report 2015. <https://www.who.int/malaria/publications/world-malaria-report-2015/en/>. accessed: 05 October 2019)