

## ENDOVASKÜLER KOİL EMBOLİZASYONU İLE TEDAVİ EDİLEN İNTRASEREBRAL ANEVİZMALARDA MANYETİK REZONANS PERFÜZYON DİNAMİĞİNİN DEĞERLENDİRİLMESİ

### Evaluation of Magnetic Resonance Perfusion Dynamics in Patients with Intracerebral Aneurysms Treated with Endovascular Coil Embolization

Gökhan POLAT(0000-0002-9184-8730), Suat EREN (0000-0002-7379-6922), Akın LEVENT(0000-0003-0136-4570), Hayri OĞUL(0000-0001-5989-3729), Mecit KANTARCI (0000-0002-1043-6719)

#### ÖZET

**Giriş ve Amaç:** Aneurizmalar kese içi doluma bağlı oluşan kitle etkisiyle, rüptürüne bağlı oluşan kanama ve vasküler spazm gibi komplikasyonlarla beyin hemodinamiğini ve perfüzyonunu etkiler. Bu nedenle, tedavideki amaç aneurizmayı tam olarak dolaşım dışında bırakarak kanama ihtimalinin ortadan kaldırılması, kitle etkisinin yok edilmesi ve bunun yanı sıra ana arterdeki kan akımının korunmasıdır. Çalışmamızdaki amacımız, aneurizma tedavisinin beyin perfüzyonu üzerinde yaptığı değişimlerin belirlenmesidir.

**Gereç ve Yöntem:** 2014 - 2017 tarihleri arasında Atatürk Üniversite Radyoloji A.B.D.'da endovasküler aneurizma tedavisi yapılan 42 hasta incelemeye alındı. 8 hasta değerlendirme kriterlerine uymadığı için çalışmadan çıkarıldı. Çalışmada yaşları 21-69 arasında değişen 34 hastada işlem öncesi, işlem sonrası 3. gün ve işlem sonrası 1. ay beyin perfüzyon parametreleri (rCBV, rCBF, MTT ve TTP), posterior dolaşımla kıyaslanarak perfüzyon parametrelerinde ki değişimler istatistiksel olarak değerlendirildi.

**Bulgular:** Çalışma popülasyonumuzun ortalama yaşı 52 yaştır.(21-69) Hastalarımızda aneurizma boyutu  $\leq 10$ mm ölçülmüş olup küçük aneurizmalar sınıfında değerlendirildi. Operasyon öncesi, operasyon sonrası üçüncü gün ve operasyon sonrası birinci aya ait perfüzyon parametreleri karşılaştırıldığında rCBV, rCBF ve MTT değerleri bakımından operasyon öncesi ve sonrasında istatistiksel olarak anlamlı farklılık saptanmamıştır. İstatistiksel p değerleri: rCBV için  $p=0.652$ , rCBF için  $p=0.563$ , MTT için  $p=0.865$  bulunmuştur. TTP haritasından elde edilen değerlerde ise operasyon öncesine göre, operasyon sonrası üçüncü gün uzama ve operasyon sonrası birinci ayda ise azalma izlenmiş olup anlamlı farklılık tespit edilmiştir.(  $p=0.025$  )

**Sonuç:** Küçük aneurizmalar beyin perfüzyonunda rCBV ve rCBF'ye etki etmediğinden bu aneurizmaların tedavisinde perfüzyona bağlı hiperperfüzyon sendromu beklenmemektedir. TTP haritasının 3. gün uzaması ve 1. ay kısalması işlem sırasında ve sonrasında gelişen beyin ödemi, vazospazm gibi komplikasyonları açısından gösterge olabilir.

**Anahtar Kelimeler:** Serebral aneurizma; Perfüzyon; Manyetik rezonans

#### ABSTRACT

**Introduction and purpose:** Aneurysms affect the hemodynamics and perfusion of the brain, with complications such as intraparenchymal mass, ruptured bleeding, and vascular spasm. For this reason, the purpose of the treatment is to remove an aneurysm completely from the circulation, to eliminate the possibility of bleeding, to destroy the mass effect, and to protect the blood flow in the main artery. Our study aims to determine how aneurysm treatment affects brain perfusion.

**Materials and Methods:** Between 2014 and 2017, 42 patients who underwent endovascular aneurysm treatment at Atatürk University's Radiology Department were examined. Eight patients were excluded from the study because they did not meet the inclusion criteria. The data for 34 patients were evaluated in the study. Brain perfusion parameters were measured before the procedure, 3 days after the procedure, and 1 month after the procedure. Also, rCBV, rCBF, MTT, and TTP parameters were compared with posterior circulation, and the changes in perfusion parameters were evaluated statistically.

**Results:** The size of the aneurysm was measured as  $\leq 10$  mm in our patients. Thus these patients were evaluated as part of the small aneurysm class. When the perfusion parameters were compared, there was no significant difference between preoperative and postoperative values in terms of rCBV, rCBF, and MTT. The p values obtained were as follows:  $p = 0.652$  for rCBV,  $p = 0.563$  for rCBF, and  $p = 0.865$  for MTT. There was a significant difference in the values obtained from the TTP map ( $p = 0.025$ ). According to the measurements taken before the operation, prolongation was observed on the third day after the operation, which decreased in the first month after the operation.

**Conclusion:** Because small aneurysms do not affect rCBV and rCBF during brain perfusion, perfusion-related complications (hyperperfusion syndrome), which can be seen during the treatment of aneurysms, are not expected. The third-day prolongation and the shortening of the first month of the TTP period may be indicative of complications such as brain edema and vasospasm, which may develop during or after the procedure

**Keywords:** Magnetic resonance perfusion ;Intracerebral aneurysms ;Endovascular coil embolization

<sup>1</sup>Department of Radiology,  
Medical Faculty, Ataturk  
University, Erzurum, Turkey

Gökhan POLAT, Doç. Dr.  
Suat EREN, Prof. Dr.  
Akın LEVENT, Prof. Dr.  
Hayri OĞUL, Doç. Dr.  
Mecit KANTARCI, Prof. Dr.

#### İletişim:

Dr. Gökhan POLAT  
Department of Radiology  
Faculty of Medicine  
Ataturk University  
25040 Erzurum, Turkey  
Tel: +90 442 344 6920  
e-mail:  
dr.g.polat@gmail.com

Geliş tarihi/Received: 25.01.2019  
Kabul tarihi/Accepted:06.03.2019  
DOI: 10.16919/bozoktip.517959

Bozok Tıp Derg 2020;10(1):50-4  
Bozok Med J 2020;10(1):50-4

## INTRODUCTION

Aneurysm is the irreversible expansion of the normal diameter of a vessel as the word meaning [1]. With the effect of intravenous pressure and the regeneration due to turbulence, weak spots develop in the aneurysm wall. Thus, rupture may occur in the vessel wall [2]. Mass effect, rupture, and thromboembolic events are complications that directly affect brain vascular hemodynamics and perfusion. Therefore, it is important to make an early diagnosis and treatment [3]. The aim of the treatment is to eliminate the possibility of bleeding by leaving the aneurysm out of the circulation completely, to eliminate the mass effect and to preserve the blood flow in the main artery [4]. The flow in the main artery is important because it directly affects the brain perfusion of the patient. Therefore, treatment-related complications (ischemia, hyperperfusion, thromboembolism, etc.) that may occur after treatment are complications that should be considered [4]. In this study, we aimed to evaluate brain perfusion dynamics after aneurysm treatment by examining the brain perfusion parameters of patients undergoing endovascular treatment.

## MATERIALS AND METHODS

### Patient Selection

Forty-two patients with endovascular aneurysm treatment were included in the study. The patients underwent magnetic resonance(MR) perfusion one day prior to endovascular treatment. MR perfusion procedure was repeated at 3 days and 1 month after treatment. Two patients had aneurysm in the posterior circulation. Since the perfusion values of the aneurysm area were examined according to the perfusion values of the posterior circulation as reference point, these two patients were excluded from the study. In addition, patients with posterior cerebral artery with persistent fetal origin who were directly affected by anterior circulation were evaluated. Therefore, six patients with posterior cerebral circulation with persistent fetal origin were excluded from the study. The remaining 34 patients were included in the study.

### MR Perfusion Protocol

Views were performed using a 3-Tesla MRI device with a 20-channel phase array cranial coil (Skyra, Siemens

Medical Systems, Forcheim, Germany). All patients underwent routine brain MRI, diffusion MRI, MR angiography for the exclusion of additional pathologies. T2 \* weighted echo planar imaging sequence (TR: 800ms, TE: 54ms, matrix: 128x128, data flow time 60sec, FOV: 256 mm, section thickness: 5mm, gap spacing 0 mm) was used for Dynamic susceptibility contrast(DSC) perfusion MRI. As an intravenous contrast agent, 0.2mmol Gadolinium per kilogram of body weight was given. The contrast medium was given at a rate of 4ml / sec with an automatic injector. 20 ml of saline was then made. The image acquisition was started within 5 seconds after contrast medium administration and image was taken for 60 seconds.

### Evaluation of Images

The data obtained from the imaging was then sent to the workstation (syngo-via, Siemens medical systems) for evaluation. With the help of fully automated software, the data were analyzed and the relative cerebral blood volume(rCBV), cerebral blood flow(rCBF), mean transit time(MTT) and time to peak(TTP) maps were obtained relative to the arterial input factor. On these maps, quantitative values were obtained by using ROIs with an area of 0.65-0.80cm<sup>2</sup>. The values obtained from the perfusion site of the aneurysm artery and the neighboring region of the occipital lobe interhemispheric fissure, which is the perfusion site of the posterior circulation used as reference, were listed for analysis. The perfusion values obtained from the aneurysm localization were compared to the reference point occipital lobe perfusion values. Thus, the effect of conditions that may affect perfusion in the patient is reduced (changes in blood pressure, cardiac rhythm changes, etc.). Values were obtained by a single radiologist at the same anatomic level in all patients (centrum semiovale level where lateral ventricles ended).

### Statistical analysis

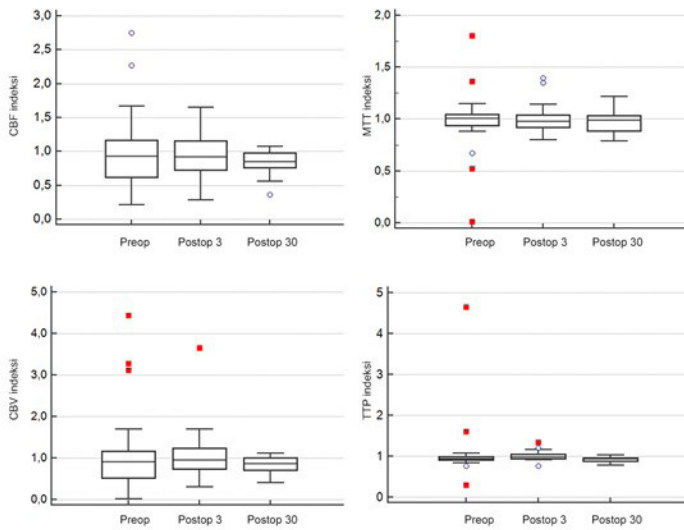
Continuous variables are expressed as mean  $\pm$  standard deviation. Comparison between nonparametric perfusion values obtained at different times of the same patient group was performed by using Friedman test.

All reported p-values were calculated as two-way and p-value less than 0.05 was considered statistically significant. All statistical analyzes were performed using statistical software (Medcalc ver. 12, Mariagerke, Belgium).

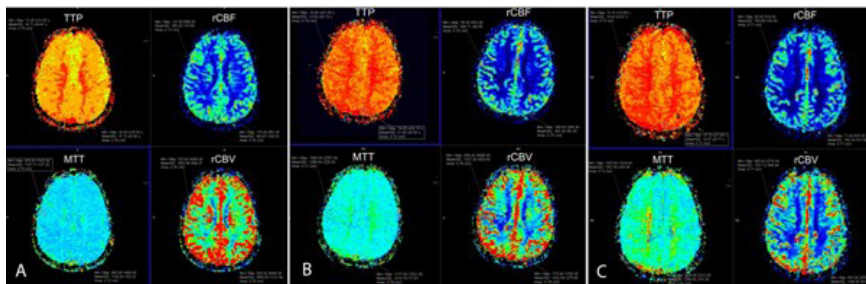
## RESULTS

The mean age of the patients was  $52.1 \pm 12.2$  years and the female male ratio was 1. When the data were evaluated, there was no statistically significant difference between rCBV, rCBF and MTT values before

and after the operation. Statistical p values of perfusion parameters: for rCBV;  $p = 0.652$  for rCBF;  $p = 0.563$  for MTT;  $p = 0.865$  (Fig. 1,2,3,4). In the values obtained from the TTP map, a significant difference was found between the preoperative values and the perfusion values on the third postoperative day ( $p = 0,025$ ) (Figure 1,2). There was no significant difference between the postoperative first month and the preoperative period in terms of time to perfusion peak.



**Figure 1:** Graph of perfusion parameters



**Figure 2:** A 67-year-old female patient had a 4x6mm wide necked aneurysm in the right MCA bifurcation. Coil treatment was applied to the patient. In the perfusion images of the patient; (A) before the procedure: rCBF lesion / rCBF reference = 0,760309; rCBV lesion / rCBV reference = 0.696764; MTT lesion / MTT reference = 0.980514; TTP lesion / TTP reference = 0.972884. (B) On the 3rd day after the procedure: rCBF lesion / rCBF reference = 1,082902; rCBV lesion / rCBV reference = 0,960203; MTT lesion / MTT reference = 0.984733; TTP lesion / TTP reference = 1,120279. (C) 1st month after the procedure: rCBF lesion / rCBF reference = 0.981132; rCBV Lesion / rCBV reference = 1.032554; MTT lesion / MTT reference = 0,874675; TTP lesion / TTP reference = 0.976346

## DISCUSSION

Aneurysms can provide a wide spectrum of clinical presentations ranging from headache to mass pressure effects. As the size of the aneurysm increases, the risk of rupture increases [3,4]. Therefore, endovascular or surgical treatment methods are used to prevent these complications of aneurysms. However, these treatment methods may cause changes in brain hemodynamics and perfusion. These include vasospasm and thromboembolism-induced ischemia, as well as complications such as hyperperfusion and brain edema [3]. The aim of the treatment is to isolate the aneurysm from the circulation, to eliminate the possibility of bleeding, to eliminate the mass effect and to protect the blood flow in the main artery [5,6].

Blood flow in the main artery can be affected directly by treatment procedures, operational errors or complications. After endovascular treatment, we evaluated brain perfusion parameters in our patients. No significant difference was found between the perfusion maps in the MTT, rCBV and rCBF maps of the brain perfusion maps in the controls, on the 3rd day and in the 1st month after the procedure. In our study patients, we think that aneurysms do not affect the hemodynamic parameters such as MTT, rCBV and rCBF, because they are smaller than 10 mm. Because, due to the effect of turbulence in the giant aneurysms and the compression of the main artery due to the mass effect of the aneurysm, there may be perfusion variability in the aneurysm perfusion site [4-8]. Therefore, the possibility of adverse events such as sudden changes in the brain perfusion (hyperperfusion, ischemia) in the treatment of small aneurysms decreases. Studies in the literature show that hemodynamic changes in the treatment of large aneurysms cause changes in all parameters of the perfusion, and therefore it is necessary to be careful for possible sudden changes in the perfusion of large aneurysm treatments [8,9]. In our study, we have seen that small aneurysms do not cause hyperperfusion syndrome because they do not affect rCBV and rCBF map. This suggests that surgical or endovascular methods may be a safe procedure for this complication.

Smaller aneurysms show changes in the TTP map.

These changes were observed as an extension of TTP at 3 days and shortening at 1 month. The extension of TTP on third day may indicate the effect of vasospasm or brain edema during and after endovascular procedure. M.Hohliedier et al. showed that more than half of the patients treated with endovascular aneurysm had vasospasm [10]. Vasospasm is usually seen in ruptured aneurysms but may also occur in non-ruptured aneurysms. [10]. In addition, some studies have shown that there is evidence of brain edema in the perianeurysmal tissue after aneurysm treatment [11, 12]. The prolongation of TTP on the 3rd day in our patients may be due to recent processing and process-related vascular effects.

Shortening of TTP in patients at the 1st month shows the effect of complications such as postoperative vasospasm or brain edema. It can be used as a parameter for rCBV, rCBF and TTP perfusion changes in large aneurysms and can be used as TTP perfusion parameter in small aneurysms. This parameter may allow the use of markers in the determination and follow-up of conditions such as vasospasm, brain edema after endovascular treatment of small aneurysms.

As conclusion, TTP parameter can be used as a hemodynamic parameter regardless of the size of the aneurysm. This hemodynamic parameter can be used as a quantitative indicator in the determination of the complications related to aneurysms.

## REFERENCES

1. Kumral K. Serebrovasküler hastalıklar. Bornova İEÜM, 1975. Serebrovasküler hastalıklar. Bornova, İzmir: Ege Üniversitesi Matbaası, 1975.
2. Bornett JM, Mohr JP, Stein BM, Yatnu FM. Intracranial aneurysms Diagnosis and Management. Stroke, Newyork.
3. Ecker RD, Murray RD, Seder DB. Hyperperfusion Syndrome after Stent/Coiling of a Ruptured Carotid Bifurcation Aneurysm. Neurocrit Care 2013;18:54-8.
4. Liangder Jou GB. Correlation Between Aneurysm Size and Hemodynamics in One Individual with Multiple Small Intracranial Aneurysms. 2016 :Cureus 8(7): e683 DOI 107759/cureus683.
5. Ayhan T, M. Akif B, Cevdet G, Nurullah E, ve ark. Intracranial Giant Aneurysms: Report of two Cases. Türk Nöroşirürji Dergisi, 2006, Cilt: 16, Sayı: 3, 183-187.
6. Ayhan T, M. Akif B, Cevdet G, Nurullah E, ve ark. Intracranial Giant Aneurysms: Report of two Cases. Türk Nöroşirürji Dergisi, 2006, Cilt: 16, Sayı: 3, 183-187.
7. Otani T, li S, Shigematsu T, et al. Computational study for the effects of coil configuration on blood flow characteristics in coil-

embolized cerebral aneurysm. Medical & biological engineering & computing 2016.

**8.** Cheng XQ, Zhou CS, Chen Q, et al. Cerebral Hemodynamic Evaluation of Parent Artery Occlusion for Giant Intracranial Aneurysm in Patients who Tolerated Balloon Test Occlusion: Two Case Reports. Turkish neurosurgery 2015;25:959-62.

**9.** Oya S, Fujisawa N, Matsui T. Hemichorea-hemiballismus caused by postoperative hyperperfusion after clipping of a giant unruptured middle cerebral artery aneurysm. Surgical neurology international 2015;6:84.

**10.** Hohlrieder M, Spiegel M, Hinterhoelzl J, et al. Cerebral vasospasm and ischaemic infarction in clipped and coiled intracranial aneurysm patients. Eur J Neurol 2002;9:389-99.

**11.** Su IC, Willinsky RA, Fanning NF, et al. Aneurysmal wall enhancement and perianeurysmal edema after endovascular treatment of unruptured cerebral aneurysms. Neuroradiology 2014;56:487-95.

**12.** Sim KJ, Yan B, Dowling RJ, et al. Intracranial aneurysms with perianeurysmal edema: long-term outcomes post-endovascular treatment. Journal of neuroradiology Journal de neuroradiologie 2015;42:72-79. ;33:173-6.