

RESEARCH  
ARTICLE

 Handan Derebasinlioglu<sup>1</sup>  
 Sanem Nemmezi Karaca<sup>2</sup>

<sup>1</sup>Plastic Reconstructive and Aesthetic Surgery Department Sivas Cumhuriyet University Medical Faculty, Sivas, Turkey  
<sup>2</sup>Family Medicine Department Sivas Cumhuriyet University Medical Faculty, Sivas, Turkey

**Corresponding Author:**  
Handan Derebasinlioglu  
Plastic Reconstructive and Aesthetic Surgery Department, Sivas Cumhuriyet University Medical Faculty, Sivas, Turkey  
mail:handanderebasinlioglu@gmail.com  
Phone: +90 532 240 87 67

Received: 26.03.2020  
Acceptance: 12.07.2020  
DOI: 10.18521/ktd.708364

**Konuralp Medical Journal**  
e-ISSN1309-3878  
konuralptipdergi@duzce.edu.tr  
konuralptipdergisi@gmail.com  
www.konuralptipdergi.duzce.edu.tr

## A 20-Year Retrospective Analysis of Skin Cancers: Comparison of the First and Second Decades

### ABSTRACT

**Objective:** The incidence of skin cancer increases day by day depending on environmental factors. Developing diagnostic and pathological methods provide correct typing of skin cancers.

**Methods:** This retrospective analysis included patients who presented to and were scheduled for treatment at Sivas Cumhuriyet University Plastic Reconstructive and Aesthetic Surgery Clinic between January 1, 2000 and December 31, 2019 due to skin cancer and carcinoma in situ. The results were divided two groups as first ten years and second ten years. The groups were compared among themselves in terms of cancer type, age, gender and localization.

**Results:** 619 cases of 652 skin cancer and in situ carcinoma results were detected. When the groups were compared in terms of tumor types detected, there was a significant increase in MM, Bowen's disease, and rare NMSC subtypes other than SCC and BCC in the second decade ( $p<0.001$ ). Comparison of NMSC and MSC rates between the groups showed that the incidence of MSC had increased significantly from 5.2% to 10% in the past 10 years ( $p<0,05$ ).

**Conclusions:** Rare Non-melanocytic skin cancer group includes many types of carcinoma, there are various treatment protocols. Furthermore, many members of this group are known to be more aggressive than Basal cell carcinoma and squamous cell carcinoma. There are no consensus especially for approaches targeting lymph nodes. Closely following is necessary for early detection of recurrences and metastases.

**Keywords:** Skin Cancer, Non-Melanocytic Skin Cancer, Melanocytic Skin Cancer, Merkel Cell Carcinoma, Malignant Eccrine Poroma, Malignant Nodular Hidradenoma

## Cilt Kanserlerinin 20 Yıllık Retrospektif Analizi: Birinci 10 Yıl İle İkinci 10 Yılın Karşılaştırılması

### ÖZET

**Amaç:** Çevresel faktörlere bağlı olarak cilt kanserlerinin insidansı gün geçtikçe artmaktadır. Gelişen tanısal ve patolojik metotlar kanserlerin daha doğru tiplendirilmesine yardımcı olmaktadır.

**Gereç ve Yöntem:** Çalışmamızda cilt kanserleri ve in situ karsinom nedeniyle 1 Ocak 2000-31 Aralık 2019 tarihleri arasında kliniğimizde tedavi amacıyla başvuran ve tedavisi planlanan hastalar dahil edildi. Hastalar ilk on yıl ikinci on yıl olarak iki gruba ayrıldı. Gruplar; kanser tipi, yaş, cinsiyet ve lokalizasyon açısından karşılaştırıldı.

**Bulgular:** 619 vakaya ait 652 cilt kanseri ve insitu karsinom tespit edildi. Gruplar karşılaştırıldığında ikinci on yılda malign melanoma, Bowen hastalığında ve nadir gözlenen Non Melanositik Cilt Kanseri (NMCK)'nin alt tiplerinde anlamlı bir artış olduğu gözlemlendi ( $p<0,001$ ). NMCK ve Melanositik Cilt Kanseri (MCK) karşılaştırıldığında MCK insidansının son 10 yılda %5.2 den % 10 a yükselmesi istatistiksel açıdan anlamlı idi ( $p<0,05$ ).

**Sonuç:** Nadir gözlenen NMCK'ler çeşitli tedavi protokolleri olan pek çok karsinom tiplerini içermektedir. Ayrıca bu grubun pek çok üyesinin Bazal Hücreli Kanser ve Skuamöz Hücreli Kanserden daha agresif seyrettikleri bilinmektedir. Özellikle lenf nodlarına karşı yaklaşım hakkında ortak bir konsensüs bulunmamaktadır. Rekürrens ve metastazların erken tespit edilebilmesi için yakın takip gereklidir.

**Anahtar Kelimeler:** Deri Kanseri, Melanositik Olmayan Deri Kanseri, Melanositik Deri Kanseri, Merkel Hücreli Karsinom, Malign Ektrin Poroma, Malign Nodüler Hidradenom

## INTRODUCTION

Non-melanocytic skin cancers (NMSC) are the 5th most common type of cancer, while melanomas rank 19th (1). Malignant melanoma (MM) accounts for only 2% of all skin cancers but is the most common cause of skin cancer-related deaths (2). Basal cell carcinoma (BCC) and squamous cell carcinoma (SCC) are the most common types of NMSC, while other rarer subtypes such as Merkel cell carcinoma (MCC), Porocarcinoma (PC), and Hidradenocarcinoma account for less than 1% of cases (3). According to Turkish Cancer Statistics data (2015), the number of newly reported cases of melanocytic skin cancer increased from 330 in 2011 to 618 in 2015. For NMSCs, 4,450 new cases were reported in 2011 and this figure jumped to 8,800 in 2015 (4). The aim of this study was to determine changes in the incidence and distribution of skin cancers between the first and second decades of a 20-year period.

## MATERIAL AND METHODS

This retrospective analysis included patients who presented to and were scheduled for treatment at Sivas Cumhuriyet University Plastic Reconstructive and Aesthetic Surgery Clinic between January 1, 2000 and December 31, 2019 due to skin cancer and carcinoma in situ. The patients were divided into two groups: those who presented between January 1, 2000 and December 31, 2009 comprised Group 1 and those who presented between January 1, 2010 and December

31, 2019 comprised Group 2. Both groups were evaluated in terms of age, sex, tumor type, number of cases, localization, reconstruction method and increase in tumor type. Patients whose patient files and pathology results were not reached, these were excluded from the study. Ethical approval for the study was obtained from the Cumhuriyet University Ethics Committee. (Decision no:2020-01/41).

**Statistical Analysis:** The collected data were uploaded to the SPSS (version 23.0) software package and tested for normal distribution using the Kolmogorov–Smirnov test. Data analyses included descriptive statistics (frequency, percent, etc.), as well as chi-square test in 2x2 and multicell tables for discrete qualitative data and Mann–Whitney U test for measured data because they did not meet parametric test assumptions. The type I error level was 0.05.

## RESULTS

Data pertaining to 619 patients were accessed and a total of 652 skin cancers and in situ carcinomas were identified. Of this patient group, 40.9% (n=253) were in Group 1 and 59.1% (n=366) were in Group 2. When all lesions were evaluated, 61.4% (n=393) of the cancers were BCC, 27.5% (n=176) were SCC, 7.97% (n=51) were MM, and 3.13% (n=20) were other NMSC subtypes. NMSC accounted for 90.3% (n=589) of all lesions, MSC for 7.8% (n=51), and the prevalence of Bowen's disease was 1.8% (n=12). (Table 1 and 2).

**Table 1.** Distributions of Subtypes of Carcinomas and Anatomical Location

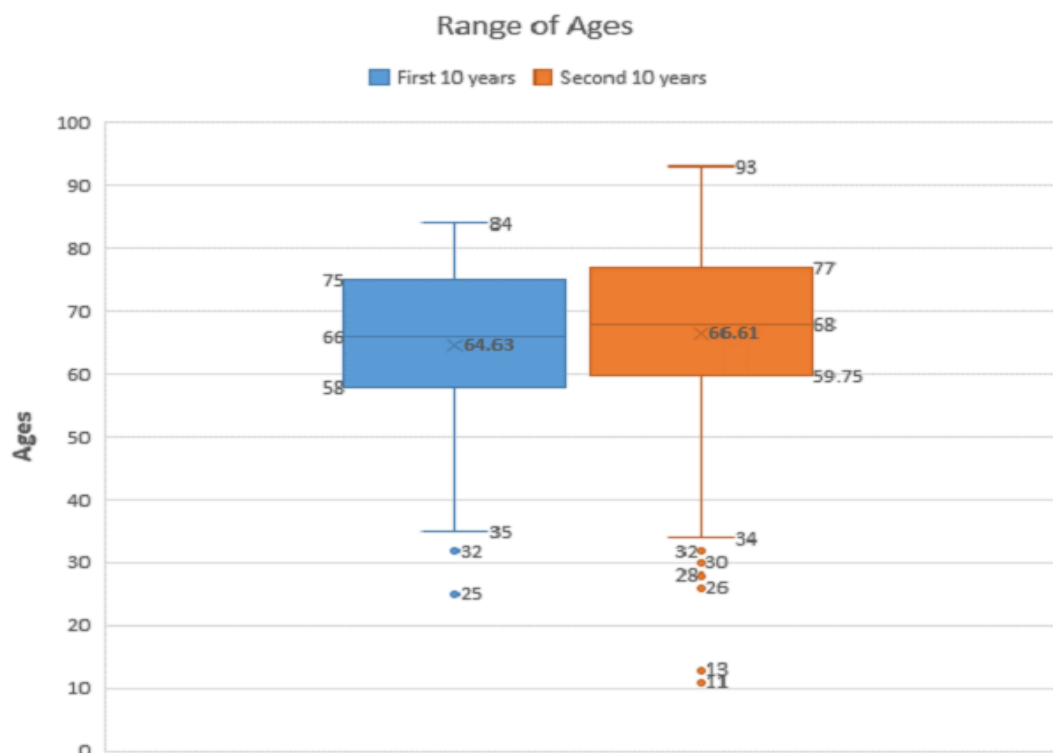
Groups	Basal Cell Carcinoma		Squamous Cell Carcinoma		Malignant Melanoma		Bowen Diseases		Others		TOTAL
	I	II	I	II	I	II	I	II	I	II	
Scalp	4	30	5	10	2	3	0	1	0	0	55
Forehead	26	17	3	2	2	4	0	0	0	1	55
Nose	50	66	2	13	1	0	0	0	0	2	134
Ear	5	6	1	2	0	0	0	0	0	1	15
Periorbital area	53	47	2	7	1	1	0	0	0	2	113
Lower lip	2	2	34	34	2	2	0	1	0	1	78
Upper lip	5	6	4	6	0	0	0	1	0	0	22
Cheek	25	31	6	10	2	4	0	2	0	0	80
Lower extremite	2	3	12	5	1	13	0	1	0	4	41
Upper extremite	0	1	6	7	1	6	1	3	0	3	28
Trunk	1	5	2	0	2	3	0	2	2	4	21
Neck	2	4	2	1	0	1	0	0	0	0	10
Total	175	218	79	97	14	37	1	11	2	18	652

**Table 2.** Uncommon Types of NMSC

Uncommon Types of NMSC	Group 1	Group 2
Dermatofibrosarcoma Protuberans	0	5
Basosquamous Cell Carcinoma	0	1
Spindle Cell Carcinoma	0	2
Sebaceous Carcinoma	0	1
Merkel Cell Carcinoma	2	1
Caposi Sarkoma	0	1
Verrucous Carcinoma	0	1
Malignant Nodular Hidradenoma	0	1
Epithelioid sarcoma	0	1
Malignant Eccrine Poroma	0	2
Total	2	16

The study sample comprised 39.1% female (n=242) and 60.9% male (n=377) patients. Analysis of sex distribution by group showed that Group 1 included 153 males (60.5%) and 100 females (39.5%), while Group 2 included 224 (61.2%) males and 142 (38.8%) females. Mean age was 65.9 ± 13.6 (11–93) years in the entire patient group, 64.7 ± 12.1 (25–84) years in Group 1, and 66.4 ± 14.1 (11–93) years in Group 2. (Graphic1)

When the two groups were compared based on the median age of patients diagnosed with the different cancer types, there were no significant age differences except for BCC (p<0.05) (Table 3).



**Graphic 1.** Range of ages

**Table 3.** Statistical analysis of age and tumour subtypes

	Mean Ranks For Ages	Median ± SD (min-max)	Results
<b>BCC</b>			
The first ten years (n:74)	112.41	67 ± 12.787	p:0.005*
The second ten years (n:193)	142.28	(26-93)	
<b>SCC</b>			
The first ten years (n:46)	72.23	69 ± 11.744	p:0.884
The second ten years (n:96)	71.15	(25-90)	
<b>MM</b>			
The first ten years (n:6)	25.50	62 ± 20.465	p:0.461
The second ten years (n:37)	21.43	(11-90)	
<b>Bowen</b>			
The first ten years (n:1)	5.00	65 ± 14.514	p:0.751
The second ten years (n:10)	6.10	(34-85)	
<b>Other</b>			
The first ten years (n:2)	13.00	67 ± 14.902	p:0.528
The second ten years (n:18)	10.22	(33-87)	

\*p<0.05; Mann Whitney U test was used.

When the first and second decades were compared in terms of the types of cancers detected, there was no significant difference for male patients ( $p>0.05$ ). However, there was a significant increase in other rare NMSCs in female patients ( $p<0.05$ ). Comparison of MSC and NMSC subgroups revealed that the incidence of MSC had increased from 27.8% ( $n=5$ ) to 72.2% ( $n=13$ ) in females and from 27.3% ( $n=9$ ) to 72.7% ( $n=24$ ) in males, but these differences were not statistically significant ( $p>0.05$ ).

The most common type of skin tumor in Group 1 was BCC ( $n=175$ , 64.6%), followed by SCC ( $n=79$ , 29.2%). The incidence of MM was 5.2% ( $n=14$ ). Bowen's disease was detected in only one patient, while other NMSCs accounted for 0.7% of the lesions ( $n=2$ ). MCC was detected in two patients who had an NMSC other than SCC or BCC. Among the NMSCs, 68.3% ( $n=175$ ) were BCC, 30.8% ( $n=79$ ) were SCC, and 0.8% ( $n=2$ ) were other rare NMSC subtypes. Lesions in non-head and neck locations accounted for 11.1% ( $n=30$ ).

Similarly, the most common skin cancers in Group 2 were BCC (57.2%,  $n=218$ ) and SCC (25.5%,  $n=97$ ). MM was detected in 9.7% ( $n=37$ ) and Bowen's disease in 2.9% ( $n=11$ ) of the patients. Other NMSC subtypes were detected in a total of 16 lesions (4.7%). In the past 10 years there were 333 cases of NMSC (90%) and 37 cases of MSC (10%). Of the NMSCs, 65.4% ( $n=218$ ) were BCC, 29.1% ( $n=97$ ) were SCC, and 5.4% ( $n=18$ ) were other rare NMSC subtypes. Sixty lesions (15.7%) occurred in non-head and neck localizations.

When the groups were compared in terms of tumor types detected, there was a significant increase in MM, Bowen's disease, and rare NMSC subtypes other than SCC and BCC in the second decade ( $p<0.001$ ). Comparison of NMSC and MSC rates between the groups showed that the incidence of MSC had increased significantly from 5.2% to 10% in the past 10 years ( $p<0.05$ ) (Table 4). In terms of tumor location, there was a significant increase in tumors located on the scalp and decrease in those located on the forehead and periorbital region ( $p<0.05$ ) (Table 4).

**Table 4.** Statistical analysis of groups

	Group 1 n (%)	Group 2 n (%)	Results
<b>Sex</b>			
Female	100 (39.5)	142 (38.8)	$X^2$ : 0.033 $p$ :0.867
Male	153 (60.5)	224 (61.2)	
Total	253	366	
<b>Types of Carcinomas</b>			
BCC	175 (66.6)	218 (57.2)	$X^2$ : 20.064 $p<0.001$ **
SCC	79 (29.2)	97 (25.5)	
MM	14 (5.2)**	37 (9.7)**	
Bowen	1 (0.4)**	11 (2.9)**	
Others	2 (0.7)**	18 (4.7)**	
Total	271	381	
<b>Distributions of Carcinomas</b>			
NMSC	256 (94.8)	333 (90.0)	$X^2$ : 4.934 $p$ :0.026*
MSC	14 (5.2)	37 (10.0)	
Total	271	370	
<b>Anatomic Distributions of Carcinomas</b>			
Scalp	11 (4.1)**	44 (11.5)**	$X^2$ : 23.609 $p$ :0.014**
Forehead	31 (11.4)**	24 (6.3)**	
Nose	53 (19.6)	81 (21.3)	
Ear	6 (2.2)	9 (2.4)	
Periorbital region	56 (20.7)**	57 (15.0)**	
Lower lip	38 (14.0)	40 (10.5)	
Upper lip	9 (3.3)	13 (3.4)	
Cheek	33 (12.2)	47 (12.3)	
Lower Extremite	15 (5.5)	26 (6.8)	
Upper Extremite	8 (3)	20 (5.2)	
Trunk	7 (2.6)	14 (3.7)	
Neck	4 (1.5)	6 (1.6)	
Total	271	381	
<b>Region</b>			
Head and neck	241 (88.9)	321 (84.3)	$X^2$ : 2.913 $p$ :0.088
Other	30 (11.1)	60 (15.7)	
Total	271	381	

\* $p<0.05$  \*\*Chi square test was used; Bonferroni test was used for subgroups.

Recurrences accounted for 5.1% (n=33) of all lesions. Reconstruction techniques used were primary repair in 21.2% (n=138), graft in 34.4% (n=224), and flap in 42.8% (n=279) of the lesions. Distant flaps were used in 5.39% (n=15) of flap reconstructions, while the rest utilized local flaps. Tumor-related amputation was performed in 1.4% (n=9) of the patients. Two patients refused surgery and were referred for radiotherapy.

#### DISCUSSION

Skin cancers are among the most common cancers. The most frequent type of skin cancer is BCC, which is more benign than other types. SCC and other rare NMSC subtypes tend to be more aggressive. Although MMs are responsible for most skin cancer-related deaths, high rates of recurrence and metastasis have also been reported for NMSCs such as MCC, Porocarcinoma, and sebaceous carcinoma. These tumors reportedly account for less than 1% of NMSCs (5), but their incidence in the second decade of our series was 4.7%, which is substantially higher than rates reported in the literature.

Merkel cell carcinoma is an aggressive neuroendocrine skin tumor (6). The number of patients diagnosed increases each year, which is believed to be due in part to the advanced methods used for the diagnosis of this tumor (7). Although 75% of cases are diagnosed as local disease, recurrence rates are high, at 30% (7,9). Even in localized disease, lymph node involvement can occur in 25% of cases (10). One of the most important prognostic factors is lymph node involvement (8,11-13). However, there is no consensus on elective lymph node dissection. Involvement is detected in about 30% of patients who undergo sentinel lymph node biopsy (SLNB) (6). Like other neuroendocrine tumors, it is radiosensitive (14). A total of three MCCs were identified in our series. Of the two patients with tumors located on the back, axillary single node metastasis was detected in one patient and involvement of four inguinal lymph nodes was detected in the other patient. No lymph node involvement was detected in the one patient in the second decade.

Hidradenocarcinoma has an incidence of less than 0.001% (15,16). Because it is so rare, the treatment protocols used are a subject of debate. It has local recurrence rates up to 50% and metastasis rates of around 60% despite wide excision, which is the generally accepted treatment method (17,18,19). As dermal lymphatic invasion, nerve sheath involvement, deep structure infiltration, positive resection margins, highly anaplastic morphology, and extracapsular lymph node spread are associated with high recurrence rates, these patients have been recommended adjuvant radiotherapy (20,21). Furthermore, successful outcomes have been reported regarding preoperative radiotherapy (22).

Although some authors recommend prophylactic lymph node dissection because of high lymphatic involvement (23,24), it has also been emphasized that SLNB provides tumor-free survival, even if the number of the cases is limited (25-27). Due to high recurrence and metastasis rates, antihormone therapy to prevent spread has also been proposed as beneficial for the treatment of these tumors in receptor-positive cases (27). A 67-year-old woman in our series had a MNH on her lower lip. No lymphatic involvement or distant metastasis was detected at the time of diagnosis. The patient underwent wide excision and is currently in her second postoperative year of follow-up with no recurrence or metastasis.

Porocarcinoma accounts for 0.005–0.01% of skin tumors (28,29). Metastatic disease is present in 22.3% of patients at the time of diagnosis (30). It is an aggressive tumor with recurrence and metastasis rates of about 20% despite curative surgery (29,30). The generally accepted treatment is surgical excision. Poor prognostic factors include lymphovascular invasion, high mitosis, tumor thickness over 7 mm, irregular tumor margins, and poor differentiation (32,33). In addition, tumor location is also an important factor for prognosis. Primary lesions in the upper and lower extremities, trunk, hips, and genital area are associated with higher risk of lymph node metastasis than tumors located in the head and neck region. SLNB is recommended for patients in the high-risk group (29). Lymph node positivity is reported to increase to 50% for tumors that are poorly differentiated (34,35). Despite reports that response to radiotherapy and chemotherapy was poor (36) and radiotherapy had no effect on survival, radiotherapy can be used for patients with positive surgical margins and those not eligible for surgery (37). There were two cases of MEP in our series. One was located on the lower eyelid of a 75-year-old patient, while the other was located in the gluteal region of an 83-year-old patient, both of whom were women. No lymphatic involvement or distant metastasis was detected at the time of diagnosis in the patient with the eyelid tumor. She underwent wide excision and has been under follow-up for 1.5 years. The tumor located in the gluteal region was reported to be carcinoma in situ.

Dermatofibrosarcoma protuberance (DFSP) is a soft tissue sarcoma with an incidence of four per million (38). It typically grows slowly and has less than 5% likelihood of regional or distant metastasis unless it transforms into a high-grade fibrosarcoma (39,40). Histopathologically, 3–20% of DFSPs contain fibrosarcomatous changes, and this finding is described as an independent risk factor for recurrence and distant metastases (39,41,42). Other risk factors for recurrence are a clean resection margin narrower than one millimeter or a positive surgical margin and tumor

size. Recurrence is more common with tumors larger than five centimeters (41). Most distant metastases are found in the lungs, but they are also known to metastasize to the bone, soft tissue, liver, kidneys, gastrointestinal tract, and lymph nodes (38). While metastasis was not observed in any of our cases, one of our patients presented with a fifth relapse.

Epithelioid sarcoma (ES) is a rare type of sarcoma with a reported incidence of 0.02–0.05 per 100,000 (43,44). There are two types of ES, proximal and conventional. The conventional type usually occurs in distal locations in the upper extremities, and is seen in adolescents and young men (45). The proximal type is less common, located on the trunk, and has poorer prognosis (46). It also occurs very rarely in the perineum, penis, and vulva (47,48). Treatment planning is based entirely on the presence or absence of lymphatic involvement and distant metastasis. Lymphatic involvement has been reported at rates of 10–80% (49-52). Preoperative evaluation of lymphatic involvement is important due to the high risk. Therefore, many authors recommend SLNB for accurate staging (50,52,53). Pre- or postoperative radiotherapy reduces local recurrence rates and is recommended as an adjunct to radical surgical treatment (50,53). In our patient, the tumor was located in the perineal region and the patient underwent wide excision, bilateral groin dissection, and chemoradiotherapy. While receiving radiotherapy, metastasis developed on the skin of the vulva at postoperative five months. The vulvar metastasis was controlled with wide surgical excision. However, the patient died one and a half years later due to distant metastasis and recurrence.

Sebaceous carcinoma is an aggressive adnexal tumor with two types, ocular (OSC) and extraocular (EOSC). The ocular type is more common but more aggressive than the extraocular type (54). As few cases of EOSC have been described, a definite consensus regarding treatment has yet to be reached, and there are conflicting views in the literature. The generally accepted treatment is wide tumor resection (55). Different figures have been reported regarding its lymphatic involvement and metastasis rates. Lymphatic metastasis rates of 1.3–16% and non-lymph node metastasis rates of 0.4–10% have been reported (55,56). Due to these different rates, there are different attitudes regarding the use of sentinel lymph nodes. Some authors report that subclinical nodal spread is rare for EOSC and few SLNBs are positive (57-59), while others argue that EOSC is a locally aggressive tumor with a high likelihood of regional nodal metastasis and that regional nodal dissection together with a wide local excision should be considered optimal (55). For optimal treatment, SLNB may be helpful in determining subclinical lymphatic involvement in high-risk patients, particularly those with tumors thicker than

two millimeters, tumors with a Clark stage over 4, lymphovascular invasion, perineural invasion, bone infiltration, and anaplasia or poorly differentiated tumors (55,60). Although the role of adjuvant radiotherapy is controversial, radiotherapy can be given after complete tumor resection either alone or in combination with chemotherapy (55). Primary radiotherapy alone is not recommended due to high recurrence rates (56,58,60). It can be used in patients who refuse surgery or cannot undergo surgery due to comorbidities, and there are also publications that recommend its postoperative use after resection (55). Our patient was an 85-year-old man with nasally located cancer. Although his cervical lymph nodes were positive at the time of diagnosis, he did not consent to neck dissection and was lost to follow-up.

Detection of spindle cells in pathologic examination is suggestive of spindle squamous cell carcinoma, spindle-cell melanoma, pleomorphic undifferentiated sarcoma, and leiomyosarcoma in diagnosis (61). Spindle and basal cells may also be found in the sarcomatous type of BCC (62). In fact, it has been emphasized that basal cells may be overlooked in some cases (62-65). This subtype exhibits aggressive behavior and has metastatic potential (62). The spindle cell variant of SCC is rare. While it can be seen in sun-exposed regions and radiotherapy areas (66). It is a poorly differentiated form of SCC (61) and progresses more aggressively (62). The spindle variant of MM is in the vertical growth phase. Like the SCC variant, it occurs in sun-exposed areas (62). It is detected as widespread metastatic disease (67,68). In our series, spindle cell carcinoma was detected in two patients, both patients were over 70 years of age and the tumors were located on the face. The pathology department reported them as spindle cell carcinomas, with no subtyping.

In this study, the quantitative increase observed in MM, Bowen's disease, and rare types of NMSC in the second decade was statistically significant. The increase in Bowen's disease may be considered a result of early diagnosis.

The number of patients with MM is increasing daily worldwide (69) and our country (70). The increase in our series is consistent with the literature. This increase has also been observed in the pediatric age group (71). Pediatric malignant melanoma (PMM) accounts for 1–4% of all cases of melanoma (72). Although prognosis is more favorable in the pediatric age group (72-74), MM is a deadly disease and should be treated aggressively. Diagnosing PMM can be difficult, even for experienced physicians. Misdiagnosis in this age group has been reported at around 40% (75,76). Nodular PMMs may exhibit a pyogenic granuloma-like morphology (76,77). In the pediatric age group, PMM should not be overlooked in the differential diagnosis of pigment-free lesions with benign morphology. The treatment protocol is the same as

the protocol for adults. However, sentinel lymph node involvement occurs at a higher rate than in adults (72). Two of the MM patients in the second decade were in the pediatric age group and MM was detected incidentally. One patient was 13 years old and presented with a long-standing unpigmented granulomatous lesion on the front of the thigh. The result of incision biopsy was reported as PMM. Sentinel sampling was performed in this case because Breslow's depth was 6 mm. SLNB was positive and the patient underwent lymph node dissection. MM involvement was not observed in any of the nodes dissected after the sentinel lymph node. The other patient presented because of a nail change and excisional biopsy was performed upon observation of irregular pigmented lesions on the anterior surface of the tibia. The pathology result was reported as superficial spreading MM. The Breslow's depth of the tumor was 0.5 mm. Both of patients are in the second year of postoperative follow-up with no recurrence or metastasis. Although there were a small number of pediatric patients in our study, pediatric patients represented 3.9% of all cases of MM detected in 20 years.

The most important limitation in our study is that the hospital in which we are working has a patient profile limited with local region and it is a single center study. Although small skin cancers are treated in state hospitals in our region, metastatic tumors such as SCC, MM, big size tumors and rare forms are consulted and this contributes positively to our work.

The pathological differential diagnosis of rare NMSC subtypes such as MCC, MNH, MEP

and sebaceous carcinoma includes BCC and SCC. Different immunohistochemical dyes are used for differential diagnosis (79-82). This increase may be due to an increase in the number of cases or it may be related to more accurate diagnosis with advanced detection methods and staining techniques. As this group includes many types of carcinoma, there are various treatment protocols. Furthermore, many members of this group are known to be more aggressive than SCC and BCC. However, for many types of cancer there are a limited number of cases in the literature and no clear consensus regarding treatment. This creates a limitation, especially for approaches targeting lymph nodes. Treatment protocols are based on case reports and a few case series. It should be kept in mind that without the correct approach and follow-up planning, morbidity and mortality will be higher, especially in patients with aggressive types. This increases the importance of closely following patients for early detection of recurrences and metastases.

#### **Declaration of Conflicting Interests**

The author(s) declared no potential conflicts of interest with respect to the research, authorship, and/or publication of this article.

#### **Funding**

The author(s) received no financial support for the research, authorship, and/or publication of this article.

**Ethical approval:** The approval of Cumhuriyet University Ethical Committee was satisfied. Decision no:2020-01/41.

## **REFERENCES**

1. <https://www.wcrf.org/dietandcancer/cancer-trends/skin-cancer-statistics> World Cancer Research Fund International
2. Holm RP. Skin cancer prevention and screening. *S D Med*. 2015; 75(7) 79-81.
3. Eisemann N, Waldmann A, Geller AC, Weinstock MA, Volkmer B, Greinert R, et al. Nonmelanoma skin cancer incidence and impact of skin cancer screening on incidence. *J Invest Dermatol* 2014;134(1):43-50.
4. Türkiye kanser kontrol programı (2018) Halk Sağlığı Genel Müdürlüğü <https://hsgm.saglik.gov.tr> › Ulusal\_Kanser\_Kontrol\_Planı\_2013\_2018
5. Katalinic A, Kunze U, Schafer T Epidemiology of cutaneous melanoma and non-melanoma skin cancer in Schleswig-Holstein, Germany: incidence, clinical subtypes, tumour stages and localization (epidemiology of skin cancer). *Br J Dermatol*. 2003 149:1200–6
6. Perez MC, Oliver DE, Weitman ES, Boulware D, Messina JL, Torres-Roca J Management of Sentinel Lymph Node Metastasis in Merkel Cell Carcinoma: Completion Lymphadenectomy, Radiation, or Both? *Ann Surg Oncol*. 2019 Feb;26(2):379-385
7. Saeb-Lima M, Montante- Montes de Oca D, Albores Saavedra J. Merkel cell carcinoma with eccrine differentiation: a clinicopathologic study of 7 cases. *Ann Diagn Pathol* 2008; 12: 410.
8. Medina-Franco H, Urist MM, Fiveash J, Heslin MJ, Bland KI, Beenken SW et al Multimodality treatment of Merkel cell carcinoma: Case series and literature review of 1024 cases. *Ann Surg Oncol*. 2001 ;8(3):204-8.
9. Karakousis CP, Balch CM, Urist MM, Ross MM, Smith TJ, Bartolucci AA. Local recurrence in malignant melanoma: longterm results of the multiinstitutional randomized surgical trial. *Ann Surg Oncol*. 1996;3:446–52
10. Peter J. Allen, Wilbur B. Bowne, David P. Jaques, Murray F. Brennan, Klaus Busam, and Daniel G. Coit Merkel Cell Carcinoma: Prognosis and Treatment of Patients From a Single Institution *J Clin Oncol* 2005; 23:2300-9

11. Pitale M, Sessions RB, Husain S. An analysis of prognostic factors in cutaneous neuroendocrine carcinoma. *Laryngoscope* 1992;102:244–9
12. Fenig E, Brenner B, Katz A, Rakovsky E, Hana MB, Sulkes A. The role of radiation therapy and chemotherapy in the treatment of Merkel cell carcinoma. *Cancer* 1997;80:881–5.
13. Victor NS, Morton B, Smith JW. Merkel cell cancer: is prophylactic lymph node dissection indicated? *Am Surg* 1996; 62:879–82
14. Carney DN, Gazdar AF, Bepler G, Guccion JG, Marangos PJ, Moody TW, et al. Establishment and identification of small cell lung cancer cell lines having classic and variant features. *Cancer Res.* 1985 Jun;45(6):2913-23.
15. Mehregan AH, Hashimoto K, Rahbari H. Eccrine adenocarcinoma: a clinicopathologic study of 35 cases. *Arch Dermatol.* 1983;119(2):104-14.
16. Vernekar SS, Priyadarshini Bargunam P. Malignant nodular hidradenoma-inguinal region clinically masquerading as squamous cell carcinoma: a case report. *Int J Res Med Sci.* 2019 ;7(7):2848-2852
17. Amel T., Olfa G.,Faten H. ,Makrem H, Slim B.A., Moncef M. Metastatic hidradenocarcinoma: surgery and chemotherapy *N Am J Med Sci.* 2009 ; 1(7): 372–374.
18. Rafols M, Mejia O, Oh KS, Bendixen B, Jorge I, Narayanan S.An Unusual Case of Lower Extremity Clear Cell Hidradenocarcinoma. *Case Rep Surg.* 2020 ; 8;1-4
19. Souvatzidis P, Sbrano P, Mandato F, Fimiani M, Castelli A. Malignant nodular hidradenoma of the skin: report of seven cases. *J Eur Acad Dermatol Venereol.* 2008 May;22(5):549-54.
20. Hall J, Kneey G, A'Hern RP, et al. Sweat-gland Tumours: A Clinical Review of Cases in One Centre Over 20 Years. *Clin Oncol.* 2006;18:351–359. [PubMed] [Google Scholar]
21. Harari PM, Shimm DS, Bangert JL, Cassady JR. The role of radiotherapy in the treatment of malignant sweat gland neoplasms. *Cancer.* 1990 Apr 15;65(8):1737-40.
22. Nongkynrih A, Kamboj K, Dhull A.K, Kaushal V. Miraculous response to radiotherapy in a rare case of malignant nodular hidradenoma nose. *J Cancer Prev Curr Res.* 2018;9(3):97–99.
23. Jouary T, Kaiifa A, Lipinski P, Vergier B, Lepreux S. Metastatic hidradenocarcinoma: efficacy of capecitabine. *Arch Dermatol* 2006; 142: 1366–1367.
24. Khalil HM, Yusuf H, Kaddour HS. Malignant eccrine hidradenoma of neck causing acute heart failure. *Auris Nasus Larynx.* 2003 ;30(3):307-10.
25. Chang AS, Busam MD, Kraus DK. Applicability of lymphoscintigraphy with sentinel node biopsy to eccrine carcinoma of the head and neck. *Head Neck.* 2003 ;25(10):879-82
26. Bogner PN, Fullen DR, Lowe L, Paulino A, Biermann JS, Sondak VK, et al. Lymphatic mapping and sentinel lymph node biopsy in the detection of early metastasis from sweat gland carcinoma. *Cancer* 2003;97(9):2285–9
27. Tolland JP, Brenn T, Guldbakke KK, Schanbacher CF. Mohs micrographic surgery sentinel lymph node mapping, and estrogen receptor analysis for the treatment of malignant nodular hidradenoma. *Dermatol Surg.* 2006 Oct;32(10):1294-301.
28. Riera-Leal L, Guevara-Gutiérrez E, Barrientos-García JG, Madrigal-Kasem R, Briseño-Rodríguez G, Tlacuilo-Parra A. Eccrine porocarcinoma: epidemiologic and histopathologic characteristics. *Int J Dermatol.* 2015;54(5):580-6.
29. Bhat W, Akhtar S, Khotwal A, Platt AJ. Primary eccrine porocarcinoma of the finger with transit forearm and axillary metastasis. *Ann Plast Surg.* 2011 Apr;66(4):344-6
30. Nazem A, Higgins S, Swift R, In G, Miller K, Wysong A. Eccrine Porocarcinoma: New Insights and a Systematic Review of the Literature. *Dermatol Surg.* 2018;44(10):1247-61
31. Robson A, Greene J, Ansari N, Kim B, Seed PT, McKee PH, et al. Eccrine porocarcinoma (malignant eccrine poroma): a clinicopathologic study of 69 cases. *Am J Surg Pathol.* 2001 ;25(6):710-20.
32. Sawaya JL, Khachemoune A. Poroma: a review of eccrine, apocrine, and malignant forms. *Int J Dermatol.* 2014 ;53(9):1053-61
33. Tolkachjov S, Hocker T, Camilleri M, Baum C. Treatment of porocarcinoma with Mohs micrographic surgery: the Mayo Clinic experience. *Am Soc Dermatol Surg.* 2016;42:745–50.
34. Belin E1, Ezzedine K, Stanislas S, Lalanne N, Beylot-Barry M, Taieb A, et al. Factors in the surgical management of primary eccrine porocarcinoma: prognostic histological factors can guide the surgical procedure. *Br J Dermatol.* 2011;165(5):985-9
35. Swanson JD Jr., Pazdur R, Sykes E. Metastatic sweat gland carcinoma: Response to 5-fluorouracil infusion. *J Surg Oncol,* 1989; 42(1): 69–72
36. Vleugels FR1, Girouard SD, Schmults CD, Ng AK, Russell SE, Wang LC, et al. Metastatic eccrine porocarcinoma after Mohs micrographic surgery: A case report. *J Clin Oncol.* 2012; 30(21): 188–91
37. Snow SN, Reizner GT. Eccrine porocarcinoma of the face. *J Am Acad Dermatol.* 1992;27(2):306–11.
38. Avraham JB, Villines D, Maker VK et al: Survival after resection of cutaneous adnexal carcinomas with eccrine differentiation: Risk factors and trends in outcomes. *J Surg Oncol.* 2013; 108(1): 57–62



39. Kreicher KL, Kurlander DE, Gittleman HR, Barnholtz-Sloan JS, Bordeaux JS. Incidence and survival of primary dermatofibrosarcoma protuberans in the United States. *Dermatol Surg.* 2016;42(1):S24-S31.
40. Liang CA, Jambusaria-Pahlajani A, Karia PS, Elenitsas R, Zhang PD, Schmults CD. A systematic review of outcome data for dermatofibrosarcoma protuberans with and without fibrosarcomatous change. *J Am Acad Dermatol.* 2014 Oct;71(4):781-6.
41. Rutkowski P, Debiec-Rychter M. Current treatment options for dermatofibrosarcoma protuberans. *Expert Rev Anticancer Ther.* 2015;15(8):901-9
42. Huis In 't Veld EA, van Coevorden F, Grünhagen DJ, Smith MJ, van Akkooi ACJ, Wouters MWJM, et al. Outcome after surgical treatment of dermatofibrosarcoma protuberans: Is clinical follow-up always indicated? *Cancer.* 2019 ;125(5):735-741
43. Hoesly PM, Lowe GC, Lohse CM, Brewer JD, Lehman JS. Prognostic impact of fibrosarcomatous transformation in dermatofibrosarcoma protuberans: a cohort study. *J Am Acad Dermatol.* 2015;72: 419-425
44. Frezza AM, Botta L, Pasquali S, et al. An epidemiological insight into epithelioid sarcoma (ES): the open issue of distal-type (DES) versus proximal type (PES). Presented at the European Society of Medical Oncology Annual Meeting, Madrid, Spain, September, 2017.
45. Frezza AM, Jones RL, Lo Vullo S, Asano N, Lucibello F, Ben-Ami E et al. Anthracycline, Gemcitabine, and Pazopanib in Epithelioid Sarcoma: A Multi-institutional Case Series. *JAMA Oncol.* 2018 1;4(9):e180219.
46. Spillane AJ, Thomas JM, Fisher C. Epithelioid sarcoma: the clinicopathological complexities of this rare soft tissue sarcoma. *Ann Surg Oncol.* 2000;7:218–25.
47. Gambini C, Sementa A, Rongioletti F. “Proximal-type” epithelioid sarcoma in a young girl. *Pediatr Dermatol.* 2004;21:117–20.
48. Spillane AJ, Thomas JM, Fisher C. Epithelioid sarcoma: the clinicopathological complexities of this rare soft tissue sarcoma. *Ann Surg Oncol.* 2000;7:218–25.
49. de Visscher SA, van Ginkel RJ, Wobbles T, Veth RP, Ten Heuvel SE, Suurmeijer AJ, et al Epithelioid sarcoma: Still an only surgically curable disease. *Cancer.* 2006 ;107(3):606-12.
50. Guzzetta AA, Montgomery EA, Lyu H, Hooker CM, Meyer CF, Loeb DM, et al. Epithelioid sarcoma: one institution's experience with a rare sarcoma. *J Surg Res.* 2012 ;177(1):116-22
51. de Visscher SA1, van Ginkel RJ, Wobbles T, Veth RP, Ten Heuvel SE, Suurmeijer AJ, et al. Epithelioid sarcoma: still an only surgically curable disease. *Cancer.* 2006 ;107(3):606-12
52. Sambri A, Bianchi G, Cevolani L, Donati D, Abudu A. Can radical margins improve prognosis in primary and localized epithelioid sarcoma of the extremities? *J Surg Oncol.* 2018 May;117(6):1204-10
53. Alex Seal A, Tse R, Wehrli B, Hammond A Temple C. Sentinel node biopsy as an adjunct to limb salvage surgery for epithelioid sarcoma of the hand. *World J Surg Oncol.* 2005 Jun 29;3:41
54. Sobanko JF1, Meijer L, Nigra TP. Epithelioid sarcoma: a review and update. *J Clin Aesthet Dermatol.* 2009 May;2(5):49-54.
55. Moreno C, Jacyk W.K., Judd M.J., Requena L. Highly Aggressive Extraocular Sebaceous Carcinoma. *Am J Dermatopathol.* 2001 ;23(5):450-5
56. Giridhar P., Kashyap L., Mallick S, Dutt Upadhyay A, Rath GK. Impact of surgery and adjuvant treatment on the outcome of extraocular sebaceous carcinoma: a systematic review and individual patient's data analysis of 206 cases. *Int J Dermatol.* 2020 Apr;59(4):494-505
57. Dasgupta T., Wilson L.D., Yu J.B. A retrospective review of 1349 cases of sebaceous carcinoma. *Cancer.* 2009 Jan 1;115(1):158-65.
58. Ornellas AA, Frota R, Lopes da Silva LF, Dauster B, Quirino R, de Santos Schwindt AB, et al. Sebaceous carcinoma of the penis. *Urol Int.* 2009;82(4):477-80.
59. Sawyer AR, McGoldrick RB, Mackey S, Powell B, Pohl M (2009) Should extraocular sebaceous carcinoma be investigated using sentinel node biopsy? *Dermatol Surg* 35:704–708
60. Kibbi N, Worley B, Owen JL, Kelm RC, Bichakjian CK, Chandra S, et al. Sebaceous carcinoma: controversies and their evidence for clinical practice *Arch Dermatol Res.* 2020;312(1):25-31
61. Kyllö R.L., Brady K.L. Hurst E.A. Sebaceous Carcinoma: Review of the Literature. *Dermatol Surg* 2015;41:1–15
62. Thornhill R. S., Scott T. Aggressive Spindle Cell Neoplasm Atlas of Mohs and Frozen Section Cutaneous Pathology Chapter 25 pp 241-242
63. John AM, Singh P, Handler MZ, Lambert WC. Aggressive Mimicry in Dermatology: When a Basal or Squamous Cell Carcinoma Mimics a Spindle Cell Tumor. *Skinmed.* 2018;16(1):39-41.
64. Fernandez-Flores A. Study of D2-40 immunoreactivity of the spindle cell areas of a metaplastic basal cell carcinoma (sarcomatoid basal cell carcinoma). *Appl Immunohistochem Mol Morphol.* 2012 Oct;20(5):518-22
65. Harvey NT1, Sinha A, Houghton DC, Beer TW, Kingston FJ, Yu L, et al. Basal cell carcinosarcoma: A report of 4 cases and review of the literature *Am J Dermatopathol.* 2014 Jun;36(6):483-9

66. Bigby SM, Charlton A, Miller MV, Zwi LJ, Oliver GF. Biphasic sarcomatoid basal cell carcinoma (carcinosarcoma): Four cases with immunohistochemistry and review of the literature. *J Cutan Pathol.* 2005;32:141-47.
67. John D, Jayalekshmi B, Mathew A S Mathew S.S Spindle Cell Squamous Cell Carcinoma with Unique Presentation in Middle Aged Indian Man: A Case Report. *East African Scholars J Med Sci* 2019;2(12): 697-99
68. Walia R, Jain D, Mathur SR, Iyer VK. Spindle cell melanoma: a comparison of the cytomorphological features with the epithelioid variant. *Acta Cytol.* 2013;57:557-61.
69. Shivamurthy A, Kudva R, Kudva A, Jaiprakash P. Metastatic spindle cell melanoma on cytology – A diagnostic challenge. *Our Dermatol Online.* 2019;10(2):159-62.
70. Baykal C, Atci T, Akay BN. Is the frequency of primary cutaneous melanoma increasing in Turkey? An evaluation of the experiences of two dermatology centers *Journal of Oncological Sciences* 2018;4(1): 19-23
71. Carr S, Smith C, Wernberg J. Epidemiology and Risk Factors of Melanoma. *Surg Clin North Am.* 2020 Feb;100(1):1-12
72. Offenmueller S, Leiter U, Bernbeck B, Garbe C, Eigentler T, Borkhardt A. Clinical characteristics and outcome of 60 pediatric patients with malignant melanoma registered with the German Pediatric Rare Tumor Registry (STEP). *Klin Padiatr.* 2017;229(6):322-28.
73. Omie Mills, MD, and Jane L. Messina, MD Pediatric Melanoma: A Review. *Cancer control J* 2009; 16(3):225-233
74. Downard CD, Rapkin LB, Gow KW. Melanoma in children and adolescents. *Surg Oncol.* 2007;16(3):215-20.
75. Paradela S1, Fonseca E, Pita-Fernández S, Kantrow SM, Diwan AH, Herzog C, et al. Prognostic factors for melanoma in children and adolescents: a clinicopathologic, single-center study of 137 Patients. *Cancer.* 2010;116(18):4334-44
76. Spatz A, Ruiter D, Hardmeier T, Renard N Wechsler J, Bailly C, et al. Melanoma in childhood: an EORTC-MCG multicenter study on the clinicopathological aspects. *Int J Cancer.* 1996;68:317-24.
77. Ducharme EE, Silverberg NB. Pediatric Malignant Melanoma: An Update on Epidemiology, Detection and Prevention. *Cutis.* 2009;84(4):192-8.
78. Jafarian F1, Powell J, Kokta V, Champagne M, Hatami A, McCuaig C V, et al. Malignant melanoma in childhood and adolescence: report of 13 cases. *J Am Acad Dermatol.* 2005;53(5):816-22
79. Tetzlaff MT, Harms PW. Danger is only skin deep: aggressive epidermal carcinomas. An overview of the diagnosis, demographics, molecular-genetics, staging, prognostic biomarkers, and therapeutic advances in Merkel cell carcinoma. *Mod Pathol.* 2020 Jan;33(1):42-55
80. Jinnah AH, Emory CL, Mai NH, Bergman S, Salih ZT. Hidradenocarcinoma presenting as soft tissue mass: Case report with cytomorphologic description, histologic correlation, and differential diagnosis. *Diagn Cytopathol.* 2016 May;44(5):438-41
81. Asadi-Amoli F, Khoshnevis F, Haeri H, Jahanzad I, Pazira R, Shahsiah R. Comparative examination of androgen receptor reactivity for differential diagnosis of sebaceous carcinoma from squamous cell and basal cell carcinoma. *Am J Clin Pathol.* 2010 Jul;134(1):22-6.
82. Khan SA, Ali AAA, Ferdousi, Riyad M, Mahmud AAH. Malignant Nodular Hidradenoma: Isolated Case Report and Review of Literature *Journal of Bangladesh College of Physicians and Surgeons* 2016 ;34(2):100-103