

SHORT COMMUNICATION

Preliminary study on a stranding case of Mediterranean monk seal *Monachus monachus* (Hermann, 1779) on Antalya coast, Turkey, August 2013

**Erdem Danyer^{1,2*}, Işıl Aytemiz^{1,2}, Elif Özgür Özbek^{2,3},
Arda M. Tonay^{2,4}**

¹Faculty of Veterinary Medicine, Istanbul University, 34320, Avclar, Istanbul, TURKEY

²Turkish Marine Research Foundation (TUDAV), P.O. Box: 10, Beykoz, Istanbul, TURKEY

³Antalya Metropolitan Municipality, Karaalioğlu Parkı içi, 07120, Antalya, TURKEY

⁴Faculty of Fisheries, Istanbul University, Ordu St., No. 200, 34470, Laleli, Istanbul, TURKEY

*Corresponding author: erdemdanyer@gmail.com

Abstract

The Mediterranean monk seal, *Monachus monachus* (Hermann, 1779) is one of the most endangered mammals in the world. On 15 August 2013, an adult female monk seal was found stranded on the coast of Antalya, Turkey. Previously on 6 July 2013, this seal stranded alive in Historic Alanya Shipyard. Gross necropsy was carried out. The seal was emaciated and were nematodes, cestodes and trematodes found in the gastrointestinal tract. Macroscopic findings indicated that hypovolemic shock resulted in death because of internal bleeding which occurred by verminous intoxication or systemic infection. This paper summarizes the preliminary findings of the gross necropsy.

Keywords: Mediterranean monk seal, *Monachus monachus*, digestive track parasite infestation.

Introduction

The Mediterranean monk seal, *Monachus monachus* (Hermann, 1779) is one of the Europe's most endangered marine mammal species and there are about 100

individuals in the Turkish coasts (Güçlüsoy *et al.* 2004). The number of identified seals in the northeastern Mediterranean Sea is given as 42 by Gücü *et al.* (2009). Several factors have caused dramatic population decrease over time: deliberate killing by fishermen due to the damage seals cause to fishing nets when they prey on fish in the nets, as well as coastal urbanization, pollution, overfishing, bacterial, fungal and viral infectious diseases (Öztürk 1992; 2007; Androukaki *et al.* 1999).

Parasites have great importance to the health of their hosts (Raga *et al.* 2002).. Marine mammal parasites contain some of the smallest and most primitive animals known yet they can destroy one of the largest creatures in the world (Dailey 2005). Information on the parasite fauna of the Mediterranean monk seal is very poor (Öztürk 2007). In young pinniped individuals hookworms of genus *Uncinaria* cause hemorrhagic enteritis and anemia. *Diphyllibothrium* cestods and the same genera of the Anisakids are found in pinnipeds and cetaceans. Anisakid nematodes cause gastritis, gastric ulceration, enteritis, diarrhea, dehydration, anemia and sometimes gastric perforation. In pinnipeds intestinal trematodes may occur in massive numbers but they are not a common mortality factor (Dailey 2001).

An adult female Mediterranean monk seal was found stranded ashore on the coast of Gazipaşa Region, Antalya, on the Mediterranean coast of Turkey, on 15 August 2013. The seal was found by local people and brought into a deep freezer. They reported to the Turkish Marine Research Foundation through the Marine Mammal Stranding Network. Gross necropsy was performed, after which the carcass was buried in soil for the preparation of the.

This seal was stranded on 6 July 2013 in Historic Alanya Shipyard and the local people recognized her by the necropsy photos. When they first found her in Alanya, she was exhausted, not active and also she had a superficial injury on her left hind flipper (Figure 1). A local veterinarian applied general antibiotic and anti-parasite therapy at that time and this treatment was performed for a month under the veterinary control. The wound on her left hind flipper was healed, then she was released. (pers. comm., Vet. Med. Kenan Ersoy*).

*Alanya Vet Clinic, Özel Hayat Hastanesi Arkası, A. Ulusoy Sok. 1/F Alanya / Antalya.

Necropsy

The necropsy of the seal was performed on August 16, 2013. It was a very thin, emaciated, adult female with a length of 229 cm from nose to hind flipper end, 220 cm from nose to tail end and the body weight of approximately 100-150 kilograms (Figure 2). The condition was poor according to Barnett and Knight (2008). External examination revealed scratches by rocks on the dorsal part and a healed superficial injury mark on the left hind flipper which helped the identification of the seal easily.



Figure 1. The female Mediterranean monk seal stranded on 6 July 2013 in Alanya (Ö. Yılmaz/ DHA)

On the abdomen, there were three black circular marks approximately 2 cm in diameter. Eyes were normal and mouth was hardly closed. Gums of teeth were massively eroded and gingivitis was observed (Figure 3). Erosion of gums proved that the seal was an old and malnourished individual. Extremities showed normal formation. The seal was observed to have skinny vertebrae so articulations could be easily seen.



Figure 2. The female Mediterranean monk seal stranded in Antalya

Blubber was measured 0.5 cm thick on the thoracic ventromedian line and colour was yellowish. There were bleeding and petechial haemorrhages over the abdomen muscles. Peritoneum was normal. Massive intra-abdominal haemorrhage and lenfadenopathy was observed. Uterus muscle was strong and contracted. Liver was hemorrhagic. Bile seeped from the gall bladder into abdominal cavity. Spleen was enlarged and white spots were seen on it, so the seal was possibly fighting with a systemic infection. Stomach was empty except heavy trematode infestation and a small piece of fishing net. Trematodes also found on the intestinal lumen wall.

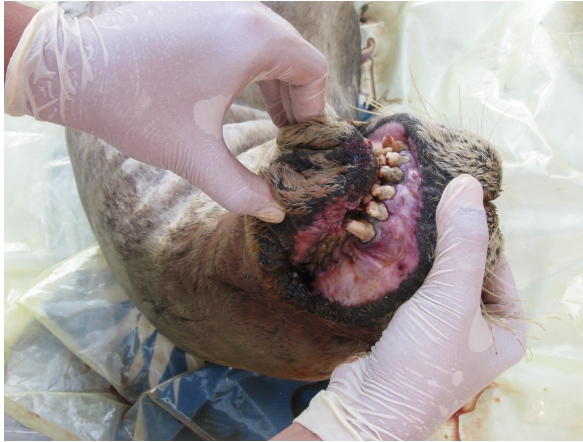

Figure 3. Gingivitis and tooth enamel erosion

Extensive pneumothorax was observed on the right lung that may be caused by an infection. Trachea was clear, esophagus was empty. In the oral cavity there were living cestodes and nematodes (Figure 4). They were collected and kept in the glycerine alcohol solution for further analyses.

Malnutrition probably followed the release, which can be assumed by the teeth condition, gingivitis and parasites in the digestive system. At first sight, massive internal bleeding implied an acute toxicity but the stomach and intestine were almost empty, with little remain of prey fish and other parasites. On the basis of necropsy findings, the cause of death was determined as hypovolemic shock due to internal bleeding which occurred by verminous intoxication or systemic infection. Microscopic pathological study and parasite identifications are carried out and will be published later on.

In April 2013, Danyer *et al.* (2013) reported deliberate killing of an adult male monk seal in the same area. Every single individual is very important for such an endangered population. Conservation measures should be enforced at local and national levels more intensively for this species.

Acknowledgement

We would like to thank Drs. Bayram Öztürk, Ayaka A. Öztürk for their encouragement and support, Antalya Metropolitan Municipality for logistics, Ahmet Mefut and Merve Özkaya for their help in the necropsy, DHA (Doğan News Agency) for the photograph, Turkish Marine Research Foundation for financial support.

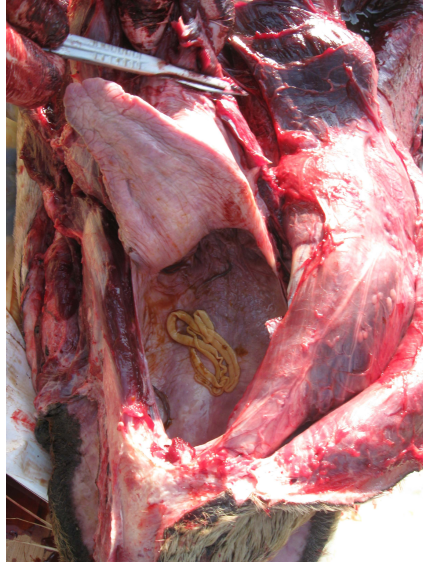


Figure 4. Nematodes and cestodes in the oral cavity

Türkiye Antalya sahilinde, Ağustos 2013'te karaya vuran Akdeniz foku *Monachus monachus* (Hermann, 1779) hakkında ilk bulgular

Özet

Akdeniz ve Ege Sahillerimizde yaşayan Akdeniz Foku *Monachus monachus* (Hermann, 1779) dünyanın nesli kritik olarak tehlikede olan hayvanlarından birisidir. 15 ağustos 2013 tarihinde Antalya kıyılarında erişkin, dişi bir Akdeniz Foku bulundu. Bir gün sonra nekropsisi yapıldı. Fok aşırı derecede kaşektikti. Sindirim sisteminde nematode, sestod ve trematod bulundu. Nekropsi bulgularına dayanılarak ölümün iç kanamaya bağlı hipovolemik şok sonucunda gerçekleştiği düşünülmektedir. İç kanamaya ise verminöz intoksikasyonun yada sistemik bir enfeksiyonun neden olduğu düşünülmektedir. Bu çalışma nekropside elde edilen ilk bulguları paylaşmaktadır.

References

Androukaki, E., Adamantopoulou, S., Dendrinou, P., Tounta, E., Kotomatas, S. (1999) Causes of mortality in the Mediterranean monk seal (*Monachus monachus*) in Greece. *Contributions to the Zoology and Ecology of the Eastern Mediterranean Region* 1: 405-411.

Barnett, J., Knight, A., Stevens, M. (2008) *Marine Mammal Medic Handbook*, 6th Edition, BDMLR, East Sussex, Great Britain, pp. 93.

Dailey, M.D. (2001) Parasitic Diseases, In: CRC Handbook of Marine Mammal Medicine, Second Edition (ed., Dierauf, L. A.), CRC Press, USA, pp. 357-379.

Dailey, M.D. (2005) Parasites of marine mammals. In: Marine Parasitology. (ed. Rohde, K.), Csiro Publishing, Australia, pp.408-414.

Danyer, E., Özbek, E.Ö., Aytemiz, I., Tonay, A.M. (2013) Preliminary report of a stranding case of Mediterranean Monk Seal *Monachus monachus* (Hermann, 1779) on Antalya coast, Turkey, April 2013, *J. Black Sea/Mediterr. Environ.* 19 (2): 278-282.

Gücü, A.C., Sakinan, S., Ok, M. (2009) Occurrence of the critically endangered Mediterranean monk seal, *Monachus monachus*, at Olympos-Beydağları National Park, Turkey (Mammalia: Phocidae). *Zoology in the Middle East* 46 (1): 3-8.

Güçlüsoy, H., Kiraç, C.O., Veryeri, N.O., Savas, Y. (2004) Status of the Mediterranean monk seal, *Monachus monachus* (Hermann, 1779) in the coastal waters of Turkey. *EU Journal of Fisheries & Aquatic Sciences* 21 (3-4): 201-210.

Raga, J.A., Aznar, F.J., Balbuena, J.A., Fernandez, M. (2002) Parasites In: Encyclopedia of Marine Mammals (eds., Perrin, W.F., Wursig, B., Thewissen, J.G.M.), Academic Press, San Diego, USA, pp. 867-875.

Öztürk, B. (1992) Mediterranean Monk Seal. Anahtar Kitaplar, İstanbul, 215 pp (in Turkish).

Öztürk, B. (2007) Mediterranean Monk Seal and Its Protection. Yalıkavak Çevre ve Fok Araştırmaları Derneği Yayın No:1, Muğla Turkey, 132 pp (in Turkish).

Received: 01.09.2013

Accepted: 04.10.2013