

Myxoid degeneration of the tendon as a cause of pediatric trigger finger

Pediatric tetik parmak nedeni olarak, tendonun miksoid dejenerasyonu

Mehmet Erođlu¹, Mehmet Serhan Er², Recep Abdullah Erten¹, Hasan Metineren³, Betül Demirciler Yavař⁴

ABSTRACT

Pediatric trigger finger is rarely seen in clinical practice and when seen is the trigger thumb mostly. A myxoid degeneration of the tendon in the nodule has been detected at superficial flexor tendon of third finger on left side of a 12 year old child who underwent surgery with a diagnosis of trigger finger. The patient is free of pain and triggering after the excision of this degeneration. The aim of this report is to remind that rare pathologies as tendon tumors (or myxoid degeneration, as in our case) of the tendon may be the cause of pediatric trigger finger with most of them requiring surgery. *J Clin Exp Invest* 2014; 5 (1): 106-107

Key words: Myxoid degeneration; pediatric; trigger finger.

INTRODUCTION

Pediatric trigger finger (TF) is a rare condition, which is ten times less common than pediatric trigger thumb [1,2]. The cause is unknown but anatomic variations are claimed to be responsible and although those exist from birth, the entity occurs in the following years [3]. If there is no anatomic pre-disposing factor, rarer conditions that increase the contents of the sheath can cause pediatric TF. These include inflammatory synovitis of rheumatoid arthritis, post traumatic calcific tendonitis or deposition of mucopolysaccharide in Hurler's syndrome, etc. [1,2]. We report an unusual cause of pediatric TF myxoid degeneration of the tendon.

CASE

A twelve year-old male patient with triggering of the third finger on left side for one year admitted to our outpatients clinic. He had no accompanying dis-

ÖZET

Pediatric tetik parmak klinik uygulamada nadiren görülür ve görüldüğünde çoğunlukla tetik başparmak olarak ortaya çıkar. Tetik parmak tanısıyla ameliyat edilen 12 yaşındaki bir çocuğun sol el üçüncü parmağının yüzeysel fleksör tendonundaki nodül içerisinde miksoid dejenerasyon tespit edildi. Bu dejenerasyon cerrahi olarak çıkartıldıktan sonra hastanın ağrısının ve takılmasının geçtiği görüldü. Bu olguyu sunma amacımız, vakamızda olduğu gibi tendonun miksoid dejenerasyonu ve tümörler gibi nadir görülen patolojilerin, çoğu cerrahi gerektiren, çocuk tetik parmak nedeni olabileceğini hatırlatmaktır.

Anahtar kelimeler: Miksoid dejenerasyon, pediatrik, tetik parmak

eases or history of trauma. The triggering occurred especially in the morning and decreased during the day time. It caused pain and relieved spontaneously.

In the examination, the finger was locked in flexion and while extending there were two clicks. A painful nodule was palpated on the volar aspect of third metacarpophalangeal joint.

In the operation, the A1 pulley seemed normal, after dividing it decussating of superficial flexor tendon proximal to A1 pulley and a wider ulnar slip were seen. The ulnar slip was three times wider than the radial one (Figure 1). After a longitudinal incision a yellowish mass was seen in the deeper part of the tendon and it was excised (Figure 1). There were no triggering after this point and the operation ended.

Pathological examination of the mass revealed myxoid degeneration of the tendon which is unusual as a cause pediatric TF (Figure 2). The patient is free of pain and triggering after the operation.

¹ Department of Orthopedics and Traumatology, University of Afyon Kocatepe, School of Medicine, Afyonkarahisar, Turkey

² Department of Orthopedics and Traumatology, University of Akdeniz, School of Medicine, Antalya, Turkey

³ Department of Orthopedics and Traumatology, University of Dumlupınar, School of Medicine, Kütahya, Turkey

⁴ Department of Pathology, University of Afyon Kocatepe, School of Medicine, Afyonkarahisar, Turkey

Correspondence: Mehmet Serhan Er,

Kocatepe University, School of Medicine, Dept. Orthopedics&Traumatology, Afyon, Turkey Email: mserhan2005@hotmail.com

Received: 30.09.2013, Accepted: 22.10.2013

Copyright © JCEI / Journal of Clinical and Experimental Investigations 2014, All rights reserved

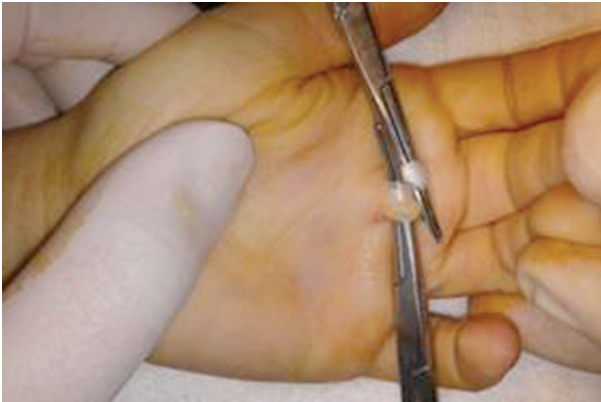

Figure 1. Radial part of FDS tendon is in normal size but the ulnar part of the tendon is enlarged and contains a lipid mass which later shown to be myxoid degeneration of the tendon

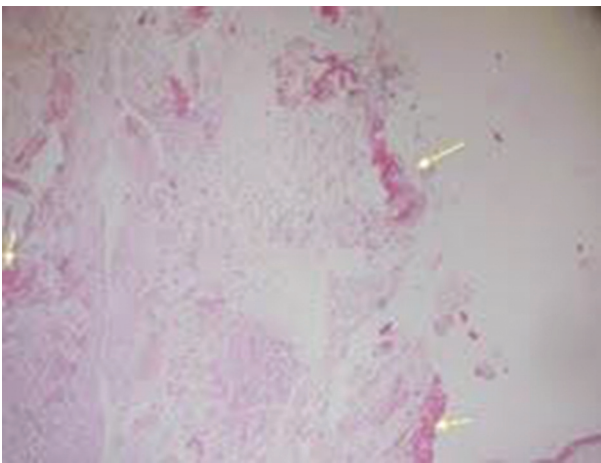


Figure 2. In histologic examination, fibrin deposition (arrows) in loose edematous connective tissue, indicative of myxoid degeneration is seen.(H&E x40)

DISCUSSION

Trigger thumbs constitute 90% of pediatric trigger digits [2]. It is a rare condition which usually occurs in children aged <8 years [4] and affects less than 0.05% of children [2]. Unlike pediatric trigger thumb it usually does not resolve with time and requires surgery. It is still controversial regarding the congenital versus acquired nature of pediatric trigger thumbs and the rate of spontaneous resolution [4].

Many factors are listed as the cause; anatomical abnormalities, thickened tendons and tendon sheaths, trauma (partial laceration of FDS tendon), tumors and lesions within the flexor apparatus, viral infections, some metabolic disorders such as type 1 diabetes mellitus and mucopolysaccharidosis, inflammatory diseases such as juvenile rheumatoid arthritis [1,3,4]. Reported abnormalities included a more proximal than normal decussation of the FDS, a slip of FDS that inserted into the FDP tendon, nodules in the tendon, and a stenotic A-3 pulley [1,2].

We present a case with an unexpected cause; myxoid degeneration of the tendon. We believe that the degeneration of the tendon is a result of proximal decussation of flexor digitorum superficialis tendon. Although some authors recommended conservative treatment and reported spontaneous recovery [2,5], unlike the adult TF, surgical treatment of pediatric TF may need a more extensile approach through a Bruner incision [1,6]. In our case there was not any need for extensile approach as triggering relieved after excision of the mass and pulley release.

Despite pediatric TF is about one tenth as common as trigger thumb, it needs a thorough understanding and assessment as it may have a wide range of etiology with most of them requiring surgery.

REFERENCES

- Schaverien MV, Godwin Y. Paediatric trigger finger: Literature review and management algorithm. *J Plast Reconstr Aesthet Surg* 2011 May;64:623-631.
- Ryzewicz M, Wolf JM. Trigger digits: principles, management, and complications. *J Hand Surg Am* 2006 Jan;31:135-146.
- Chia J, Pho RW, Sinniah R. "Congenital" trigger thumb caused by intratendinous granulation tissue. *J Hand Surg Br* 1996 Oct;21:612-613.
- Pargali N, Habibzadeh F. Bilateral trigger finger in a 5-year-old child: case report. *J Plast Reconstr Aesthet Surg* 2011 Nov;64:283-284.
- Moon WN, Suh SW, Kim IC. Trigger digits in children. *J Hand Surg Br* 2001 Feb;26:11-12.
- Hamada Y, Tonogai I, Hibino N, Henmi T. Etiology and treatment of pediatric trigger finger: possible application of partial V-shaped resection of the central part of flexor digitorum superficialis through our case presentation. *Hand (N Y)*. 2011;6:115-116.