

Local steroid injection accompanied by ultrasonographic imaging in the treatment of facet syndrome

Faset sendromunun tedavisinde ultrasonografik görüntüleme eşliğinde lokal steroid enjeksiyonu uygulaması

Murat Karkucak¹, İpek Can¹, Erhan Çapkın¹, Avni Mustafa Önder², Emre Baki², İbrahim Batmaz³

ABSTRACT

Ultrasonography (USG) is becoming increasingly important in visualizing the musculoskeletal system. It is used as a diagnostic guide and in local injection procedures but is less frequently applied in visualizing deep joints and injections. The purpose of this study is to describe the results of USG-guided facet joint injection in a 19-year-old male patient with low back pain for the preceding year and a preliminary diagnosis of facet syndrome, together with a review of the literature. *J Clin Exp Invest* 2014; 5 (1): 125-127

Key words; Facet syndrome, Ultrasonography, Local injection

INTRODUCTION

Ultrasonography (USG) is becoming increasingly used in the musculoskeletal system. The main advantages of USG are that it is non-invasive, economical, provides dynamic imaging, is easily routinely performed and facilitates local procedures to the musculoskeletal system [1]. It is used, in the light of American College of Rheumatology (ACR) recommendations, both diagnostically and as a guide in several joints [2]. The most commonly involved joints are the shoulder, knee and hand [3]. The use of USG in the lumbar region is uncommon. Image quality in injections performed with USG to deep joints such as the hip, lumbar region and sacroiliac joints may not always achieve the desired quality. Chronic lower backache is the most important cause of disability below the age of 45 [4-5]. One of the main causes of backache in the young is facet syndrome. This generally develops as a result of inflammation in the joint capsule or increased

ÖZET

Ultrasonografi (US) muskuloskeletal sistem görüntülemesinde gittikçe önemli bir yer tutmaktadır. Lokal enjeksiyon uygulamalarında tanısal rehber olarak kullanılmakla birlikte, derin eklemlerin görüntülenmesi ve enjeksiyonunda daha az sıklıkta kullanılmaktadır. Bu çalışmanın amacı faset sendromu tanısı ile bir yıldır devam eden bel ağrısı olan 19 yaşında erkek hastada, US eşliğinde yapılan faset eklem enjeksiyonu sonucunu literatür derlemesi ile birlikte sunmaktır.

Anahtar kelimeler: Faset sendromu, Ultrasonografi, Lokal enjeksiyon

joint fluid following repetitive microtrauma (such as obesity and extended periods in a sitting posture) or high-energy trauma [6-7]. Local steroid injections are widely used in the treatment of facet syndrome. This procedure is generally performed accompanied by fluoroscopy and computerized tomography.

One contemporary study compared fluoroscopy and USG as guides in steroid injection to the facet joint, and reported similar outcomes from both [9]. USG represents a good alternative in facet joint injections in suitable patients since it involves no radiation risk. The purpose of this report is to describe the results of USG-guided facet joint injection in a young patient with backache for the preceding year.

CASE

A 19-year-old male patient presented to our clinic with backache. He described pain persisting for approximately one year in the lower back and left hip but not extending below the knee. The pain in-

¹ Karadeniz Technical University, Medical School, Dept. of Physical Medicine and Rehabilitation, Trabzon, Turkey

² Karadeniz Technical University, Medical School, Dept. Orthopedics and Traumatology Trabzon, Turkey

³ Dicle University, Medical School, Dept. of Physical Medicine and Rehabilitation, Diyarbakır, Turkey

Correspondence: İpek Can,

KTU, Medical School, Dept. Physical Medicine and Rehabilitation, Trabzon, Turkey Email: dripekcan86@gmail.com

Received: 17.12.2013, Accepted: 09.01.2014

Copyright © JCEI / Journal of Clinical and Experimental Investigations 2014, All rights reserved

creased when he lay on his back at night and when working during the day. Painkillers produced a marked improvement. The patient had experienced marked restriction in sitting activity due to this pain. At physical examination body mass index was 24 kg/cm². Sensitivity to pressure was present in facet joints L 3-4 and L 4-5. Lower back movements were unimpeded, and more marked pain was present at end of extension. No abnormality was encountered at musculoskeletal system examination or in routine laboratory parameters with associated the etiology of low back pain.

Preliminary diagnosis of facet syndrome was made on the basis of increasing pain with facet joint pressure at extension and straight leg raise test negativity. The patient was started on nonsteroidal anti-inflammatory drug (NSAID) therapy. The patient had a visual analog scale (VAS) of 8 and a modified Oswestry scale of 68. Symptoms did not improve, and local steroid injection accompanied by USG to the facet joint at levels L 3-4 and L4-5 was applied twice at a 3-week interval. During the procedure, with the patient in the prone position, a panoramic image was obtained of the L2-S1 spinous processes. Once the relevant lumbar spinous process had been identified, the probe was turned toward the lateral aspect and the facet joint visualized (Figure 1). An approximately 10-cc combination of 1-2% lidocaine hydrochloride and betamethasone was divided between the two regions. During the period, the patient was not taking any medication and physical therapy programs. Six weeks after the injections a 4-unit decrease in VAS and a 12-point decrease in modified Oswestry score were registered. The patient was given appropriate advice and placed under long-term monitoring.

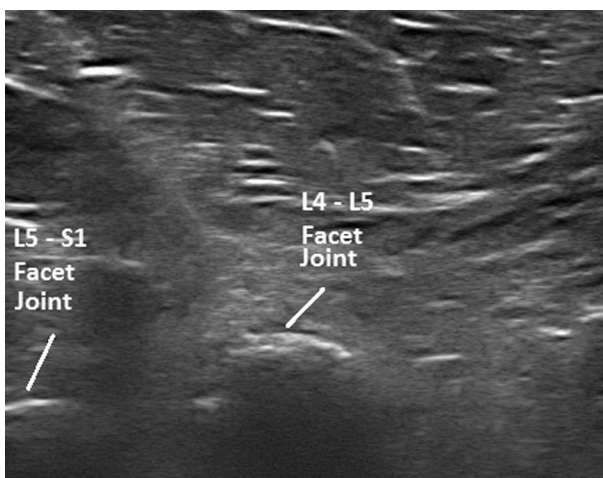


Figure 1. Lateral aspect of facet joint

DISCUSSION

Local injections are a good alternative in medical treatment for soft tissue rheumatism. That effectiveness is enhanced if these are accompanied by imaging. USG is a very good guide for local procedures [3]. As described above, we observed a marked improvement in our patient's symptoms, which had persisted for one year, after two injections to the facet joint accompanied by USG.

USG has become an important and popular imaging technique increasingly employed in the musculoskeletal system. USG is used both as an extension of physical examination in patient assessment and as a guide in invasive procedures. USG enables joint injections and aspiration biopsies to be applied to the correct location. The main advantages of USG are that it does not involve exposure to radiation during the procedure and is economical and repeatable, and that images can be obtained in many planes [1]. Disadvantages include the need for experience, problems with the area of application and low image quality in soft tissues. There may also be difficulties associated with the patient's physical characteristics in imaging of deep structures such as the hip joint and the lumbar and sacroiliac region. Better images may be obtained with a linear probe compared to a concave probe [10].

The prevalence of lower backache is rising together with obesity and a sedentary life style. Sedentary activity together with long-term inappropriate posture leads to soft tissue pathologies in the lower back region. One study reported that chronic backache is the main cause of disability below the age of 45 [5]. Facet syndrome constitutes 5%-15% of the chronic lower backache population, depending on the diagnostic criteria selected [8]. This can rise to 80% in chronic lower back pains [11]. Facet syndrome is characterized by inflammation in the joint capsule or increased joint fluid following repetitive microtrauma (such as obesity and extended periods in a sitting posture) or high-energy trauma [6-7]. Anamnesis and physical examination are mainly used to diagnose facet syndrome, which is particularly characterized by low back pain. Pseudoradicular pain can spread to the hip, groin and posterior part of the thigh. Sensitivity may be present on palpation of the facet joints. Increased pain with lower back extension is characteristic [5]. Facet syndrome treatment consists of conservative and interventional approaches. Interventional treatment options include injections and radiofrequency therapy [8]. Facet injections are applied for different purposes and in different techniques such as diag-

nostic blocks, intra-articular steroid application, medial branch block and block before radiofrequency [12]. One study that compared radiofrequency and injection recommended injection as the first option, with radiofrequency use if the effect obtained is inadequate or if symptoms recur [13]. This technique is often applied with fluoroscopy and CT guidance.

Ha et al. reported the 6-month results of 105 patients receiving injections to the facet joint. That retrospective study emphasized that there is no risk of radiation in facet joint block with USG, and that it can be preferred as a minimally invasive and simple procedure [14]. Galiano et al. also recommended USG guidance in facet joint injection as easy to perform and involving minimal risk [1].

On one contemporary study, Dong Hwan et al. randomly divided 57 facet syndrome patients into two groups. One group was given facet joint injection with fluoroscopy (n=25) and the other group with USG (n=32). VAS, global assessment and modified Oswestry disability index were used in patient evaluation. A significant improvement in all parameters was determined and the first week and the first and third months. However, no statistically significant difference was determined between the two techniques [9]. Mean BMI in the patients in the USG group in this study was 23.8 kg/cm². This has a positive effect on USG imaging of the facet joint. The fact that our patient was young and had a low BMI also assisted better imaging of the facet joints. Improvement in terms of both pain and function in the first month following the two procedures suggests that this injection technique with USG is effective.

USG is becoming increasingly used in local injections. In terms of increasing awareness of these procedures, identifying suitable patients and determining interventional procedures, well designed prospective studies with larger case numbers and investigating long-term effects are now needed.

REFERENCES

- Galiano K, Obwegeser AA, Walch C, et al. Ultrasound-guided versus computed tomography-controlled facet joint injections in the lumbar spine: a prospective randomized clinical trial. *Reg Anesth Pain Med* 2007;32:317-322.
- Mcalindon T, Kissin E, Nazarian L, et al. American College of Rheumatology Report on Reasonable Use of Musculoskeletal Ultrasonography in Rheumatology Clinical Practice. *Arthritis Care & Res* 2012;64:1625-1640.
- Ucuncu F, Capkin E, Karkucak M, et al. A comparison of the effectiveness of landmark-guided injections and ultrasonography guided injections for shoulder pain. *Clin J Pain* 2009;25:786-789.
- Atkinson JH, Slater MA: Behavioral medicine approaches to chronic low back pain. In Rotman RH, Simeone FA (Eds.) *The Spine*. Philadelphia, 1961-81,1992.
- Beresford ZM, Kendall RW, Willick SE. Lumbar facet syndromes. *Curr. Sports Med. Rep.* 2010;9:50-56.
- Song KJ, Lee KB. Bilateral facet dislocation on L4-L5 without neurologic deficit. *J Spinal Disord Tech* 2005;18:462-464.
- Yang KH, King AI. Mechanism of facet load transmission as a hypothesis for low-back pain. *Spine* 1984;9:557-565.
- Kleef M, Vanelderden P, Cohen PH, et al. Pain originating from the lumbar facet joints. *Pain Practice* 2010;10:459-469.
- Yun DH, Kim HS, Yoo DS, et al. Efficacy of ultrasonography-guided injections in patients with facet syndrome of the low lumbar spine. *Ann Rehabil Med* 2012;36:66-71.
- Chen CPC, Lew HL, Tsai WC, et al. Ultrasound-guided injection techniques for the low back and hip joint. *Am J Phys Med Rehabil* 2011;90:860-867.
- Shealy CN. Facet denervation in the management of back and sciatic pain. *Clin Orthop Relat Res* 1976;115:157-164.
- Cohen SP, Huang JHY, Brummet C. Facet joint pain advances in patient selection and treatment. *Nature Reviews Rheumatology* 2013;9:101-116.
- Civelek E, Cansever T, Kabataş S. Comparison of effectiveness of facet joint injection and radiofrequency denervation in chronic low back pain. *Turk Neurosurg* 2012;22: 200-206.
- Ha DH, Shim DM, Kim TK, et al. Comparison of ultrasonography and fluoroscopy-guided facet joint block in the lumbar spine. *Asian Spine J* 2010;4:15-22.