

Orthopedic approach to foreign body stings

Yabancı cisim batmalarına ortopedik yaklaşım

Celil Alemdar, Abdullah Demirtaş, Mehmet Gem, Emin Özkul, İbrahim Azboy, Mehmet Bulut, Cahit Ancar

ABSTRACT

Objective: Although foreign body injuries are quite common, there are an insufficient number of publications on this matter. The aim of this study was to evaluate patients with foreign body injuries, and to determine the treatment algorithm.

Methods: A total of 97 patients were evaluated, including 53 men and 44 women. Ninety-one patients underwent surgery, and six patients were treated conservatively. Surgery was performed in the operating room in all cases. To ensure that the foreign body was removed, fluoroscopic control was completed during and after the procedure. Antibiotics were administered routinely to all patients, and the need for tetanus prophylaxis was evaluated in each patient.

Results: The mean age of the patients was 16.5 (range: 2-58) years. Regarding the type of foreign body, there was injury due to: a needle in 65 patients, glass in 14, wood in 7, iron spit in 1, iron bar in 1, pieces of metal in 3, and other foreign bodies were found in 6 patients. There were 25 injuries of the upper extremity, and 72 of the lower extremity. The time of admission to the hospital after the injury ranged from 1 day to 3 years. Obvious signs of infection were detected in 10 patients. There were no complications after the follow-up of patients who were treated conservatively.

Conclusion: Foreign body penetration is a severe injury that may cause significant problems when ignored. Treatment algorithms prepared according to the type of injury would guide the most appropriate approach to these injuries. *J Clin Exp Invest* 2013; 4 (4): 443-448

Key words: Foreign body, extremity, localization, injury

INTRODUCTION

Foreign body injuries are not uncommon. Foreign body penetration may occur in almost any part of the body. The major routes of foreign body exposure are through the skin by penetration, the gastrointestinal tract by ingestion, and the lungs by aspiration and abuse. The degrees of injury may vary.

ÖZET

Amaç: Toplumda çok sık görülmesine rağmen, ortopedik sahayı ilgilendiren yabancı cisim batmaları literatürde yeteri kadar yer bulmamıştır. Çalışmamızın amacı yabancı cisim batması nedeni ile takip ettiğimiz hastaları değerlendirmek ve tedavi yaklaşımı ortaya koymaktır.

Yöntemler: 53 erkek, 44 kadın olmak üzere toplam 97 hasta değerlendirildi. Hastaların 91'ine cerrahi, 6'sına konservatif tedavi uygulandı. Cerrahi girişimlerin tamamı ameliyathane şartlarında gerçekleştirildi. Operasyon sırasında ve sonrasında skopi kontrolü yapılarak yabancı cisim ya da cisimlerin çıkarıldığından emin olundu. Rutin olarak antibiyotik uygulanan hastalar tetanoz profilaksisi açısından da değerlendirildi.

Bulgular: Hastaların ortalama yaşı 16,5 (dağılım; 2-58) YIL idi. Hastaların 65'inde iğne, 14'ünde cam, 7'sinde tahta, 1'inde şiş, 1'inde demir çubuk, 3'ünde metal parçası ve 6'sında diğer yabancı cisimler tespit edildi. Yaralanmaların 25'i üst ekstremitede, 72'si ise alt ekstremitede idi. Yaralanma sonrası hastaneye başvuru süresi 1 gün-3 yıl arasında değişmekteydi. Toplam 10 hastada belirgin enfeksiyon bulguları tespit edildi. Konservatif kalınan hastaların sonraki takiplerinde komplikasyon görülmedi.

Sonuç: Yabancı cisim batmaları, dikkatli değerlendirilmediğinde önemli sorunlara yol açabilen ciddi yaralanmalardır. Yaralanmanın tipine göre hazırlanan tedavi şemaları en uygun yaklaşımı belirlemede yol gösterici olacaktır.

Anahtar kelimeler: Yabancı cisim, ekstremitte, lokalizasyon, yaralanma

For this reason, while a number of patients exposed to foreign body injury seek medical care, others remove the foreign body themselves.

Most of the patients with foreign body injuries are first evaluated in the emergency department, and interventions are administered by the emergency department physician. Yet a number of patients

are admitted to orthopedic outpatient clinics. In some cases, a foreign body is detected in patients with a variety of complaints, because of clinical investigations [1].

Although there are many studies in the literature with regard to the treatment of foreign body injuries in other relevant areas of specialization, there are very few studies related to orthopedic cases of foreign body injuries, and most of these studies are case reports [2-4]. In the current study, the objects disrupting the integrity of the skin and entering the body resulting in injury in the field of orthopedic surgery were assessed. The intent was to create a treatment algorithm by evaluating the treatment results.

METHODS

Ninety-seven patients with a foreign body injury admitted to the emergency room and outpatient clinics were evaluated retrospectively. Foreign body injuries accompanying severe soft tissue injury due to high-energy trauma were not included in the study. Age, gender, and mechanism of trauma were noted. Physical examination and radiological evaluation were done.

Physical examinations were done including the depth and structural properties of foreign body. In addition, the possibility of contamination, accompanying infection or abscess were evaluated. An X-ray study was performed after the physical examination in all patients. Direct radiographies were taken to assess the localization, characteristics, and depth of injury. Ultrasonography, computed tomography and magnetic resonance imaging were done when the foreign body was

Informed consent was taken before surgical intervention. In all procedures, fluoroscopic equipment was available. Total excision of radio-opaque foreign bodies was confirmed by fluoroscopy. After the removal of the foreign body, the wound was irrigated and closed. The wounds, which contaminated or accompanied by an abscess were debrided and a drain was placed for 24-48 hours. An X-ray was taken after the operation.

Prophylactic antibiotics were started in all patients. Depending on the degree of contamination of the wound, single, double, or triple antibiotic therapy was started. In cases with single antibiotic therapy, mainly broad-spectrum antibiotics effective on Gram (+) bacteria (mostly first-generation cephalosporins) were given. In cases with contaminated wounds, antibiotics with a Gram (-) activity from the group of aminoglycoside antibiotics were added. In

the case of triple therapy, nidazol class antibiotics that are effective in treating anaerobic bacteria were added to the regimen. In addition, tetanus prophylaxis was administered in all cases seen during the acute phase after injury (Table 1) [5].

Table 1. Tetanus prophylaxis

Unknown or <3 doses	Yes	No	Yes	Yes
>3 doses	No *	No	No **	No

*Administered more than 10 years after the last dose, ** Administered more than 5 years after the last dose

TT: Tetanus Toxoid, TIG: Tetanus immunoglobulin

RESULTS

The mean age of the patients was 16.5 years (range, 2-58). There were 25 injuries of the upper extremity, and 72 of the lower extremity (Figure 1, 2). The majority of foreign bodies were needles in 65(67%) patients (Table 2). Time to admission to the hospital after the injury was 7 days (range, 1 day - 3 years). Obvious signs of infection were detected in 10 patients. Ninety-one patients underwent surgery, and 6 patients were treated conservatively (Table 3). In one patient treated by surgery, the foreign body was left in situ, abscess drainage and debridement were performed, and the procedure was terminated.

Table 2. The distribution of foreign bodies

	n (%)
Needle	65 (67)
Glass	14 (14.4)
Wood	7 (7.2)
Iron spit	1 (1)
Iron bar	1 (1)
Pieces of metal	3 (3)
Other	6 (6.1)

The patients who underwent conservative treatment were followed-up on. In patients with needle or glass injuries, removal was not considered an option when they were small and completely stuck in the bone. In a patient complaining of a needle injury in the knee joint, the needle was found to be in the joint (Figure 3). In the follow-up, the patient did not have any complaints.

Irrigation only was performed in 86 of the patients who underwent surgery. Debridement was also performed in 5 patients. A total of 10 patients

developed an infection. Of these patients the rate of infection was less in pin punctures (4 patients, 6.25%) and glass punctures (1 patient-, 7.14%) compared to wood punctures (2 patients, 28.5%), and unknown foreign bodies (3 patients, 50%). First generation cephalosporins were administered in all infected patients after obtaining cultures. According to the cultures antibiotherapy was designed.

Since the foreign body was palpated in 6 of 13 patients in whom the foreign body could not be seen on direct roentgenograms no further studies were performed. The foreign body was detected with ultrasonography in 2 patients, tomography in 2 patients, and MRI in 1 patient.

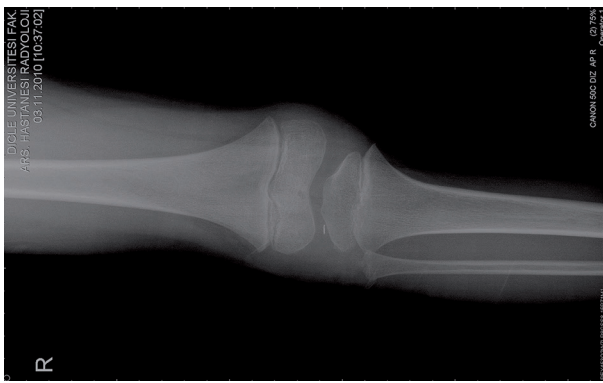


Figure 1. A piece of glass protruding from the foot, pierced while playing soccer

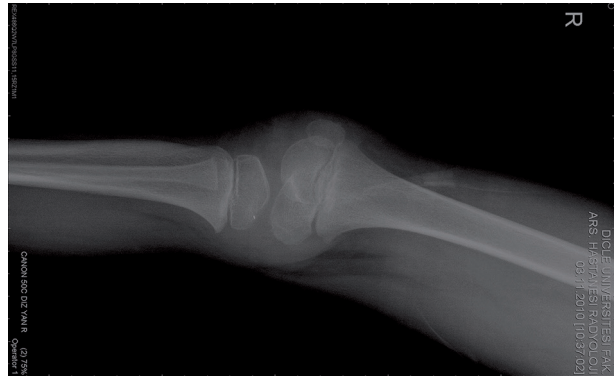


Figure 2. Metal rod in the thigh

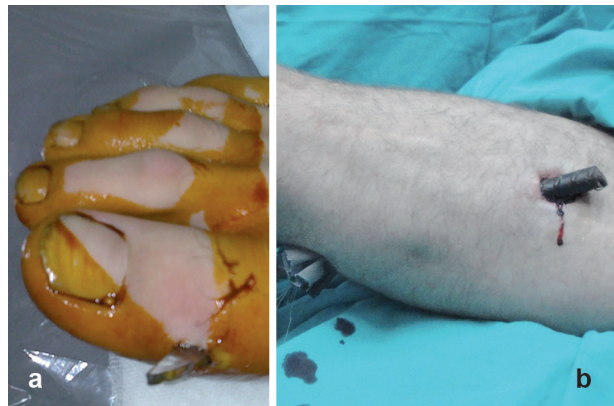


Figure 3a, b. A Foreign body located postero-laterally

Table 3. Localization of foreign bodies and type of treatment

Localization	Number of foreign bodies n (%)	Surgical treatment	Conservative treatment
Hand	14 (14.4)	13	1
Forearm	5 (5.1)	3	2
Elbow	4 (4.1)	4	-
Arm	2 (2)	2	-
Foot	42 (43.2)	40	2
Cruris	5 (5.1)	5	-
Knee and surrounding	16 (16.4)	15	1
Thigh	3 (3)	3	-
Hip	3 (3)	3	-

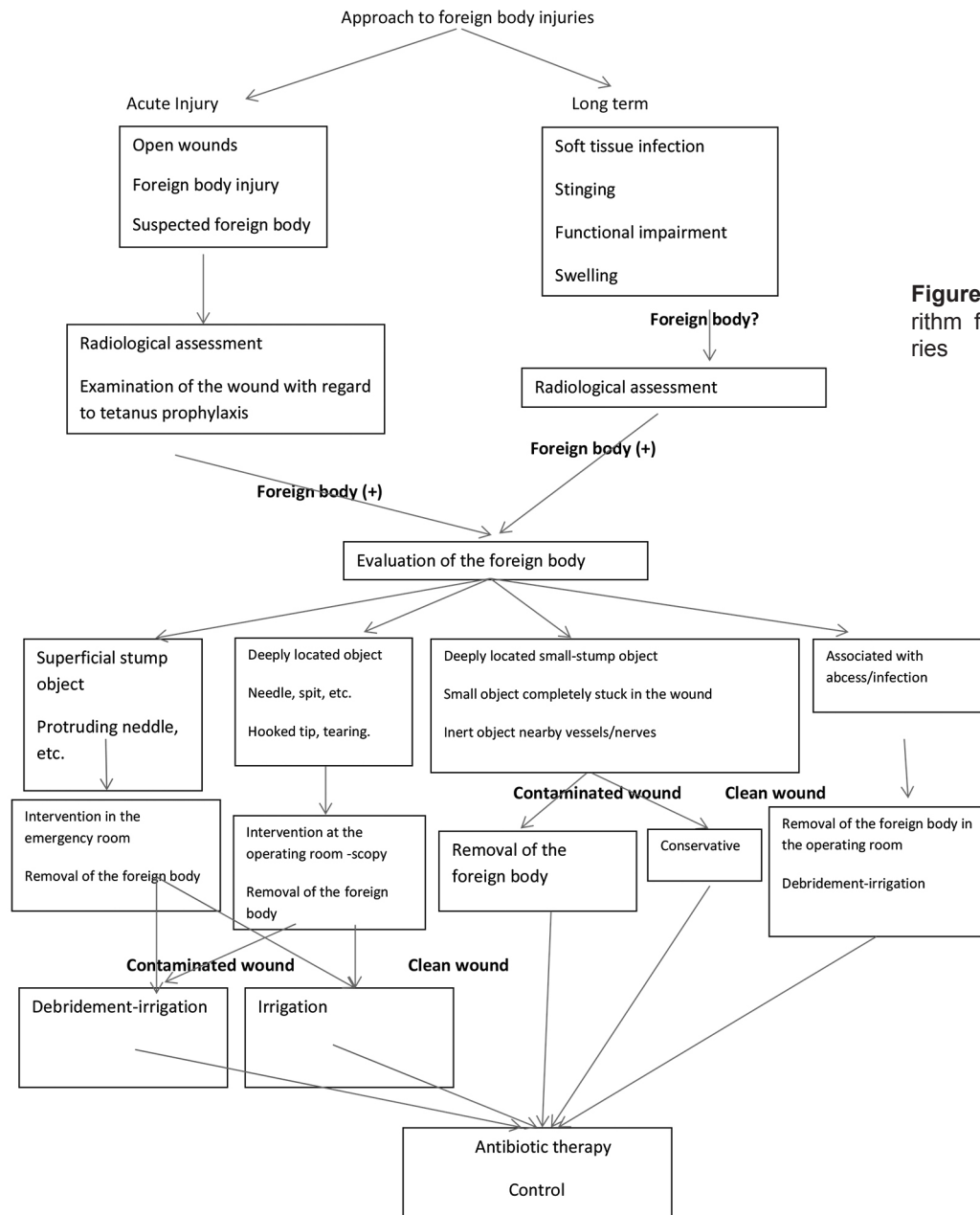


Figure 4. Treatment algorithm for foreign body injuries

DISCUSSION

Foreign body penetration injuries are common. However, knowledge in the literature is limited about the systematic approach to those injuries. The development of standard and evidence based treatment principles, as in all diseases, will provide the proper and efficient approach in foreign body penetration injuries. The treatment methods that were used in this study and the results of these approaches were evaluated in light of literature.

Radiological evaluation should absolutely be performed in all patients with foreign body penetra-

tions after careful physical examination [6,7] and direct radiographies should be ordered as at least in two directions. Because radiolucent objects could not be seen on direct radiographies, CT and MRI might be used when further evaluation is required [8]. The characteristics and depth and the number of the pieces of the foreign body and its distance from a vascular or neural trajectory can be identified by radiological evaluation. This information will be helpful in treatment planning. An obvious sign of injury and history of foreign body penetration to aid in diagnoses are present in most of the patients upon admission. In some cases, the presentation may

present with various complaints and foreign bodies may be incidentally detected during the examination.

Foreign body injuries without early diagnosis may result in a variety of clinical conditions. Immune reactions against the foreign body might result in signs mimicking soft tissue and bone infections and tumors, and the etiology of the clinical picture may be realized later to be a foreign body [9]. Maempel et al [2] reported that a piece of wood that stung intramuscularly 30 months ago in a male patient with the age of 29 years behaved like a tumor with a large granulation tissue surrounding it.

Patients who did not notice that the foreign body entered through their skin might present to health facilities with other complaints. A positive history of a foreign body could not be obtained in some cases when questioned retrospectively. Melek et al [3] reported that they identified a sewing needle in the roentgenogram of a 5- year old girl who presented with septic arthritis; information could not be obtained from either the girl or her relatives supporting the history of foreign body injury. Foreign bodies were also found in the purulent drainage in 2 patients in whom we performed abscess drainage.

The consistency of the information about the history given by the patient or his/her relatives with the findings of clinical and radiological examinations should be considered. Families can give misleading information, especially in pediatric patients. Lee et al [4] have reported a case of a 4- year old boy with a penetrating hand injury of the hand with a pen, who had been subjected to violence by his mother.

In patients with a foreign body injury, the primary decision should be whether the removal of the foreign body is necessary. It should then be decided where the intervention should take place: either in the emergency room, or at the operating room under sterile conditions and under fluoroscopic control. A planned procedure is the key for successful treatment [10]. Superficial located, palpable or protruding foreign bodies that can be removed without further damage can be removed in the emergency room. Local anesthesia is generally adequate for such injuries. Hocaoglu et al [11], in their study of 86 patients with hand injuries due to foreign body reported that they performed the surgical operations of the patients under local anesthesia in 94.2% of the patients. However, it should be kept in mind that the vastly palpable objects may 'disappear' after the injection of the local anesthetics. In such cases, the foreign body must be significantly palpable and it should be assured that the object will remain fixed

in place. In addition, the smallest possible amount of local anesthetic should be applied.

The foreign bodies, such as needles, which can move within the tissue, should be removed at the operating room, even if palpable. During surgery, movements of the dissecting scissors will cause propulsion of the foreign bodies, resulting in the advancement of these objects to deeper tissues. Thus, the surgeon can lose his/her orientation of the object. In such a case, the object is usually quite difficult to find, since the object may be very far from the localization visible in the x-ray, or may have progressed far from the estimated location. The patient should then be taken to the operating room, and an unnecessarily large incision should be made for a relatively small foreign body that could have been removed through a smaller incision. For this reason, foreign body injuries with a needle should always be treated at the operating room with fluoroscopic guidance. Objects that could damage the surrounding structures should not be withdrawn, but be removed by careful surgical dissection. Otherwise, serious damage may occur during removal. If the object is in proximity to large vessels, it may be safer to plan the surgery with a cardiovascular surgeon. We developed a treatment algorithm according to the type of injury. We consider that it was beneficial to define the foreign body and the most appropriate approach to these injuries (Figure 4).

The foreign body should be extracted through the closest point to the surface and with minimal dissection possible. Extraction of radiopaque foreign bodies with the aid of fluoroscopy would prevent unnecessary tissue damage and decrease the rate of infection. Irrigation should always be done after extraction. In the case of contaminated wounds with irregular borders, the wound should be debrided [12].

When considering that incidentally discovered metallic substances during daily practice remain in place for years without any discomfort to the patient, metallic foreign bodies located deep in the skin (under the fascia) and/or attached to the bone with no effect on the comfort or functions of the patient may not require excision. Efforts to remove deeply located foreign bodies, in particular, are likely to result in damage of the vascular and neural structures. However, the foreign bodies in the joints can cause problems, such as septic arthritis and synovitis [13]. Contaminated, massive, intra-articular foreign bodies, which may potentially cause functional impairment, should be removed. It is essential to make adequate preoperative planning, and remove the body with the minimal iatrogenic damage.

Inadequate initial evaluation and absence of radiological examinations are the two most frequently encountered errors in practice. In these circumstances, the open wound is sutured in most cases; however, the patient's complaints continue related to the type of the remaining foreign body [14]. The foreign body, which could not be detected, may lead to problems such as infection, chronic pain, stinging, swelling, loss of function, and contractures [15].

Wounds with impaired skin integrity are at risk for infections [16]. The risks of infection of the clean-contaminated and dirty wounds are higher than 5% [17]. Most of the wounds associated with trauma are clean-contaminated or contaminated wounds. According to the European Surgical Infection Committee, antibiotics should be used in cases where the risk of infection is more than 5% [18]. We also believe that antibiotic prophylaxis should be performed in such cases according to the degree of contamination. Haverstock [19] emphasized the importance of infection in perforating wounds of the foot, and in this regard, he reported that cleansing and antibiotics in the initial treatment are crucial. In diabetic patients in particular, complications as serious as infections and sepsis, can develop following foreign body injuries [20].

In the present study, the feet (43.2%) are the predominantly affected location. Metallic needles (67%) the most frequently encountered materials. The most common complication is infection (10.3%) and contaminated wounds possess more risk in this context. The rate of infection is lower in needle (6.25%) and glass wounds (7.14%); this may be due to the nature of those injuries, which are generally not contaminated with minimal tissue damage. On the contrary, the rate of infection (38.4%) is higher in contaminated wounds that develop with puncture by wood and other materials most commonly occur in external environments.

In conclusion, foreign body injuries are severe injuries that may cause significant problems when ignored. The algorithm we present may be useful not only for defining but also for treatment of foreign bodies

REFERENCES

- Sayhan MB, Kavalcı C, Orak M. Bir Yabancı Cismin Atipik Başvurusu: Olgu Sunumu. *Balkan Med J* 2011;28:471-472.
- Maempel JF, Nicol G, Clement RG, Porter D. A foreign body masquerading as a tumour. *BMJ Case Rep* 2013;22.
- Melek H, Şen TH, Köken R, ve ak. Septik artritile başvuran olgunun diz eklemine saptanan yabancı cisim-poster-22. *Güncel Pediatri Derg* 2008;6:22.
- Lee AC, So KT, Wong HL, Lau S. Penetrating pencil injury: an unusual case of child abuse. *Child Abuse Negl* 1998;22:749-52.
- Öztürk R. Çocuk ve Erişkinlerde Aşılama. In: Akkaya N, Camcıoğlu Y, Gür E, Öztürk R, eds. *İ. Ü. Cerrahpaşa Tıp Fakültesi Sürekli Tıp Eğitimi Etkinlikleri*, 1th edn. İstanbul: Doyuran Matbaası, 2010: 65-91.
- Mehdi SA, Dunlop DG, Oliver CW. "Uneasy lies the hand in which rests the crown" an unusual foreign body following a punch injury. *J Hand Surg Br* 2000;25:221-222.
- Phillips C, Mackay DR. An unusual foreign body in the hand: delayed presentation of an intact human tooth. A case report. *Scand J Plast Reconstr Surg Hand Surg* 1995;29:181-183.
- Jaiswal A, Habib M, Tanwar YS. Neglected foreign body in contralateral limb in a traumatic transfemoral amputee radiographs can be misleading. *Chin J Traumatol* 2013;16:61-64.
- Agrawal NK, Patnaik RP. Thorn And Wooden Splinter Induced Osteomyelitis-Like Lesions Of Bone And Soft Tissues. *Indian J Orthop* 1978;12:62-64.
- Yıldırım C, Sözüer EM, Avşaroğulları L, ve ak. Yumuşak doku içindeki radyopak yabancı cisimlerin stereotaksik yöntemlerle çıkarılması. *Ulus Travma Acil Cerrahi Derg* 1999;5:213-216.
- Hocaoğlu E, Kuvat SV, Ozalp B, et al. Foreign body penetrations of hand and wrist: a retrospective study. *Ulus Travma Acil Cerrahi Derg* 2013;19:58-64.
- Sinha M. An unusual foreign body in the hand. *J Hand Surg Eur Vol* 2007;32:231-2.
- Said HG, Masoud MA, Yousef HA, Imam HM. Multidetector CT for thorn (wooden) foreign bodies of the knee. *Knee Surg Sports Traumatol Arthrosc* 2011;19:823-825.
- Ozsarac M, Demircan A, Sener S. Glass foreign body in soft tissue: possibility of high morbidity due to delayed migration. *J Emerg Med* 2011;41:125-128.
- Dar TA, Sultan A, Hussain S, et al. Contracture of the third toe as a delayed presentation of a foreign body in the foot. *Foot Ankle Spec* 2011;4:298-300.
- Büyükdöğün M. Travmada enfeksiyon ve immünite sorunu. *Tıp Araştırmaları Derg* 2010;8:63-68.
- Bulut O, Öztürüm Z. Ortopedik travmatolojik cerrahide antibiyotik profilaksisi. *Cukurova Univ. Tıp Fak Derg* 2002;24:97-100.
- Ertekin C. Travma hastalarında antiyotik kullanımı. *ANKEM Derg* 2005;19:144-147.
- Haverstock BD. Puncture wounds of the foot. *Clin Podiatr Med Surg* 2012;29:311-22.
- Naraynsingh V, Maharaj R, Dan D, Hariharan S. Puncture wounds in the diabetic foot: importance of X-ray in diagnosis. *Int J Low Extrem Wounds* 2011;10:98-100.