

Iatrogenic subdural hematoma mimicking acute epidural hematoma on computed tomography

Bilgisayarlı tomografide akut epidural hematomu taklit eden iyatrojenik subdural hematom

Hakan Ak¹, Sadiye Yolcu², Tugay Atalay¹, Naciye Kış³

ABSTRACT

Computed tomography images of the subdural and epidural hematoma are well defined, crescent and lentiform shapes, respectively. However, it has been reported that both of them might mimic each other in rare instances. Literature reveals seven reports subdural hematoma mimicking epidural. We are reporting a new case of subdural hematoma mimicking epidural hematoma radiologically, which occurred after evacuation of chronic subdural hematoma with burr-hole in a 75 years old man. *J Clin Exp Invest* 2013; 4 (3): 367-369

Key words: Subdural hematoma, epidural hematoma, computed tomography, brain.

INTRODUCTION

Chronic subdural hematoma (SDH) is one of commonly seen pathology in neurosurgery clinics in practice. Its clinical properties and treatment are well defined. In general population incidence is 5/100.000 per year. This ratio arises to 58/100.000 in elderly population [1,2]. The radiological image of subdural hematoma typically seems as crescent, developing because of the tears of the bridging veins between dura and arachnoid. In contrast, epidural hematoma (EDH) is the bleeding that develops between dura and skull and seems as lentiform on radiological evaluation [3]. Although radiological definitions of epidural and subdural hematoma have been explained, these sometimes mimic each other.

In this paper, we are presenting a new case of subdural hematoma radiologically mimicking epidural hematoma.

ÖZET

Subdural hematom ve epidural hematomun bilgisayarlı tomografi görüntüleri iyi tanımlanmıştır, bunlar sırasıyla hilal ve mercekle şeklinde görüntü oluşturmaktadırlar. Bununla birlikte nadir durumlarda bunların birbirlerini taklit edebileceği bildirmiştir. Literatürde epidural hematomu taklit eden 7 sunum mevcuttur. Bu yazıda 75 yaşında bir erkek hastada kronik subdural hematom boşaltılmasını takiben gelişen radyolojik olarak epidural hematomu taklit eden yeni bir subdural hematom olgusu sunulacaktır.

Anahtar kelimeler: Subdural hematom, epidural hematom, bilgisayarlı tomografi, beyin.

CASE

75 age male patient admitted to our emergency department. 2 days ago he admitted to another private clinic with paresis on right side and drowsiness. He had been hospitalized with the pre-diagnosis of ischemic cerebrovascular disease and for two days and drug treatment (Enoxaparine 0.6ml 2x1 and Acetyl salicylic acid (ASA) 100 mg p.o. 1x1) was been given. No bleeding had been seen on his computed tomography (CT) in that clinic. Then he underwent magnetic resonance imaging (MRI) and was brought to our emergency department. He was conscious, oriented, and cooperated. Physical and neurological examination didn't reveal any pathologic sign except early dropping on the right upper extremity. There was no traumatic sign, however there was a history of falling about two months ago. On his MRI, bilateral temporo-parietal chronic subdural hematoma was seen.

¹ Bozok University Department of Neurosurgery, Yozgat, Turkey

² Bozok University Department of Emergency Medicine, Yozgat, Turkey

³ Bitlis State Hospital, Clinic of Radiology, Bitlis, Turkey

Correspondence: Hakan Ak,

Bozok University, School of Medicine Department of Neurosurgery Yozgat, Turkey Email: nrsdrhakanak@yahoo.com

Received: 11.03.2013, Accepted: 04.04.2013

Copyright © JCEI / Journal of Clinical and Experimental Investigations 2013, All rights reserved

We decided to follow him up in the intensive care unit because of using enoxaparine and ASA. 5 days later, he underwent operation by opening two burr holes bilaterally. After the operation early dropping of his right arm and drowsiness were disappeared. On the second day after operation control CT images of brain were taken and lentiform shaped hyperdens image (5x6 mm in size) was seen on left temporal lobe. We didn't think re-operation because of the intact neurological status of the patient. Ten days after operation control CT images were taken again and it revealed acute lentiform shaped image which was bigger than the first control image (Figure 1). We still didn't think re-operation, hematoma leaved to spontaneous resorption.

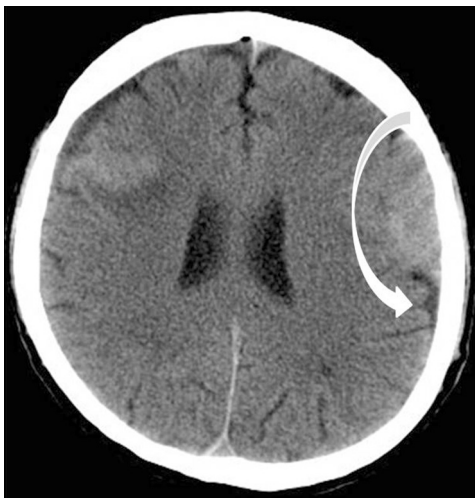

Figure 1. Left sided hyperdens lentiform image on computed tomography

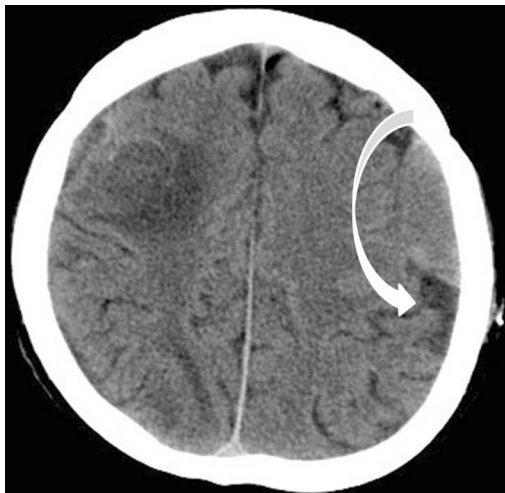


Figure 2. Left sided isodens lentiform image on computed tomography

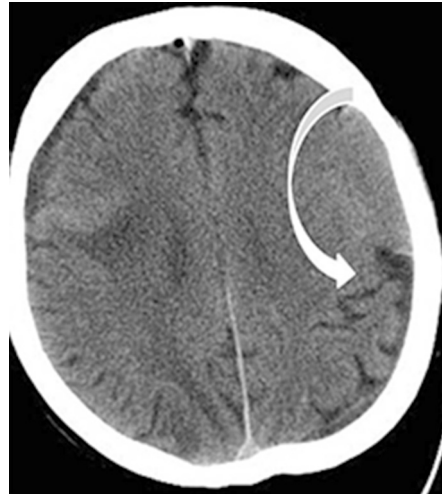

Figure 3. Left sided isodens lentiform image on computed tomography

Patient was discharged with strict suggestions about signs of increased intracranial pressure after taking sutures. 3 days after discharge patient admitted to emergency department with general fatigue and fever. His body temperature was 38.2°C and he had symptoms as upper respiratory tract infection. Laboratory tests revealed that white blood cell count was 14.500/mm³ and blood urea nitrogen was 70 mg. Control CT of brain showed left sided subacute hematoma looking like epidural hematoma, there was no increment in its amount (Figure 2). Patient again hospitalized for follow up and supporting treatment with intravenous fluids and antibiotics was been started. On the 4th day his level of consciousness suddenly decreased. He underwent CT again. We could not detect a different sign except predecessors (Figure 3). We performed left temporo-parietal craniotomy because there was not any possible cause explaining patient's decreased level of consciousness. In the operation we didn't see any hematoma in the epidural region in spite of extending the craniotomy borders. However, we saw that dura was tight and slightly bluish in color. Also, brain pulsations were absent. Dura was opened and we saw that hematoma was located between two different membranes. Also, there was a third different membrane under the first two membranes. Tears created in the first surgery were detected on the all of three membranes. Membranectomy was performed for three membranes and hematoma was evacuated, after that homeostasis was provided, and dura closed in tight water fashion. Patient was discharged without any deficit and he is under clinical control for 6 months.

DISCUSSION

CT images of the subdural and epidural hematoma are well defined. Acute epidural hematoma is seen on CT as a lentiform and homogeneous high-density lesion with or without associated lesions of the overlying skull and soft tissues and it usually appears after trauma [4-6]. Agrawal reported that rapidly accumulating extradural hematoma might mimic acute subdural hematoma on CT scan. He suggested that presence of fracture lines near the clot, presence of pneumocephalus in the clot, at places biconvex in shape, features suggesting that the clot is separated by sutures lines, and buckling of gray matter and absence of underlying brain injury on CT scan were the leading hints of extradural hematoma in his report [7]. Braun et al reported a case in which the cause of the lentiform shape was because of the subdural adhesions resulted from previous asymptomatic intracranial hemorrhages [8].

Besides, acute subdural hematoma has a crescent shape, often cerebral contusion accompanies it [6,9,10]. In practice Acute EDH and SDH can be identified easily on CT scan but sometimes this can be difficult for clinicians. In literature there are seven reports of subdural hematoma mimicking epidural hematoma [11]. Two of them were encapsulated acute subdural hematoma. In our case the possible mechanism of lentiform image was the re-bleeding from a membrane. Rebleeding between two membranes and the presence of another membrane under them caused this image. Possible vacuum phenomena closed the tears which were made in the first operation and it blocked the hemorrhage into subdural spaces so this prevented the development of crescentic shape.

In conclusion, CT images of subdural and epidural hematoma may still mimic each other and it may be a confusing problem for clinicians. In these cases close follow-up of the patients may prevent hazardous results.

REFERENCES

1. Santarius T, Kirrpatrick PJ, Ganesan D, et al. Use of drains versus no drains after burr-hole evacuation of chronic subdural haematoma: a randomised controlled trial. *Lancet* 2009;374:1067-1073.
2. K Mori, Maeda M. Surgical treatment of chronic subdural hematoma in 500 consecutive cases: Clinical characteristics, surgical outcome, complications and recurrence rates. *Neurol Med Chir (Tokyo)* 2001;41:371-381.
3. Kato K, O Watanbe O, Ozawa Y. Abrupt Exacerbation of Acute Subdural Hematoma. Mimicking Benign Acute Epidural Hematoma on Computed Tomography *Neural Med Chir (Tokyo)* 1999;39:33-35.
4. Dolinskas CA, Zimmerman RA, Bilaniuk LT, Gennarelli TA. Computed tomography of post-traumatic extracerebral hematomas: comparison to pathophysiology and responses to therapy. *J Trauma* 1979;19:163-169.
5. Zimmerman RA, Bilaniuk LT. Computed tomographic staging of traumatic epidural bleeding. *Radiology* 1982; 144:809-812.
6. Zimmerman RA, Bilaniuk LT, Gennarelli T, et al. Cranial computed tomography in diagnosis and management of acute head trauma. *AJR Am J Roentgenol* 1978;131:27-34.
7. Agrawal A. Hyperacute extradural hematoma mimicking acute subdural hematoma. *Pak J Neurol Sci* 2008;3:12-13.
8. Braun J, Borovich B, Guilburd JN, et al. Acute subdural hematoma mimicking epidural hematoma on CT. *AJNR Am J Neuroradiol* 1987;8:171-173.
9. Dubin AB, French BN, Rennick JM. Computed tomography in head trauma. *Radiology* 1997;122:365-369.
10. Merino-de Villasante J, Taveras IM. Computerized tomography (CT) in acute head trauma. *AJR Am J Roentgenol* 1976;126:765-778.
11. Miki S, Fujito K, Katayama W, et al. Encapsulated acute subdural hematoma mimicking acute subdural hematoma on computed tomography. *Neurol Med Chir (Tokyo)* 2012;52:826-828.