

Eccrine porocarcinoma: A case report and literature review

Ekrin porokarsinoma: Olgu sunumu ve literatür taraması

Deniz Arslan¹, Ali Murat Tatlı¹, Mükremin Uysal¹, Muhammet Ali Kaplan²

ABSTRACT

Eccrine porocarcinoma is a rarely seen malignant tumor of the sweat glands. It is commonly seen in elderly people and it tends to involve lower extremities. Surgical excision is the main therapeutic modality. It may show local recurrences and systemic metastasis. The effects of chemotherapy and radiotherapy are contradictory. Here, we present a case of 90-years-old female patient with eccrine porocarcinoma localized in the axillary area and additionally we review the existing literature. *J Clin Exp Invest* 2013; 4 (3): 370-373

Key words: Eccrine porocarcinoma, malignant tumor

INTRODUCTION

Eccrine porocarcinoma (EPC) is a rare malignant tumor of the sweat glands. It has initially been described as "epidermotropic eccrine carcinoma" by Pinkus and Mehregan in 1963 and later described as "eccrine porocarcinoma" by Mishima and Morika in 1969 [1,2]. It accounts for a very small part of the epithelial cutaneous cancers. This tumor originates from the intraepithelial parts of the sweat glands [3]. It commonly originates from lower extremity, especially in the elderly patients [4]. Here, we present a case of axillary eccrine porocarcinoma.

CASE REPORT

A 90-years-old female patient was brought to the emergency department with complaints including palpitations, shortness of breath and a swelling with discharge in the right axilla, which have been sustained for 4-5 days. Except for bilateral pleural fluid, bilateral passive atelectasia in the pulmonary parenchyma, cardiomegaly and a mass of approximately 4x5 cm in the right axillary fossa with several nodules in its contiguity, Thoracic computerized tomography revealed no pathologic findings (Figure

ÖZET

Ekrin porokarsinoma ter bezlerinin nadir görülen bir tümördür. Daha çok yaşlılarda gözlenir ve alt ekstremiteleri tutma eğilimindedir. Ana tedavi yöntemi cerrahi eksizyondur ve lokal ve uzak nüksler gösterebilir. Kemoterapi ve radyoterapinin etkisi çelişkilidir. Biz burada 90 yaşında kadın hastada aksillar bölgede lokalize ektrin porokarsinoma vakasını mevcut literatür eşliğinde sunduk.

Anahtar kelimeler: Ekrin porokarsinoma, kemoterapi, aksilla

1). The patient who showed atrial fibrillation signs in the electrocardiography had an ejection fraction of 60%. After the first and also the second biochemical, cytological examination of pleural fluid, It was found that pleural fluid had transudate characteristics, did not contain atypical cells and was adenosine deaminase negative. No microbiological growth was observed. In terms of tuberculosis, after the two consecutive sputum sampling it was shown that, the sputum was negative for acid-resistant bacteria (the sputum was sampled for two times at one-day interval and it was shown that there were no acid resistant bacteria). The patient was diagnosed as hyperthyroiditic and initiated to be given anti-thyroid therapy. In the excisional biopsy obtained from the right axillary lymphadenopathy, the nesting tumor consisted of the cells with coarse hyperchromatic nucleus and eosinophilic cytoplasm was observed. In the cells, periodic acid-schiff (PAS) and diastase periodic acid-schiff (d-PAS) stain-positive granules were found (Figure 2). Pathological diagnosis was reported as primary eccrine porocarcinoma. After the evaluation of Radiological, clinical and pathological findings the diagnose was right axillary region originated locally primary eccrine porocarcinoma. Upon the recurrence of pleural effusion in

¹ Akdeniz University, Faculty of Medicine, Department of Medical Oncology, Antalya, Turkey

² Dicle University, Faculty of Medicine, Department of Medical Oncology, Diyarbakir, Turkey

Correspondence: Muhammet Ali Kaplan,

Dicle University, Faculty of Medicine, Department of Medical Oncology, Diyarbakir, Turkey Email: drmalikaplan@hotmail.com

Received: 15.03.2013, Accepted: 10.04.2013

her follow-ups, a chest tube was placed into the left hemithorax of the patient who developed hypoxia. The patient demonstrated alterations in conscience, but magnetic resonance images of the brain did not show any findings consistent with metastasis. Upon

the regression of Karnofsky performance status to 20%, surgical therapy, radiotherapy or systemic therapy was not given during follow-up and the patient died in the second month of the follow-up due to sepsis resulting from intercurrent infections.

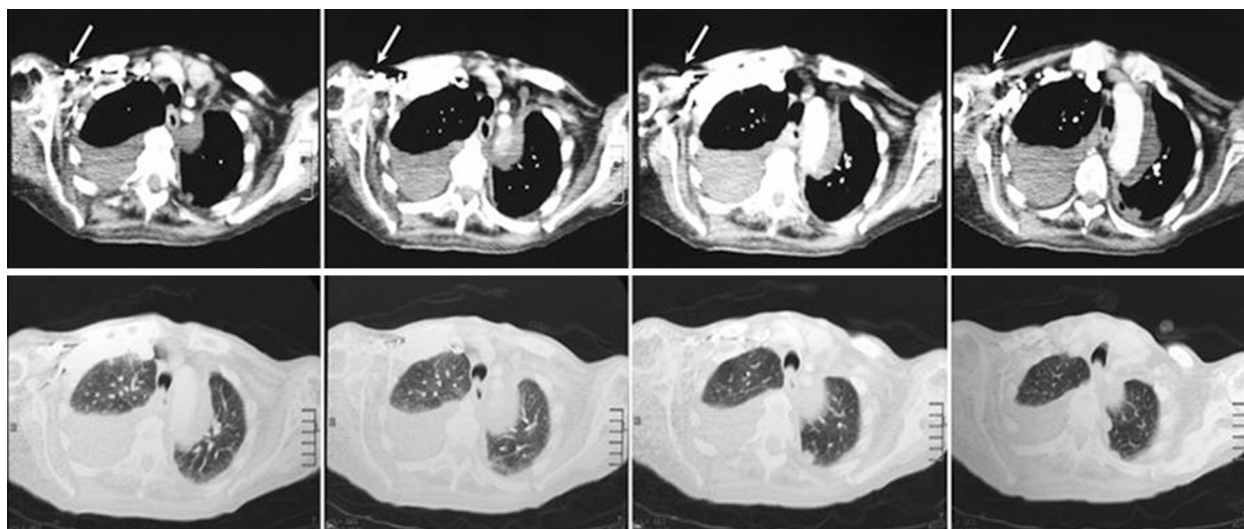


Figure 1. In the thoracic CT sections, bilateral pleural fluid, passive atelectasia in bilateral pulmonary parenchyma, and a mass of approximately 4x5 cm in the right axillary fossa with several nodules in its contiguity (arrow) can be seen, more markedly in the right side.

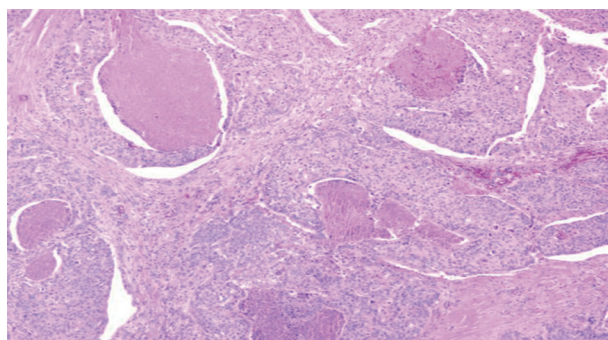


Figure 2. In the sections, a necrotic area is observed in the center of the cell groups with coarse and hyperchromatic nucleus and marked nucleolus (HEX100)

DISCUSSION

Eccrine porocarcinoma is a rarely seen tumor of the sweat glands. It accounts for 0.005% to 0.01% of all skin cancers. Since the first published case in 1963 to date, in the literature, approximately 250 case reports have been presented [5]. While its age of onset ranges between 40 and 80 years, mean age is 58,5 and it equally affects both genders [6,7]. Eccrine poroma is seen with sebaceous nevus, chron-

ic lymphocytic leukemia and malign transformation of the actinic lesions or as de novo, as seen in many cases [8]. Generally, EPC occurs as a single, asymptomatic, solitary nodule, plate and ulcerative lesion [9]. Although the pathogenesis and eventual pre-invasive markers of EPC are unknown, according to the reports of some authors in the literature, predisposing factors include exposure of the skin to burning, trauma or radiotherapy, immunosuppressive therapies administered after the transplantation (kidneys, heart), AIDS and prolonged exposure to ultraviolet light [9,10]. Although it is mostly seen in the lower extremities (50%), it is also seen in the trunk (24%), in the head-neck area (18%), in the upper extremities, in the hands, in the vulva, in the penis, in the pubis and in the abdomen [11,12]. While local metastasis and lymph node metastasis were reported in 20% of the cases, the metastases of visceral organs (lungs, liver, bladder, adrenal gland, peritoneum) and bone was reported in 10% of the cases [13]. Based on case series, in the presence of metastases, the mortality rate reaches 80% [13]. Important histological prognostic factors include the depth of the tumor, the number of mitosis and lymphovascular invasion [13]. In our case, there was no history of primary lesion. It was observed as a

single, ulcerated and running lesion in the axillary area, which is a rarely involved area.

In the differential diagnosis, basal and squamous cell carcinomas, seborrheic keratosis, amelanotic melanoma, verruca vulgaris, cutaneous lymphoma, skin metastases of different types of cancer and other diseases such as Bowen, Paget, hydroacanthoma simplex should be considered [14].

Histologically, majority of the eccrine porocarcinoma cases have acanthotic epidermis associated to neoplastic poromatous epithelial cell islets that invade the dermis. Neoplastic cells have dispersedly hyperchromatic mitotic large nucleus. These cells may be basophilic and may show clear cell differentiation [15]. Its histological diagnosis may be complicated. The study conducted by Robson et al. on a case series of 69 patients highlighted the importance of knowing eccrine ducts. Furthermore, they reported that, if taken as the essential criterion for the diagnosis, some poorly differentiated tumors might be missed [13]. Because of the staining of ECP cells with carcinoembryonic antigen (CEA), the lumens and the cytoplasm of the malignant sweat glands are mostly demonstrated. The cells located in the ductus lumen are characteristically deprived of keratin and, as glycogen granules are numerous in the cytoplasm of all cells, they may be easily seen using PAS [15]. Positive staining with PAS/d-PAS and/or CEA/EMA (epithelial membrane antigen) may also be detected without the observation of eccrine ducts under light microscope [16].

The treatment consists of large local excision of the primary lesion and it may be cured in 70-80% of the cases [17]. There are some publications that reported the absence of recurrence in the 5-year follow-up using Mohs microsurgery technique [18]. In the literature, there is not enough data to support adjuvant therapy (chemotherapy/radiotherapy) and the methods such as cryosurgery and electrosurgery for the prevention of tumor recurrence [9,10]. Regional lymph node metastasis is detected in 20% of the cases [10]. If there is dissemination to regional lymph nodes, regional lymph node dissection should be performed [19]. In these cases, the mortality rate was reported to be 67%. Sentinel lymph node biopsy may be helpful to determine the presence of subclinical metastasis in the regional lymph nodes [20]. Bogner et al. performed sentinel lymph node dissection in five patients, one of which was with salivary gland carcinoma diagnosed with eccrine porocarcinoma, and they detected lymph node metastasis in three patients [21]. More rarely, distant metastasis may also be seen in the patients

diagnosed with eccrine porocarcinoma [22]. Due to the predisposition to local recurrence and metastasis, close post-operative follow-up is required [12]. Very few or partial response was obtained using methotrexate, cisplatin, vincristine, prednisolon, adriamycine, bleomycine, isotretinone, interferon alpha, interleukine-2, 5-fluorouracil and docetaxel [9,11,12]. Da Silva and Bleir obtained successful results using post-operative radiotherapy [23].

As seen in our case, for the patients with an axillary mass, large local excision and axillary lymph node dissection may be recommended [16]. However, in our patient, additional clinical problems resulting from low performance following the biopsy prevented the administration of the surgical therapy. In these patients, there is no adequate data to show the place of radiotherapy in the adjuvant, prophylactic and palliative therapies. Therefore, palliative radiotherapy was not considered.

Consequently, as EPC is a very rarely seen tumor of the sweat glands, there are not so many actual data in the literature that evaluate different therapeutic modalities and their outcomes. As it may be mixed up with other benign and malignant lesions of the skin based on the results of few series reported in the literature, it may be stated that its diagnosis may be complicated, that despite the lack of a complete surgical margin, its primary therapy is surgery, and that the place of chemotherapy and radiotherapy is contradictory. As EPC has a poor prognosis, shows different biological behaviors and especially has the risk for local-regional recurrence and distant metastasis, it should be closely monitored.

REFERENCES

1. Pinkus H, Mehregan AH. Epidermotropic eccrine carcinoma. *Arch Dermatol* 1963; 88:597-606.
2. Mishma Y, Morioka S. Oncogenic differentiation of the intra-epidermal eccrine sweat duct: eccrine poroma, poro-epithelioma, and porocarcinoma. *Dermatologica* 1969;138:238-250.
3. Whitt P, Whelchel J, Ruff T. Eccrine porocarcinoma. *Ear Nose Throat J* 1996;75:536-538.
4. Snow SN, Reizner GT. Eccrine porocarcinoma of the face. *J Am Acad Dermatol* 1992;27:306-311.
5. Chang NC, Tsai KB. Eccrine porocarcinoma of the auricle: a case report. *Kahohsiung J Med Sci* 2009;25:401-404.
6. Ou CL, Cheng CJ. Porocarcinoma in situ showing follicular differentiation: A case report. *Dermatologica Sinica* 2012;30:47-50.
7. Poiars Baptista A, Tellechea O, Reis JP, et al. Porocarcinome Eccrine - Revue de 24 cas. *Ann Dermatol Venereol* 1993;120:107-115.

8. Ritter AM, Graham RS, Amaker B, et al. Intracranial extension of an eccrine porocarcinoma. Case report and review of the literature. *J Neurosurg* 1999;90:138-140.
9. Ferri E, Iaderosa GA, Armato E. Metastasizing eccrine porocarcinoma of the nose: case-report with immunohistochemical study and review of the literature. *Internet J Otorhinolaryngology* 2008;7:2.
10. Turner JJ, Maxwell L, Bursle GA. Eccrine porocarcinoma: a case report with light microscopy and ultrastructure. *Pathology* 1982;14:469-475.
11. Bhat W, Akhtar S, Khotwal A, Platt AJ. Primary Eccrine Porocarcinoma of the finger with transit forearm and axillary metastasis. *Ann Plast Surg* 2011;66:344-346.
12. Chang O, Elnawawi A, Rimpel B, et al. Eccrine porocarcinoma of the lower extremity: A case report and review of literature. *World J Surg Oncol* 2011;9:94.
13. Robson A, Greene J, Ansari N, et al. Eccrine porocarcinoma (malignant eccrine poroma): a clinicopathologic study of 69 cases. *Am J Surg Pathol* 2001;25:710-720.
14. Elder D, Elenitsas R, Ragsdale BD. Tumors of the epidermal appendages. In: Elder D, Elenitsas R, Jaworsky C, Johnson B, editors. *Lever's Histopathology of the skin*. Philadelphia: JB Lippincott; 1997;747-803.
15. Mehregan AH, Hashimoto K, Rahbari H. Eccrine adenocarcinoma. A clinicopathologic study of 35 cases. *Arch Dermatol* 1983;119:104-114.
16. Saynak M, Koçak Z. Ekrin porokarsinom: Olgu sunumu ve literatür derlemesi. *Türk Onkoloji Dergisi* 2007;22:188-191.
17. Goel R, Contos MJ, Wallace ML. Widespread metastatic eccrine porocarcinoma. *J Am Acad Dermatol* 2003;49:252-254.
18. Writtenberg G, Robertson D, Solomon AR, et al. Eccrine porocarcinoma treated with Mohs micrographic surgery: a report of five cases. *Dermatol Surg* 1999;25:911-913.
19. Arslan E, Tatar C, Aksoy A, Tutuncu N. De novo malignant eccrine poroma of the nose: a review of the midface as a location. *Plast Reconstr Surg* 2004;113:2227-2229.
20. Thompson JF, Uren RF. Lymphatic mapping in management of patients with primary cutaneous melanoma. *Lancet Oncol* 2005;6:877-885.
21. Bogner PN, Fullen DR, Lowe L, et al. Lymphatic mapping and sentinel lymph node biopsy in the detection of early metastasis from sweat gland carcinoma. *Cancer* 2003;97:2285-2289.
22. Plunkett TA, Hanby AM, Miles DW, Rubens RD. Metastatic eccrine porocarcinoma: response to docetaxel (Taxotere) chemotherapy. *Ann Oncol* 2001;12:411-414.
23. DaSilva MF, Terek R, Weiss AP. Malignant eccrine poroma of the hand. A case report. *J Hand Surg* 1997;22:511-514.