

Reoperative coronary artery bypass grafting

Koroner arter bypass greftlemesi yeniden operasyonu

Hüseyin Katlandur¹, Şeref Ulucan¹, Ahmet Keser¹, Zeynettin Kaya¹, Abdullah Tuncez²

ABSTRACT

Reoperative coronary artery bypass grafting (redo CABG) operation is associated with a high rate of mortality up to 11.4%. It has been estimated that 10-20% of patients with history of coronary artery bypass grafting (CABG) operation need redo CABG operation within 10 years. Due to high operation risk percutaneous coronary interventions have emerged as the preferred treatment for the patients with a history of CABG operation and presenting with acute coronary syndrome. Here, we reported percutaneous coronary intervention in a patient needed redo CABG operation. *J Clin Exp Invest* 2013; 4 (3): 380-382

Key words: Acute coronary syndrome, redo CABG operation, percutaneous coronary intervention.

ÖZET

Koroner arter bypass greftlemesi yeniden operasyonu %11,4'e varan oranlarda yüksek mortalite ile birlikte dir. Koroner arter bypass greftleme (KABG) operasyonu geçiren hastaların %10-20'sinin 10 yıl içinde yeniden KABG operasyonuna ihtiyaç duyacakları tahmin edilmektedir. Yüksek ameliyat riskleri nedeniyle KABG öyküsü olan ve akut koroner sendromu ile gelen hastalar için perkutan koroner girişimler önerilen tedavi yöntemi olarak ortaya çıkmıştır. Burada yeniden KABG operasyonu ihtiyacı doğan bir hastada uyguladığımız perkutan koroner girişimi sunduk.

Anahtar kelimeler: Akut koroner sendrom, yeniden KABG operasyonu, perkutan koroner girişim

INTRODUCTION

Reoperative coronary artery bypass grafting (redo CABG) operation is associated with a high rate of mortality up to 11.4% [1]. It has been estimated that 10-20% of patients with history of CABG operation need redo CABG operation within 10 years [2,3]. AWESOME study showed percutaneous coronary intervention (PCI) is preferable to redo CABG operation in patients who had medically refractory myocardial ischemia [4]. Due to high operation risk PCI have emerged as the preferred treatment for the patients with a history of CABG operation and presenting with acute coronary syndrome [5].

CASE

A 72-year-old man admitted to emergency department with complaint of typical chest pain and dyspnea. The patient had a history of CABG operation fifteen years ago. Two saphenous vein grafts (SVG) were anastomosed to the posterior descending artery and the obtuse marginal branch of the circumflex (Cx) artery. The left internal mammary artery

(LIMA) was anastomosed distally to the left anterior descending artery (LAD). The resting 12-lead electrocardiogram (ECG) showed anterior ischemia. The patient was transferred to the catheter lab after prescription of loading dose of clopidogrel, aspirin and intravenous unfractionated heparin. Coronary angiography performed and showed LAD occlusion after the site of anastomosis, Cx artery occlusion after the obtuse marginal branch and the right coronary artery (RCA) occlusion in the mid segment. The SVG of the posterior descending artery was occluded in the proximal segment and the SVG of the obtuse marginal branch occluded 95% in ostial segment of aortic anastomosis (Figure 1A). LIMA graft was open but the distal LAD segment occluded 90% (Figure 1B). The patient had ongoing chest pain and coronary lesions thought to be suitable for percutaneous transluminal coronary angioplasty. We decided to perform on-site PCI to the anastomosis of the SVG lesion. A 6-Fr Judkins right guiding catheter (Cordis, Johnson & Johnson, Bridgewater, NJ, USA) was engaged in the SVG through the right femoral artery. A 0.014-inch PT2 guide wire (Boston Scientific, USA) was placed in the SVG to

¹ Cardiology Department of Mevlana (Rumi) Medical School, Konya, Turkey

² Cardiology Department of Konya Numune State Hospital, Konya, Turkey

Correspondence: Zeynettin Kaya,

Cardiology Department of Mevlana (Rumi) Medical School, Konya, Turkey Email: zeynettinkeya@yahoo.com

Received: 05.05.2013, Accepted: 20.05.2013

Copyright © JCEI / Journal of Clinical and Experimental Investigations 2013, All rights reserved

the obtuse margin. We performed angioplasty with a 2.5×10 mm Sapphire balloon (Orbus Neich, Hong Kong) at 8 atmospheres, and a 3.5×8 mm Mustang stent (Microport, China) at 18 atmospheres, and TIMI 3 flow was maintained (Figure 2A). Secondly, a 6-Fr Judkins right guiding catheter was engaged in the LIMA and 0.014-inch PT2 guide wire was placed to the LAD artery. We performed angioplasty with a 2.0×15 mm Sapphire balloon at 8 atmospheres, and a 2.75×18 mm Nobori biolimus-eluting stent (Terumo, Tokyo, Japan) at 18 atmospheres, and

TIMI 3 flow was maintained (Figure 2B). The patient's chest pain relieved. Ischemic ECG changes improved. The patient was discharged without any complications. Six months later, the control coronary angiography performed and there was no stent restenosis (Figure 3A and 3B).

We think that percutaneous coronary intervention can be used as a safe and low risk method for selected patients with history of CABG operation even if presented with acute coronary syndrome and are thought to go Redo CABG operation.

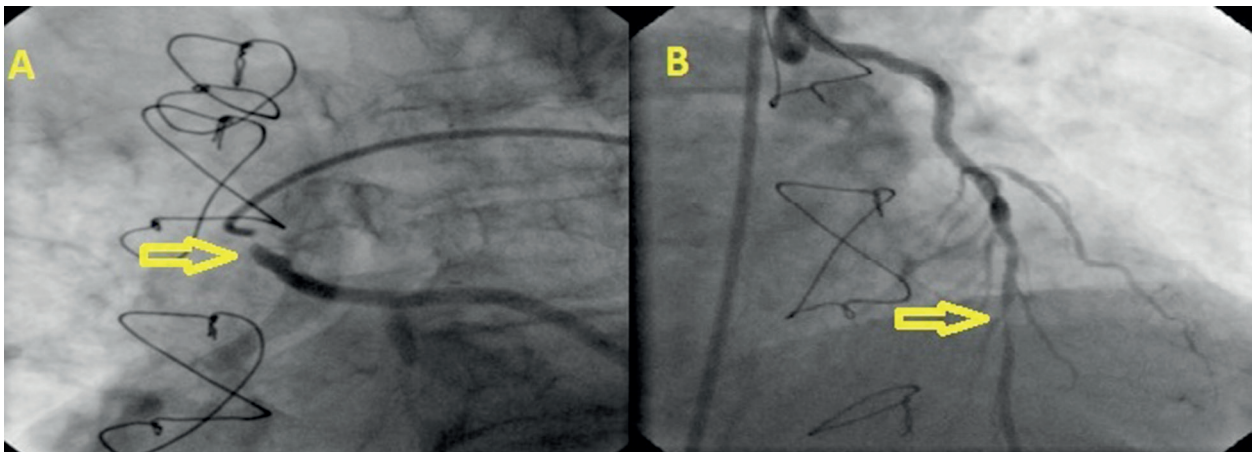


Figure 1. Coronary angiography shows the ostial saphenous graft lesion (A) and LAD lesion (B)

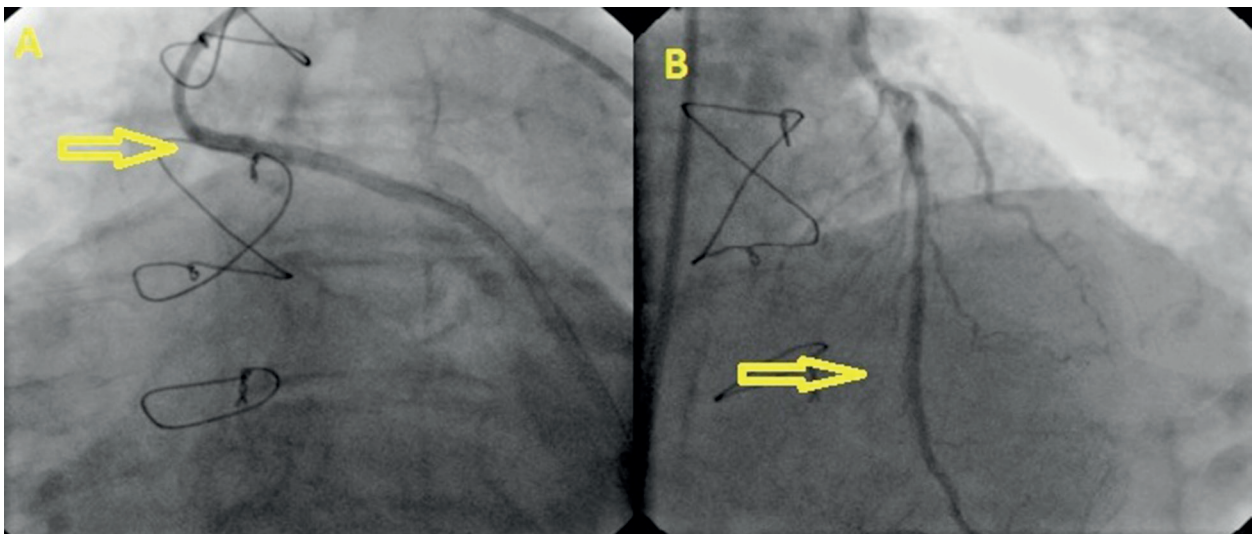


Figure 2. Coronary angiography demonstrates the saphenous vein graft after stenting (A) and LAD lesion after stenting (B)

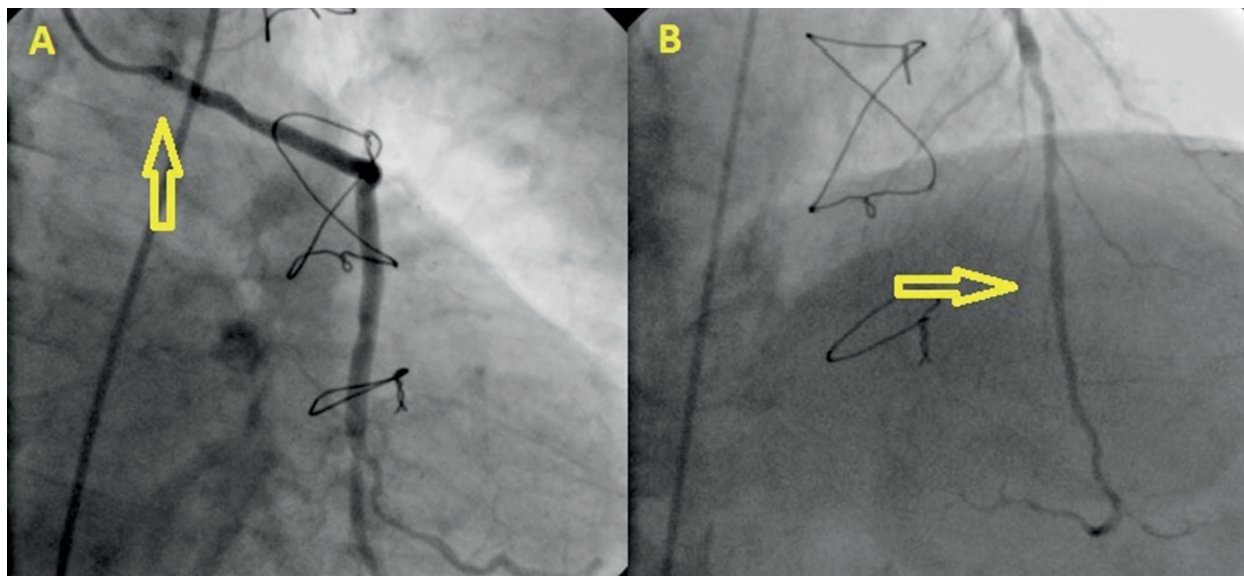


Figure 3. Control coronary angiography six months later shows patent saphenous vein graft stent (A) and LAD stent (B)

REFERENCES

1. Beldi G, Bosshard A, Hess OM, et al. Transit time flow measurement: experimental validation and comparison of three different systems. *Ann Thorac Surg* 2000;70:212-217.
2. Lytle BW, Loop FD. Superiority of bilateral internal thoracic artery grafting; it's been a long time comin. *Circulation* 2001;104:2152-2154.
3. Shahabuddin S, Ansari JA, Siddiqui FJ, et al. Redo coronary artery surgery; early and intermediate outcomes from a tertiary care hospital in a developing country. *J Pak Med Assoc* 2011;61:31-35.
4. Morrison DA, Sethi G, Sacks J, et al. Percutaneous coronary intervention versus repeat bypass surgery for patients with medically refractory myocardial ischemia: AWESOME randomized trial and registry experience with post-CABG patients. *J Am Coll Cardiol* 2002;40:1951-1954.
5. Yazdani SK, Farb A, Nakano M, et al. Pathology of drug-eluting versus bare-metal stents in saphenous vein bypass graft lesions. *JACC Cardiovasc Interv* 2012;5:666-667.