

CASE REPORT

Osteoma located in the external ear canal

Dış kulak kanalında lokalize osteom

Ekrem Karakaş¹, Nihat Kılıcaslan¹, Ömer Karakaş¹, Ferit Dogan¹, Ferhat Bozkuş²

ABSTRACT

Osteomas of the temporal bone are rare, slowly growing, benign neoplasms. They can cause symptoms of conductive hearing loss and fullness in the ear. We aimed to report the case of a 43-year-old female patient with osteoma located in the external ear canal. *J Clin Exp Invest* 2013; 4 (2): 221-222

Key words: CT, external auditory canal, osteoma

ÖZET

Temporal kemik osteomu nadir, yavaş büyüyen, benign tümörlerdir. Kulakta iletim tipi işitme kaybı ve dolgunluk semptomlarına neden olabilir. Biz dış kulak kanalında osteomu olan 43 yaşındaki kadın olguyu sunmayı amaçladık.

Anahtar kelimeler: BT, dış kulak kanalı, osteom

CASE REPORT

A 43-year-old male presented at hospital with pain in the left ear and decreased hearing which had been ongoing for a year. Physical examination revealed the external ear canal to be closed. In the hearing test, conductive hearing loss was determined. In line with this finding, thin section temporal bone Computed Tomography (CT) examination was made using 16-slice CT machine. CT images were seen in Figure a and 2. Bushing in the left external ear, and a 10 mm diameter bone lesion with equivalent density to bone were observed in the antero-superior bone structure section opening to the external ear canal and showing continuity. The patient underwent surgery. Histopathologically a diagnosis was made of osteoma originating from the external ear canal.

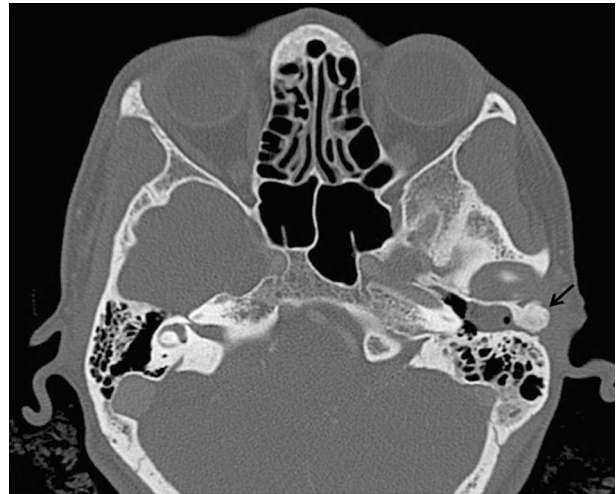


Figure 1. Bushing in the left external ear and 10 mm diameter bone lesion with equivalent density to bone in the antero-superior bone structure section opening to the external ear canal and showing continuity, were observed on the axial temporal bone CT image.

¹ Harran University, Faculty of Medicine, Department of Radiology, Şanlıurfa, Turkey

² Harran University, Faculty of Medicine, Department of Otolaryngology, Şanlıurfa, Turkey

Correspondence: Ekrem Karakaş,

Harran Üniversitesi Tıp Fakültesi Radyoloji Bölümü, Şanlıurfa, Türkiye Email: karakasekrem@yahoo.com

Received: 03.12.2012, Accepted: 19.12.2012

Copyright © JCEI / Journal of Clinical and Experimental Investigations 2013, All rights reserved

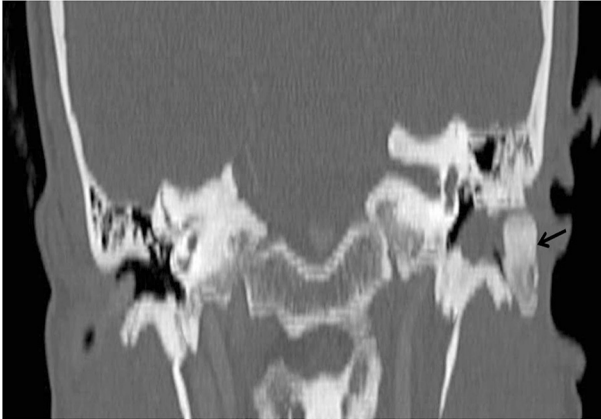


Figure 2. Bushing in the left external ear and 10 mm diameter bone lesion with equivalent density to bone in the section opening to the external ear canal, were observed on the coronal reformatted temporal bone CT image.

DISCUSSION

Osteomas are slow growing benign osseous tumors of unknown etiology. Osteomas of the temporal bone are rare. They develop in the external auditory canal on squamous sections. Osteoma location is frequently seen in the paranasal sinus, then less in the external ear canal, the orbital wall, the temporal bone, the pterygoid process and the mandible, respectively [1,2]. The radiographic appearance is that of a dense well circumscribed mass. CT reveals a well circumscribed mass of variable density, varying from very dense to less dense with a ground-glass appearance. While direct radiographs are ad-

equate for small lesions, CT is useful in defining the relationship between lesion size and surrounding tissue in large lesions [3]. In the differential diagnosis, it is necessary to consider other lesion with bone content such as exocytosis, osteoid osteoma and osteosarcoma [4]. Osteomas are true bone tumours. Specific findings are encountered related to the localisation of the mass [1,2]. In our case, the blocking of the external ear canal by the osteoma caused conductive hearing loss. Osteomas do not show malign transformation and the recurrence rate is low [2]. In the short-term, no recurrence was observed in our case. It can be concluded that in patients with conductive hearing loss, a differential diagnosis of external ear canal osteoma should be considered. Temporal bone CT is a valuable diagnostic tool in diagnosis and follow-up.

REFERENCES

1. Ebelhar AJ, Gadre AK. Osteoma of the external auditory canal. *Ear Nose Throat J* 2012;91:96–100.
2. Carbone PN, Nelson BL. External auditory osteoma. *Head Neck Pathol* 2012;6:244–246.
3. Chen CY, Ying SH, Yao MS et al. Sphenoid sinus osteoma at the sella turcica associated with empty sella: CT and MR imaging findings. *AJNR Am J Neuroradiol* 2008;29:550-551.
4. Daniels DL, Shaffer KA, Houghton VM. The base of the skull: sella and temporal bone. In: Lee SH, Rao KCVG, Zimmerman RA, *Cranial MRI and CT*. 3rd ed. New York: Mc Graw-Hill inc, 1992;441-507.