

CASE REPORT

Metoclopramide-induced parkinsonism due to bilateral basal ganglia and brain stem involvement in a patient with laryngeal carcinoma

Larinks kanserli hastada beyin sapı ve bazal ganglion tutulumu ile birlikte metoklopramidin indüklediği parkinsonizm

Ali İnal¹, Ertuğrul Uzar², Muhammed Ali Kaplan¹, Mehmet Küçüköner¹, Zuhat Urakcı¹, Faysal Ekici³, Abdurrahman Işıkdoğan¹

ABSTRACT

Parkinsonism and basal ganglion involvement due to antiemetic drugs, such as metoclopramide, is rarely encountered. However, bilateral basal ganglia and brain stem involvement has not yet been reported in patients with drug-induced Parkinsonism.

A 52-year-old male patient with laryngeal carcinoma was treated with docetaxel, cisplatin, and 5-fluorouracil (DCF) chemotherapy. Because of severe nausea and vomiting 15 days after the first course of chemotherapy, metoclopramide was administered. Parkinsonism symptoms were observed on the 6th day of metoclopramide therapy. Cerebral MRI revealed bilateral basal ganglia and brain stem involvement. Metoclopramide therapy was promptly discontinued and oral biperiden was commenced. Parkinsonism findings almost completely improved on his control examination performed after one month. He was not given metoclopramide during further chemotherapy courses. Cerebral MRI taken after three months revealed that the lesions have completely relieved.

This is an extremely rare case of metoclopramide-induced parkinsonism together with brain stem and basal ganglion involvement in a patient with laryngeal carcinoma treated by chemotherapy. The clinical and radiological improvement was observed with the cessation of the causative drug and biperiden therapy. *J Clin Exp Invest* 2012; 3(4): 536-538

Key words: Parkinsonism, metoclopramide, laryngeal carcinoma

INTRODUCTION

The drug-induced parkinsonism accounts for approximately 2.7% of these patients.¹ Metoclopramide is a dopamine receptor antagonist and may occasionally cause extrapyramidal side effects

ÖZET

Metoklopramid gibi antiemetik ilaçlara bağlı parkinsonizm ve bazal ganglion tutulumu nadirdir. Ancak, bilateral bazal ganglion ve beyin sapı tutulumu ilaca bağlı parkinsonizm hastalarında henüz bildirilmemiştir.

Larinks kanseri olan 52 yaşındaki erkek hasta dosetaksel, sisplatin ve 5-fluorourasil (DCF) kemoterapisi ile tedavi edildi. Kemoterapinin ilk küründen 15 gün sonra şiddetli bulantı ve kusma şikayeti nedeniyle metoklopramid verildi.

Metoklopramid tedavisinin 6. gününde parkinsonizm belirtileri gözlemlendi. Çekilen serebral MRG'de bilateral bazal ganglionlarda ve beyin sapında tutulum saptandı. Metoklopramid tedavisi derhal kesilerek ve ağızdan biperiden başlandı. Parkinsonizm bulguları bir ay sonra gerçekleştirilen kontrol muayenesinde neredeyse tamamen düzeldi. Hastaya daha sonraki kemoterapi tedavilerinde metoklopramid verilmedi. Üç ay sonra çekilen serebral MRG'de lezyonlar tamamen düzeldi.

Kemoterapi ile tedavi edilen larinks kanserli hastada beyin sapı ve bazal ganglion tutulumu ile birlikte metoklopramidin indüklediği parkinsonizm çok nadir görülen bir durumdur. Klinik ve radyolojik iyileşme neden olan ilacın kesilmesi ve biperiden tedavisi ile gözlenmiştir.

Anahtar kelimeler: Parkinsonizm, metoklopramid, larinks kanseri

due to its dopaminergic antagonistic effect.^{2,3} Parkinsonism and basal ganglion involvement due to antiemetic drugs, such as metoclopramide, is rarely reported,⁴ whereas bilateral basal ganglia and brain stem involvement has not yet been reported until now on the brain MRI of the patients with drug-in-

¹ Department of Medical Oncology, Dicle University Faculty of Medicine, Diyarbakır, Turkey

² Department of Neurology, Dicle University Faculty of Medicine, Diyarbakır, Turkey

³ Department of Radiology, Dicle University Faculty of Medicine, Diyarbakır, Turkey

Correspondence: Ali İnal, Dicle Üniversitesi Tıp Fakültesi Tıbbi Onkoloji Kliniği, Diyarbakır, Türkiye Email: dr.ainal@gmail.com

Received: 19.09.2012, Accepted: 26.11.2012

Copyright © JCEI / Journal of Clinical and Experimental Investigations 2012, All rights reserved

duced Parkinsonism. We present the first case of metoclopramide-induced Parkinsonism together with brain stem and basal ganglion involvement in a patient with laryngeal carcinoma treated with chemotherapy.

CASE REPORT

A 52-year-old male patient with locally advanced laryngeal carcinoma. He started to receive a chemotherapy regimen consisted of docetaxel, cisplatin, and 5-fluorouracil (DCF). He was admitted to our clinic because of severe nausea and vomiting 15 days after the first course of chemotherapy. Fluid replacement and metoclopramide (oral, 20 mg daily) were commenced to control dehydration and vomiting. Tremor in the hands, dysarthria, mask face, restlessness, irritability and limited movement developed in the patient on the 6th day of metoclopramide therapy. Neurologic examination revealed akathisia, sialorrhea, hypomimia, bradykinesia, parkinsonian gait and tremor in all extremities. Drug-induced parkinsonism and akathisia (extrapyramidal side effect) were diagnosed for the patient by the consultation with the neurology department. Complete blood count, electrolytes, anti DNA, Vitamin B12, folic acid and thyroid functions were within the normal ranges. On his cerebral MRI, T1 hypointense and T2 hyperintense signal changes were de-

termined in the bilateral basal ganglia, including putamen, globus pallidus and the head of the caudate nucleus, as well as in the mesencephalon area, including nucleus ruber and nucleus ruber (fig. 1a, 1b). Laryngeal cancer metastasis was not considered, because the contrast substance was not uptaken by the lesions on the contrast-enhanced MRI of the cerebrum.

Metoclopramide therapy was immediately discontinued and oral biperiden was started with the dose of 2 mg three times daily. Parkinsonism symptoms slightly improved on the 3rd day of biperiden therapy. Neurologic examination performed 15 days later revealed bilateral tremor in the hands of the patient has disappeared and limited movement and dysarthria have considerably regressed. The parkinsonian findings almost completely improved on control examination after one month. The lesions in the basal ganglion were absent on the follow-up MRI of the cerebrum. However, T1 hypointense and T2 hyperintense changes were observed on the brain stem lesions, including nucleus ruber (Fig. 1c, 1d). Biperiden therapy was gradually decreased and discontinued. DCF course was repeated for three times. Metoclopramide was not preferred as an antiemetic in this patient. Parkinsonism complaints did not recur, and the patient has been free of any associated symptoms.

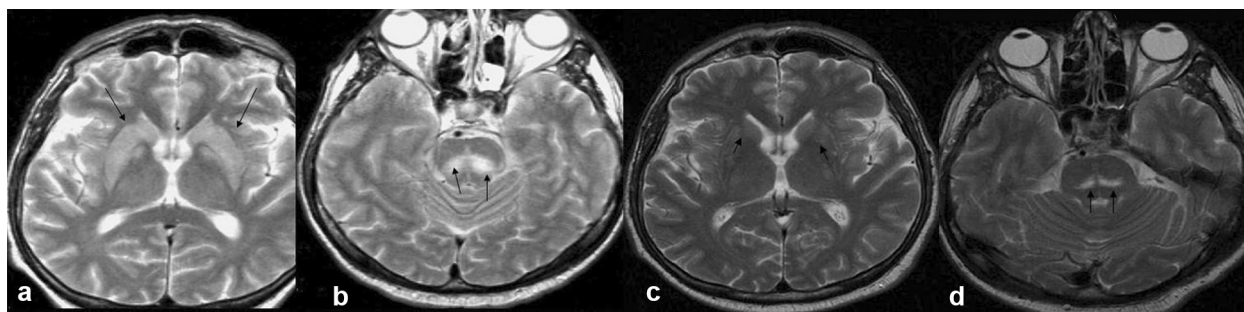


Figure 1, a; Axial T2 MRI revealed T2 hyperintense signal changes in the caudate nucleus, globus pallidus and putamen, **b;** as well as in the mesencephalon region, including nucleus ruber and the periphery of nucleus ruber, **c;** The follow-up cerebral T2 axial revealed the increased signal to disappear in the caudate nucleus, globus pallidus and putamen, **d;** however, the increased signal persisted in the mesencephalon region.

DISCUSSION

Symptoms due to the damage of the extrapyramidal system, such as parkinsonism, acute dystonic reaction, akathisia, motor tics, myoclonus and tardive dyskinesia, may be seen. One of these symptoms may occur alone, or they may present together.⁴ It has been put forward that the pathogenesis of drug-induced Parkinsonism results from the imbalance between acetylcholine and dopamine in the central

nervous system (CNS). Extrapyramidal side effects commonly appear 24 hours after metoclopramide is started and generally disappears 24 hours after discontinuation. Extrapyramidal side effects quite rarely persist for weeks or months.³ In this case, dysarthria, irritability, desire to move continuously, slowing down in walking, and tremor were developed after 24 hours following metoclopramide given in order to prevent nausea. Metoclopramide-induced Parkinsonism and akathisia, rather than idiopathic

Parkinson's disease, was considered owing to the fact that he had no history of Parkinson's disease and that his complaints have begun bilaterally and acute. No other reason was found that could lead to parkinsonism and akathisia. It has been reported that certain chemotherapeutic agents cause parkinsonism.⁵ Parkinsonism symptoms were not present in this case during the first course of anticancer therapy. Following the second course of anticancer therapy, parkinsonism was seen at the same time with metoclopramide. After the relief of parkinsonism, it did not recur following the third course of anticancer therapy. Moreover, metoclopramide-induced parkinsonism has been reported more commonly than anticancer drug-induced parkinsonism.^{1-4,6} Consequently, Parkinsonism and akathisia were not attributed to the anticancer therapy. Moreover, they gradually disappeared with the cessation of metoclopramide. Metoclopramide-induced Parkinsonism and akathisia together with the involvement of basal ganglion, thalamus and brain stem in cancer patients has not yet been reported. However, in Parkinsonism caused by toxic substances, such as carbon monoxide and manganese, globus pallidus, substantia nigra, nucleus ruber and brain stem can also be involved. Parkinsonism may be developed due to the involvement of the extrapyramidal system, including brain stem, substantia nigra, striatum and thalamus.⁷⁻¹⁰

The cerebral MRI performed in the subacute period revealed bilateral involvement of the putamen, as well as globus pallidus, the head of the caudate nucleus, substantia nigra from the mesencephalon to pons, and nucleus ruber in this case. This shows that the effect of metoclopramide on the extrapyramidal pathways is similar with that of manganese and carbon monoxide intoxication. Parkinsonism complaints of the patient decreased within one month with chemotherapy. Caudate nucleus, globus pallidus and putamen lesions of the present case disappeared on his control MRI performed after three months. Although the Parkinsonism signs have disappeared, nucleus ruber lesions persisted at the mesencephalon level.

Metoclopramide-induced Parkinsonism and akathisia can be seen rarely. Putamen, globus pallidus, the head of caudate nucleus and nucleus ruber may also be affected in such patients. In a case of metoclopramide-induced Parkinsonism, cerebral MRI should be performed to visualize the major damage in the extrapyramidal system.

REFERENCES

1. Esper CD, Factor SA. Failure of recognition of drug-induced parkinsonism in the elderly. *Mov Disord* 2008; 23(3):401-4.
2. Hawkins R, Grunberg S. Chemotherapy-induced nausea and vomiting: challenges and opportunities for improved patient outcomes. *Clin J Oncol Nurs* 2009; 13(1): 54-64.
3. Dubow JS, Leikin J, Rezak M. Acute chorea associated with metoclopramide use. *Am J Ther* 2006; 13(6):543-4.
4. Moos DD, Hansen DJ. Metoclopramide and extrapyramidal symptoms: a case report. *J Perianesth Nurs* 2008; 23(5):292-9.
5. Chuang C, Constantino A, Balmaceda C, Eidelberg D, Frucht SJ: Chemotherapy-induced parkinsonism responsive to levodopa: an underrecognized entity. *Mov Disord* 2003; 18(3): 328-31.
6. Pasricha PJ, Pehlivanov N, Sugumar A, Jankovic J. Drug Insight: from disturbed motility to disordered movement--a review of the clinical benefits and medicolegal risks of metoclopramide. *Nat Clin Pract Gastroenterol Hepatol* 2006; 3(3):138-48.
7. Perl DP, Olanow CW. The neuropathology of manganese-induced Parkinsonism. *J Neuropathol Exp Neurol* 2007; 66(8):675-82.
8. Kinoshita T, Sugihara S, Matsusue E, Fujii S, Ametani M, Ogawa T. Pallidoreticular damage in acute carbon monoxide poisoning: diffusion-weighted MR imaging findings. *AJNR Am J Neuroradiol* 2005; 26(7):1845-8.
9. Gandini C, Prockop LD, Butera R, Locatelli C, Manzo L. Pallidoreticular-rubral brain damage on magnetic resonance imaging after carbon monoxide poisoning. *J Neuroimaging* 2002; 12(2):102-3.
10. Arıkanoğlu A, Hünkar R, Çınar K. Parkinsonism secondary to bilateral subdural hematoma. *Dicle Medical Journal* 2011; 38 (2): 247-9.