

A mobile thrombus in the left main coronary artery which caused acute myocardial infarction

Akut miyokard infarktüsüne neden olan sol ana koroner arter içindeki hareketli trombüs

Zeynettin Kaya, Abdullah Tuncez, M. Alparslan Küçük

J Clin Exp Invest 2012; 3(4): 558-558

Intracoronary thrombus, vasospasm and coronary embolism are participating in the pathophysiology of acute myocardial infarction. Occlusion of the left main coronary artery (LMCA) with thrombus is rare but it's very mortal case.^{1,2} Choice of treatment options depend on the clinical presentation of the patient and result of angiographic examination. Total occlusion of the LMCA with thrombus can be treated with percutaneous coronary intervention under intraaortic balon pump back up.³ Subtotal thrombotic occlusion of the LMCA can be successfully treated with coronary artery bypass graft (CABG) operation or thrombolytic treatment.¹⁻²

We present a 54-year old man referred to our hospital with acute anterior myocardial infarction. The coronary angiogram performed with guiding

catheter revealed a mobile thrombus image on LMCA (Figure 1a-1b). The patient was hemodynamically stable, chest pain was resolved and we decided to use intracoronary streptokinase. 250 kU of streptokinase diluted with 20 ml of saline was infused through the guiding catheter within 3 min. Because there was no sign of significant lesion at LMCA we didn't consider urgent CABG operation. Also because of risk of thrombus embolization we didn't use thrombectomy catheter. Control coronary angiography performed with diagnostic catheter, revealed no coronary thrombus on LMCA but showed significant ostial stenosis of LMCA (Figure 1c). Catheter induced spasm eliminated with performing non selective coronary angiogram and nitrate infusion. In conclusion the patient referred to cardiovascular surgery clinic for elective CABG operation.

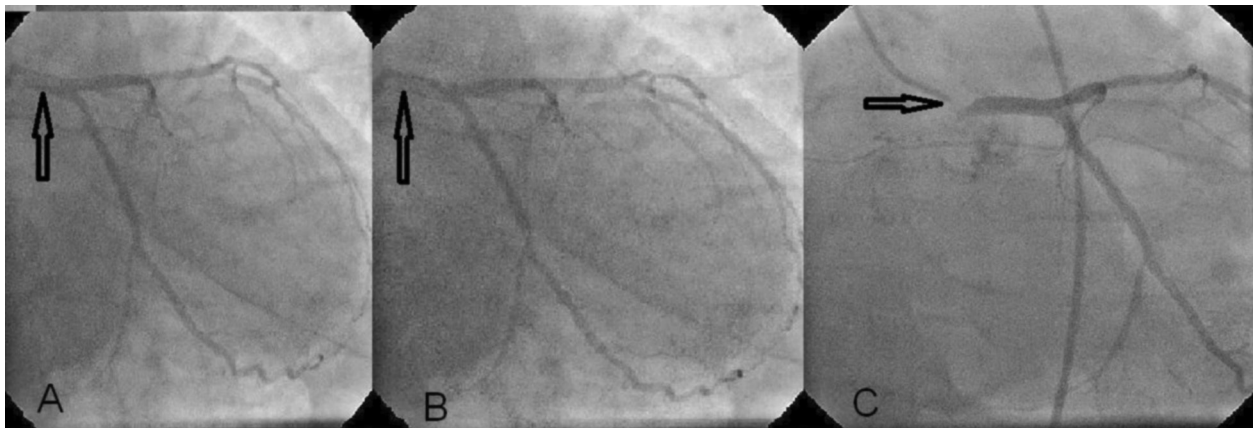


Figure 1. The coronary angiogram performed with guiding catheter revealed a mobile thrombus image on LMCA

REFERENCES

1. Ikitimur B, Gurmen T, Tabakan A, Suzer K. Acute coronary syndrome caused by a mobile mass in the left main coronary artery. *J Am Coll Cardiol* 2010;55(15):e131.
2. Karavelioglu Y, Ekicibasi E, Tanalp AC, Karapinar H, Aung SM. Worm-like thrombus in left main coronary artery after cytostatic treatment. *Blood Coagul Fibrinolysis* 2010;21(5):491-3.
3. Dwyer N, Kanani R. Images in clinical medicine. Left main coronary artery thrombosis. *N Engl J Med* 2012;366(14):e21.

Konya Numune Hastanesi Kardiyoloji Kliniği, Konya Türkiye

Correspondence: Zeynettin Kaya ,

Konya Numune Hastanesi Kardiyoloji Kliniği, Konya, Türkiye Email: zeynettinkaya@yahoo.com

Received: 12.09.2012, Accepted: 10.12.2012

Copyright © JCEI / Journal of Clinical and Experimental Investigations 2012, All rights reserved