

CASE REPORT

A case of keratitis caused by *Scedosporium apiospermum*

Asuman Özkan¹, Serdar Susever¹, Zayre Erturan¹, Meltem Uzun¹, Nilüfer Alparslan²,
Yasemin Öz³, Yıldız Yeğenoğlu¹

¹ Istanbul University, Istanbul Faculty of Medicine, Department of Medical Microbiology, Istanbul, Turkey

² Istanbul University, Istanbul Faculty of Medicine, Ophthalmology Clinic, Istanbul, Turkey

³ Osmangazi University, Faculty of Medicine, Department of Medical Microbiology, Eskisehir, Turkey

ABSTRACT

Dematiaceous fungi have been reported among the common etiologic agents of keratitis. We herein report a case of keratitis due to *Scedosporium apiospermum* identified by conventional methods and confirmed by molecular methods. A 68-year-old male who attended the Ophthalmology Clinic at Istanbul University, Faculty of Medicine Hospital, presented with pain, lacrimation and a 'foreign body' sensation in the left eye with six weeks duration. The samples which were taken from corneal tissue, contact lens and anterior chamber were inoculated on Sabouraud dextrose agar (SDA) and brain heart infusion (BHI) agar. On the third day of incubation, a phaeoid mold was observed on the plate which was inoculated with corneal tissue sample at 27°C. The strain was identified as *Scedosporium spp* with conventional methods and confirmed as *S. apiospermum* by a molecular method. Infection was successfully treated with voriconazole eyedrop (1%) after pre-diagnosis. Molecular diagnostic methods may be applied for the definitive diagnosis of the pathogen of fungal keratitis and the selection of the appropriate antifungal agent. *J Microbiol Infect Dis* 2013; 3(1): 45-48

Key words: *Scedosporium apiospermum*, fungal keratitis, phaeoid mold.

Scedosporium apiospermum'un neden olduğu bir keratit olgusu

ÖZET

Dematiyöz mantarlar keratit nedeni olarak sık saptanan etiyolojik etkenler arasında yer alır. Burada konvansiyonel yöntemlerle tanımlanan ve moleküler yöntemle doğrulanan *Scedosporium apiospermum*'un neden olduğu keratit olgusu sunuldu. Altmışsekiz yaşındaki bir erkek hasta İ.Ü. İstanbul Tıp Fakültesi Göz Hastalıkları kliniğine sol gözünde altı haftadır devam eden ağrı, batma, sulanma ve yabancı cisim hissi ile başvurdu. Hastadan alınan kornea, kontakt lens ve ön kamara örnekleri Sabouraud dextrose agar (SDA) ve beyin kalp infüzyon (BHI) agar besiyerlerine doğrudan ekim yapıldı. İnkübasyonun üçüncü gününde 27°C'de inkübe edilen korneal örneğin ekim yapıldığı besiyerlerinde feoid bir küf üremesi oldu. Suş konvansiyonel yöntemlerle *Scedosporium spp* olarak tanımlandı ve moleküler tanı yöntemi ile de *S. apiospermum* olarak doğrulandı. Olgu ön tanı aldığı üçüncü günden itibaren %1 vorikanazol göz damlası ile başarılı bir şekilde tedavi edildi. Fungal keratit olgularında doğru tanı ve uygun antifungal ajanın seçimi için moleküler yöntemler uygulanabilir.

Anahtar Kelimeler: *Scedosporium apiospermum*, fungal keratit, feoid küf.

INTRODUCTION

Fungal infections of the eye are recognized as an important cause of morbidity and blindness worldwide. Fungal keratitis is the most common encountered clinical entity. These infections represent one of the most difficult forms of microbial eye infections to diagnose and treat successfully. It is difficult to obtain correct diagnosis and topical antifungal preparations. Fungal eye infections have a highly varied etiology. *Dematiaceous* fungi are reported to be responsible for 10-15% of all fungal keratitis cases

and are the third most frequently encountered fungi following *Aspergillus* and *Fusarium*.^{1,2} *Scedosporium apiospermum* is a ubiquitous filamentous fungus and is found in soil, polluted water and decaying vegetable matter. Keratitis caused by the fungus is generally a result of trauma or ocular injury, produced by contaminated objects.²⁻⁴ *S. apiospermum* is a significant opportunistic agent with very high levels of antifungal resistance.⁵ We herein report a case of keratitis caused by *S. apiospermum* which was successfully treated with eye drops containing 1% of voriconazole.

Correspondence: Asuman Özkan, Istanbul University, Istanbul Faculty of Medicine, Dept. Medical Microbiology, Çapa, Istanbul, Turkey Email: asuman.ozkan@gmail.com

Received: 02.10.2012 Accepted: 08.11.2012

Copyright © Journal of Microbiology and Infectious Diseases 2013, All rights reserved

Case Description

A 68-year-old male attended the Ophthalmology Clinic at Istanbul University, Faculty of Medicine on July 25, 2011. He presented six weeks duration of pain, lacrimation and a 'foreign body' sensation in the left eye. His past medical history revealed a sustained trauma with dust of the left eye six weeks ago. The patient was neither immunocompromised nor diabetic, except for being contact lens user. The patient presented with a stromal infiltrate with feathery margins, of uncertain etiology, in the cornea and hypopyon. Clinical and microbiological samples for diagnostic procedures were taken from corneal tissue, contact lens and anterior chamber and inoculated on to Sabouraud dextrose agar (SDA) and brain heart infusion (BHI) agar by the ophthalmologist in the operating room on admission day. These plates were sent to the Micology Laboratory of the hospital and incubated at 27°C and 37°C. On the third day of incubation, a phaeoid mold was observed on the plate which was inoculated with corneal tissue sample at 27°C. No growth was detected on the remaining plates. The colony appearances of the fungus was dark olive-green to black and had a woolly surface (Figure 1). A direct microscopic preparation was performed with lactophenol cotton blue (LPCB) stain and pigmented fungal elements were observed. The hyphae of the fungus were septated and conidiophores were simple long or short. Conidia were singly and in some areas in small groups (Figure 2).

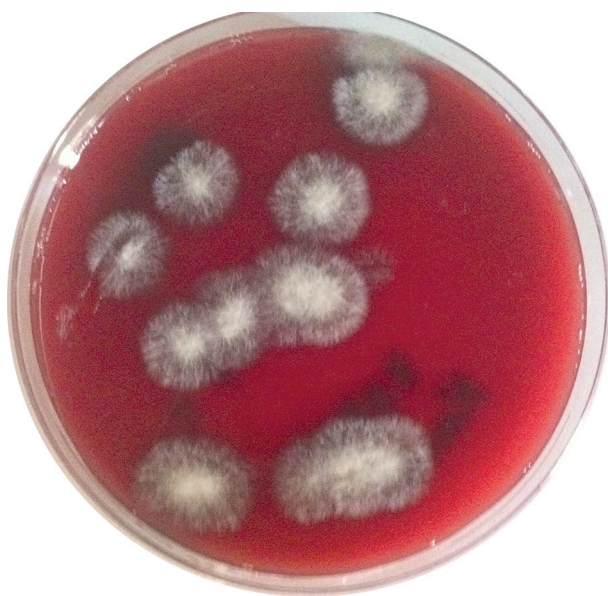

Figure 1. Colony morphology of *Scedosporium apiospermum* on brain heart infusion (BHI) agar

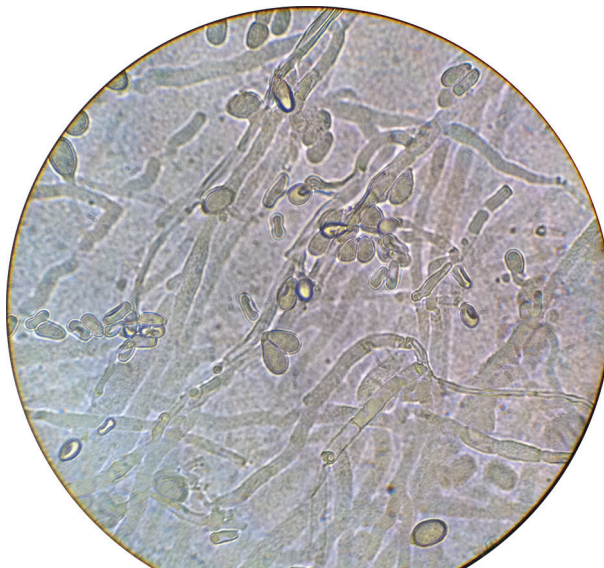


Figure 2. Microscopic appearance of *Scedosporium apiospermum* with lactophenol cotton blue (LPCB) stain

Final identification was made as *S. apiospermum* by PCR amplification of D1-D2 region of 28S rRNA gene and sequencing of the resulting amplicons. PCR amplification of fungal genomic DNA was achieved using the primers and conditions as described previously.⁶ Total size of resulting sequences was 538 bp and these sequences shared 100% identity with *S. apiospermum* strain ATCC 28206 18S ribosomal RNA gene present in the publicly available GenBank sequence database of the National Center for Biotechnology Information (NCBI). The patient was treated with voriconazole eye drops (1%) after pre-diagnosis and the regression of stromal infiltrate and disappearance of hypopyon was achieved.

DISCUSSION

The World Health Organisation (WHO) has recognized corneal blindness resulting from infectious keratitis as an important cause of worldwide visual disability.² *S. apiospermum* which was previously thought to be an asexual state of *Pseudoallescheria boydii*, is now classified as a separate species in a clade other than that of *P. boydii*. *S. apiospermum* appears to be the most commonly encountered species of the *P. boydii* complex.⁷ Although the virulence of *S. apiospermum* is low, it has been identified as the causative agent of many infections in humans (keratomycosis, endophthalmitis, meningitis, brain abscesses, endocarditis, pulmonary in-

fections, peritonitis, localized skin infections) whose severity and prognosis depends on the patient's immune status.³ This fungus is a saprophytic mold which can be isolated from environmental sources (e.g. soil, polluted water and decaying vegetable) and eye trauma is the most important risk factor for mycotic keratitis, reported in 44-55% of affected patients.^{2,8}

S. apiospermum is an uncommon cause of keratitis. In a study which investigated 150 cases of corneal ulcers during 1980-1982, only one out of 68 mycotic keratitis cases was caused by the fungus.⁹ Similarly, in a review which investigated 125 fungal keratitis cases in south Florida, the only one case (0.8%) was reported to be caused by this fungus over a 10-year period.¹⁰ In another study in northern India in which 730 cases of corneal ulcers were investigated, only one (0.14%) out of 61 fungal cases was caused by *S. apiospermum*. Wu et al³, described two new cases of keratitis caused by *S. apiospermum* and reviewed 26 other cases. The investigators reported that most cases of keratitis caused by this fungus were developed after corneal trauma by objects contaminated by vegetable matter.³

In Turkey, infections with *S. apiospermum* are rarely encountered and a few cases including mycetomas, arthritis, lymphadenitis, skin, eye, bone and soft tissue infections were reported.¹¹ A total of four oculomycosis (one chorioretinitis, two keratitis and one nonspecified) cases caused by *S. apiospermum* were reported from Turkey so far.¹¹⁻¹³ Direkel et al.¹⁴ investigated^{6,7} 42 various clinical specimens from hospitalized patients at critical units. In that study, although filamentous fungi were isolated from 71 (1.05%) samples only one isolate that was obtained from corneal specimen was identified as *Scedosporium spp.*

Fungal keratitis is associated with greater morbidity than that bacterial counterpart, since diagnosis is often delayed and available drugs are not always effective.¹⁵ Therapeutic success in cases of fungal infections of the eye depends on early diagnosis of infections, the correct identification of the etiologic agent and appropriate antifungal therapy. The selection of antifungals for the treatment of *S. apiospermum* infection is important, because this fungus has been reported to be resistant to many antifungals. Since there is no ideal antimycotic drug (i.e. non-toxic, fungicidal and with corneal penetration) the choice is often based on clinical response. *S. apiospermum* displays variable sensitivity to amphotericin B. Antifungal azoles are often cited as the agent of choice for infections due to *S. apiospermum*.

Although used successfully to treat *S. apiospermum* infections, voriconazole was reported to be less effective against *Scedosporium prolificans*, another species of *Scedosporium*.^{15,16}

In conclusion, a prompt diagnosis and treatment of fungal keratitis is essential and molecular diagnostic methods may be applied for the definitive diagnosis of the pathogen and the selection of the appropriate antifungal agent.

Acknowledgement

The authors reported no conflict of interest and no funding was received on this work.

REFERENCES

1. Wilhelmus KR, Jones DB. *Curvularia* keratitis. *Tr Am Ophth Soc* 2001;99:111-132.
2. Javey G, Zuravleff JJ, Yu VL. Fungal infections of the eye. In: Anaissie EJ, Mc Ginnis MR, Pfaller MA's *Clinical Mycology*, 2nd edn. Philadelphia: Churchill Livingstone Press, 2009:623-641.
3. Prats CH, Tello FL, San Jose AB, Otaolaumuchi JS, Baines JPO. Voriconazole in fungal keratitis caused by *Scedosporium apiospermum*. *Ann Pharmacother* 2004;38:414-417.
4. İrkeç M, Bozkurt B. Göz Enfeksiyonları. In: Topçu AW, Söyletir G, Doğanay M. eds. *Enfeksiyon Hastalıkları ve Mikrobiyolojisi*, 3rd edn. İstanbul: Nobel Tıp Kitabevleri: 2008:1583-1596. (In Turkish)
5. Guarro J, Kantarcioğlu AS, Horre R, et al. *Scedosporium apiospermum*: changing clinical spectrum of therapy-refractory opportunist. *Med Mycol* 2006;44:295-327.
6. Hinrikson HP, Hurst SF, Lott TJ, Warnock DW, Morrison CJ. Assessment of ribosomal large-subunit D1-D2, internal transcribed spacer 1 and internal transcribed spacer 2 regions as targets for molecular identification of medically important *Aspergillus* species. *J Clin Microbiol* 2005;43:2092-2103.
7. Larone Dh. *Medically Important Fungi*, 5th edn. Washington: ASM Press, 2011:208-213.
8. Husain S, Munoz P, Forrest G, et al. Infections due to *Scedosporium apiospermum* and *Scedosporium prolificans* in transplant recipients: Clinical characteristics and impact of antifungal agent therapy on outcome. *Clin Infect Dis* 2005;40:89-99.
9. Sundaram BM, Badrinath S, Subramanian S. Studies on mycotic keratitis. *Mycoses* 1989;32:568-572.
10. Rosa RH J, Miller D, Alfonso EC. The changing spectrum of fungal keratitis in South Florida. *Ophthalmology* 1994;101:1005-1013.
11. Kantarcioğlu SA, Yücel A. Pseudallescheriasis cases identified at Department of Microbiology and Clinical Microbiology, Cerrahpaşa Medical Faculty and European Confederation of Medical Mycology (ECMM) Pseudallescheriasis Study Group. *Cerrahpaşa J Med* 2005;36:90-96.
12. Yücel A. *Scedosporium apiospermum* (Monosporium apiospermum)'dan ileri gelen bir göz mikozu. *Türk Mikrobiyol Cem Derg* 1989; 19:25-29. (In Turkish)
13. Erdem Ü, Bağkesen H, Durukan AH, Saraçlı MA, Hürmeriç V, Bayraktar MZ. Total korneal erime ile seyreden mantar keratitli bir olgunun klinik izlemi. *Gülhane Tıp Dergisi* 2005;47:135-139. (In Turkish)

14. Direkel S, Otağ F, Aslan G, Ulger M, Emekdaş G. Identification of filamentous fungi isolated from clinical samples by two different methods and their susceptibility results. *Mikrobiyol Bul* 2012;46:65-78. (In Turkish)
15. Sicilia MJL, Lacomba MS, Cuesta FS, Pedraza RS, Gomez TN, Roman MC. *Scedosporium apiospermum* keratitis. *Rev Iberoam Micol* 2003;20:68-70.
16. Ozdemir HG, Oz Y, Ilkit M, Kiraz N. Antifungal susceptibility of ocular fungal pathogens recovered from around the world against itraconazole, voriconazole, amphotericin B, and caspofungin. *Med Mycol* 2012;50:130-135.