

CASE REPORT

Invasive orbital aspergillosis in an apparently immunocompetent host without evidence of sinusitis

Jennifer Primeggia¹, George Cyriac², Princy Kumar¹

¹ Department of Internal Medicine, ²Division of Infectious Diseases, Georgetown University Hospital, 3800 Reservoir Rd NW, Washington DC, 20007, USA

ABSTRACT

Invasive aspergillosis is uncommon in healthy individuals. We report a case of *Aspergillus fumigatus* orbital cellulitis with intracranial extension in an apparently immunocompetent patient with a history of benign lymphoid hyperplasia of the lacrimal gland. A 68 year-old man with no significant past medical history underwent orbitotomy and biopsy of a lacrimal gland mass. Pathology showed benign lymphoid hyperplasia of the lacrimal gland and he completed radiation therapy. Three months after orbitotomy and one month after completion of radiation therapy, he presented with orbital cellulitis. Brain magnetic resonance imaging demonstrated invasion into the frontal lobe. Clinical and radiographic findings failed to improve with prolonged antibiotic therapy; transcranial orbitotomy with right frontal craniotomy for abscess drainage and orbit washout was performed. Intraoperative cultures grew *Aspergillus fumigatus*. The patient completed a six month course of therapy with oral voriconazole and has remained free from relapse with long-term follow-up. Efficacy of voriconazole was guided by serial imaging and voriconazole trough levels. *Aspergillus* may cause invasive disease in immunocompetent hosts, even without evidence of sinusitis, and should be considered in the differential diagnosis when patients do not demonstrate clinical improvement with antibiotic therapy. *J Microbiol Infect Dis* 2012; 2(3): 113-116

Key words: Aspergillosis, orbital cellulitis, brain abscess

Görünüşte immüitesi sağlam olan bir konakta sinüzit bulgusu olmadan invaziv orbital aspergilloz

ÖZET

İnvaziv aspergilloz sağlıklı bireylerde pek görülmez. Burada, görünüşte immüitesi sağlam bir konakta gelişen, lakrimal bezin benign lenfoid hiperplazi hikayesi bulunan, kafa içi tutulumun eşlik ettiği bir *Aspergillus fumigatus* orbital sellülit vakasını sunduk. Daha önceden önemli bir sağlık problemi olmayan 68 yaşındaki erkek hastaya orbitotomi ve lakrimal bez kitle biyopsisi yapıldı. Patoloji lakrimal bezin benign lenfoid hiperplazisi olduğunu gösterdi ve radyasyon tedavisi uygulandı. Hasta, orbitotomiden üç ay ve radyasyon tedavisinin tamamlanmasından bir ay sonra, orbital sellülit ile başvurdu. Beyin manyetik rezonans görüntülemesi frontal lob içine invazyon olduğunu gösterdi. Uzun süreli antibiyotik tedavisi ile klinik ve radyolojik bulgularda iyileşme olmadı, abse drenajı için sağ frontal kraniyotomi ile transkraniyal orbitotomi ve orbita yıkaması yapıldı. Operasyonda alınan kültürde *Aspergillus fumigatus* üredi. Hasta altı aylık vorikonazol tedavi sürecini tamamladı ve uzun süreli takiplerinde relaps olmadı. Vorikonazolun etkinliği seri görüntülemeler ve vorikonazol düzeyinin ölçülmesi ile takip edildi. *Aspergillus*, immüitesi sağlam kişilerde sinüzit belirtisi olmadan da invaziv hastalık yapabilir ve antibiyotik tedavisine rağmen klinik iyileşme göstermeyen hastalarda ayırıcı tanıda akılda tutulmalıdır.

Anahtar Kelimeler: Aspergilloz, orbital sellülit, beyin apsesi

INTRODUCTION

Aspergillus species are ubiquitous molds found throughout the environment. Invasive disease is relatively uncommon and is more typically observed in immunocompromised patients.¹ We

report a case of *Aspergillus fumigatus* orbital cellulitis with intracranial extension in an apparently immunocompetent patient who underwent orbitotomy followed by radiation therapy for benign lymphoid hyperplasia of the lacrimal gland prior to presentation.

Correspondence: Jennifer Primeggia, MD, 5-Pasquerilla Healthcare Center

3800 Reservoir Rd NW Washington DC, 20007 USA 202-444-0126 (office) 1-877-665-8072 (fax) Email: jxprime@gmail.com

Received: 08 May, 2012 Accepted: 02 August, 2012

Copyright © Journal of Microbiology and Infectious Diseases 2012, All rights reserved

Case Description

A 68-yr-old South Asian male with no significant past medical history presented with proptosis to his ophthalmologist. He reported subacute onset of pain and edema of his right orbit of four months duration. An MRI at this time revealed an infiltrative mass of the right orbit. The patient underwent right orbitotomy and was found to have an infiltrating mass of the lacrimal gland. Biopsy revealed benign lymphoid hyperplasia and the patient underwent radiation therapy.

Three months after orbitotomy, and one month after completing radiation therapy, he presented to his ophthalmologist with pain, swelling, and erythema of the right orbit consistent with orbital cellulitis. He received 10 days each of cephalexin, then amoxicillin/clavulanate without clinical improvement. MRI of the brain and orbit revealed new soft tissue swelling laterally and dural thickening of the right frontal lobe with a 1 cm ring-like

cavitated lesion at the inferior surface; there was no evidence of sinus disease. Upon hospitalization, edema and erythema from the orbit to the zygomatic process was noted. Visual acuity without correction was 20/60 OD, 20/50 OS. There was downward displacement of the right globe, but extraocular movements were intact with no afferent pupillary defect. The patient was non-toxic and afebrile. Leukocyte count was 8,200/ μ L (74% neutrophils). As the patient was apparently immunocompetent, with no history of HIV, malignancy, diabetes mellitus, or immunosuppression, empiric intravenous vancomycin and ceftriaxone were initiated. This regimen resulted in a decrease in edema and erythema. Repeat MRI on hospital day 4 demonstrated an enhancing lesion of the right orbit, continuous through the orbital roof, and a right frontal ring-enhancing lesion of stable size with surrounding vasogenic edema (Figure 1 A, B). The patient was discharged on hospital day 6 to complete 4 weeks of antibiotics.

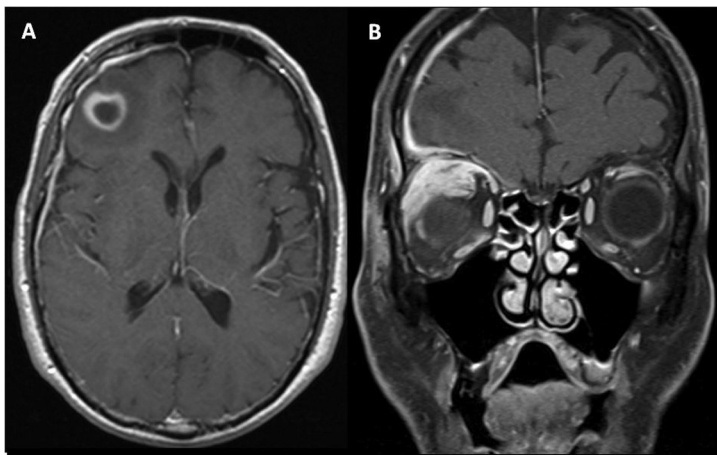


Figure 1. T1-weighted post-contrast magnetic resonance imaging brain. A. Axial image demonstrating ring enhancing lesion in the frontal lobe. B. Coronal image of the orbit demonstrating orbital cellulitis.

Seven days later, follow-up MRI revealed interval enlargement of the ring-enhancing mass, now 2.3 cm. The mass remained continuous with the enhancing phlegmonous right orbital cellulitis. The patient was afebrile and the leukocyte count was 7,200/ μ L (75% neutrophils). Cellulitis and visual deficits were stable. Given disease progression, ceftriaxone was switched empirically to meropenem and he underwent transcranial orbitotomy with right frontal craniotomy for abscess drainage and orbit washout. Intraoperative findings included orbital roof erosion in the intracranial space with inflamed orbital issue, without frank purulence. Purulent material from the frontal lobe abscess cavity was sent for culture. Gram stain

was negative but cultures identified mold on post-operative day 2.

Liposomal amphotericin B (5 mg/kg intravenous daily) was initiated. Pathology from skull-base lesion biopsies identified *Aspergillus* species (Figure 2 A, B), which then grew *Aspergillus fumigatus*. All antibiotics were discontinued. He was transitioned to oral voriconazole monotherapy 300 mg twice daily and improved clinically. A voriconazole trough prior to discharge was 2 mcg/mL (target 1-5.5 mcg/mL), indicating oral absorption. He completed 6 months of therapy with no recurrence of disease with long-term follow-up (Figure 3).

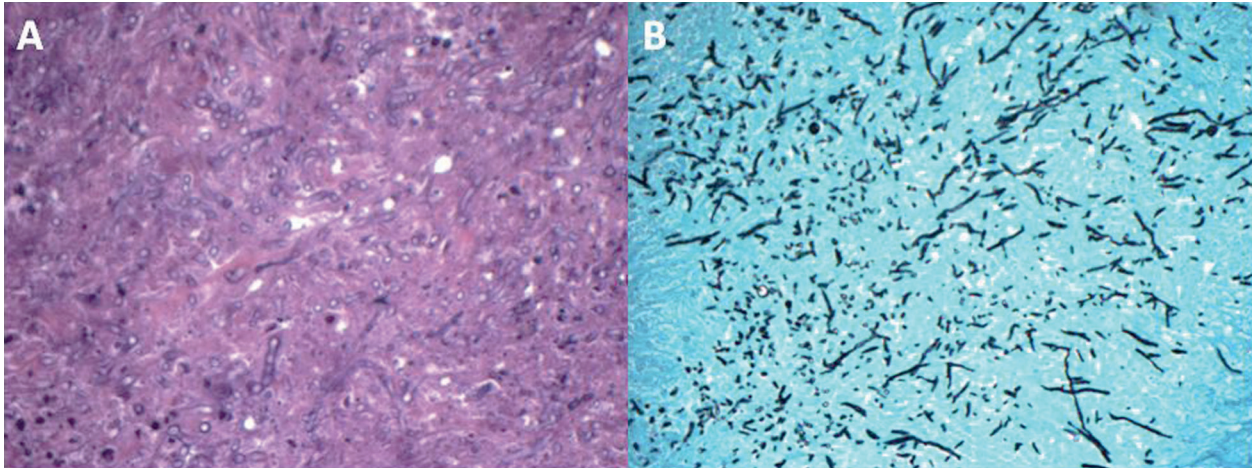


Figure 2. Histology from dural section. Periodic acid-Schiff stain (A) and Gomori methenamine silver stain (original magnification 40X) (B) demonstrating uniform branching septated hyphae diagnostic of *Aspergillus* species.

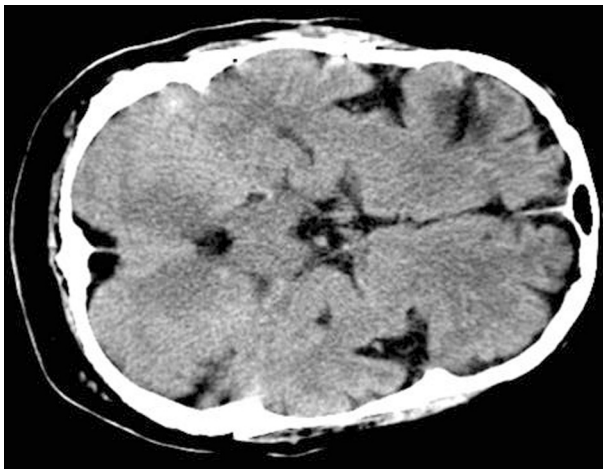


Figure 3: 6-month follow-up axial CT of the brain. Non-contrast-enhanced image demonstrates a small area of encephalomalacia in the right inferior frontal lobe and no evidence of recurrent brain abscess.

DISCUSSION

Orbital cellulitis may be observed from extension of infection from periorbital structures, direct inoculation of the orbit, trauma or surgery, or haematogenous spread. Predisposing factors to both preseptal and orbital cellulitis include ocular conditions, such as dacryocystitis, dacryoadenitis, endophthalmitis and conjunctivitis.² As respiratory epithelial cells act as an anatomic barrier to invasion by *aspergillus* and promote mucociliary clearance, so too does the lacrimal duct function in host defense.³ The lacrimal gland not only protects the ocular surface via a tear film, but also supplies the ocular surface with protective immu-

noglobulins.⁴ Orbital and preseptal cellulitis may develop as a result of nasolacrimal duct dysfunction, as this may lead to the proliferation of organisms in stagnant fluid of the lacrimal sac and may impair the clearance of pathogens.⁵ Involvement of the lacrimal sac by *aspergillus* is uncommon. In a review of 350 dacryocystorhinostomies by one surgeon, there was 1 case of *aspergillus* infection that was incidentally discovered on pathological examination.⁶

Orbital lymphoid hyperplasia is part of a continuous spectrum of lymphoproliferative disease: benign (reactive) lymphoid hyperplasia, atypical lymphoid hyperplasia, and malignant non-Hodgkin's Lymphoma (NHL).⁷ It may also be associated with systemic malignant lymphomas. Because of the high risk of NHL, systemic staging for all orbital lymphoid tumors is recommended.⁷ Irradiation is the mainstay of treatment.⁸ Side effects of therapy include cataract, minor retinopathy and corneal ulceration but association with fungal infection has not been reported.⁹

Classical risk factors for invasive aspergillosis include: prolonged neutropenia, hematopoietic stem-cell and solid organ transplantation, advanced acquired immunodeficiency syndrome and chronic granulomatous disease.¹ The incidence of invasive aspergillosis in patients with hematologic malignancies has been reported to be as high as 3.1%, with *A. fumigatus* representing the most commonly isolated species.^{10,11} The incidence of invasive aspergillosis is highest among patients with acute myeloid leukemia (1.9%), followed by those with acute lymphoblastic leukemia

(1.3%).¹⁰ In comparison, the incidence of invasive aspergillosis among patients with NHL was 0.8% in one series.¹¹ While once not considered an at risk population, the incidence of invasive aspergillosis among those with aggressive NHL and multiple myeloma has increased over time due to the use of intensive chemotherapy.^{12,13} In a review of 38 cases of invasive aspergillosis among patients with multiple myeloma over a 12 year period, 26% of the cases were reported from 1984-1991 while 74% of cases were reported from 1992 and 1996.¹³

Invasive aspergillosis in an immunocompetent host is a rare phenomena, and in one large case series accounted for less than 10% of all cases.¹⁴ When identified in immunocompetent patients, it is more commonly described in the setting of sinusitis or underlying pulmonary disease and *Aspergillus flavus* is the most commonly identified species.¹⁵ Across the board, invasive aspergillosis in apparently immunocompetent hosts has resulted in poor outcomes, with 59% of patients demonstrating either therapy failure or death.¹⁵ In immunocompetent patients with CNS involvement of sinonasal aspergillosis, the mortality rate has ranged between 25% and 66.7% in one case series, though this was prior to the advent of voriconazole.¹⁶ Voriconazole has proven more efficacious in the treatment of fungal CNS infections recently.¹⁷ For patients without hematologic malignancy or hematopoietic stem cell transplantation, response rates were as high as 72% to CNS fungal infections, the majority of which were attributable to *Aspergillus* species.¹⁷ Our patient was treated successfully with oral voriconazole at a dose of 300 mg twice daily, guided by measurements of trough blood levels with a therapeutic target range of 1 mg/L to 5.5 mg/L.

CONCLUSION

In summary, there have been few published reports of invasive orbital aspergillosis in immunocompetent patients who do not demonstrate sinusitis. Accurate diagnosis of *Aspergillus* can significantly impact the management and clinical outcomes in these patients. Orbital aspergillosis is uncommon in immunocompetent patients, but should be considered in the differential diagnosis

when patients do not improve with empiric antibiotic therapy.

Disclosures

We have no financial disclosures to report.

REFERENCES

1. Segal BH, Walsh TJ. Current approaches to diagnosis and treatment of invasive aspergillosis. *Am J Respir Crit Care Med* 2006; 173:707-717.
2. Liu IT, Kao SC, Wang AG, Tsai CC, Liang CK, Hsu WM. Preseptal and orbital cellulitis: a 10-year review of hospitalized patients. *J Chin Med Assoc* 2006; 69:415-422.
3. Segal BH. Aspergillosis. *N Eng J Med* 2009;360:1870-1884.
4. Knop E and Knop N. The role of eye-associated lymphoid tissue in corneal immune protection. *J Anat* 2005; 206:271-285.
5. Carlisle RT, Fredrick GT. Preseptal and orbital cellulitis. *Hospital Physician* 2006; 42:15-19.
6. Levin LA, Avery R, Shore JW, Woog JJ, Baker AS. The spectrum of orbital aspergillosis: a clinicopathological review. *Surv Ophthalmol* 1996; 41:142-154.
7. Polito E, Leiccotti A. Prognosis of orbital lymphoid hyperplasia. *Graefes Arch Clin Exp Ophthalmol* 1996; 234:150-154.
8. Kennerdell JS, Flores NE, Hartsock RJ. Low-dose radiotherapy for lymphoid lesions of the orbit and ocular adnexa. *Ophthalm Plast Reconstr Surg* 1999; 15:129-133.
9. De Cicco L, Cella L, Liuzzi R, Solla R, Farella A, Punzo G, et al. Radiation therapy in primary orbital lymphoma: a single institution retrospective analysis. *Radiat Oncol* 2009; 4:60.
10. Nicolle MC, Benet T, Thiebaut A, et al. Invasive aspergillosis in patients with hematologic malignancies: incidence and description of 127 cases enrolled in a single institution prospective survey from 2004 to 2009. *Haematologica* 2011; 96:1685-1691.
11. Pagano L, Caira M, Candoni A, et al. The epidemiology of fungal infections in patients with hematologic malignancies: the SEIFEM-2004 study. *Haematologica* 2006; 91:1068-1075.
12. Herbrecht R, Moghaddam A, Mahmal L, Natarajan-Ame S, Fornecker LM, Letscher-Bru V. Invasive aspergillosis in the hematologic and immunologic patient: new findings and key questions in leukemia. *Med Mycol* 2005; 43:S239-S242.
13. Lortholary O, Ascoglu S, Moreau P, et al. Invasive aspergillosis as an opportunistic infection in nonallografted patients with multiple myeloma: a European organization for research and treatment of cancer. *Clin Infect Dis* 2000; 30:41-46.
14. Perfect JR, Cox GM, Lee JY, et al. The impact of culture isolation of aspergillus species: a hospital-based survey of aspergillosis 2001; 33:1824-1833.
15. Clancy CJ, Nguyen MH. Invasive sinus aspergillosis in apparently immunocompetent hosts. *J Infect* 1998; 37:229-240.
16. Siddiqui AA, Shah AA, Bashir SH. Craniocerebral aspergillosis of sinonasal origin in immunocompetent patients: clinical spectrum and outcome in 25 cases. *Neurosurgery*; 2004; 55:602-611.
17. Schwartz S, Reisman A, Troke PF. The efficacy of voriconazole treatment of 192 fungal central nervous system infections: a retrospective analysis. *Infection* 2011; 39:201-210.