

CASE REPORT

Development of miliary tuberculosis during the course of adult-onset Still's disease: Case report

Murat Turgay¹, Halil Kurt², Ali Şahin¹, Orhan Küçükşahin¹

¹Rheumatology Department, Ankara University, School of Medicine, Ankara, Turkey

²Clinical Bacteriology and Infectious Diseases Department, Ankara University, School of Medicine, Ankara, Turkey

ABSTRACT

Adult-onset Still's disease (AOSD) is a rare systemic inflammatory disease with unknown etiology. Here, a 30-year-old man who developed miliary tuberculosis during the course of AOSD was presented due to very rare coincidence of these two diseases. The diagnosis of miliary tuberculosis was documented by bone marrow biopsy and culture. The patient's clinical findings improved with anti-tuberculosis treatment and steroids. *J Microbiol Infect Dis 2011;1(1):38-41.*

Key words: Adult-onset Still's disease, bone marrow examination, miliary tuberculosis.

Erişkin Still hastalığı seyrinde miliyer tüberküloz gelişimi: Olgu sunumu

ÖZET

Erişkin Still hastalığı, etyolojisi bilinmeyen nadir görülen inflamatuvar bir hastalıktır. Bu makalede, Erişkin Still hastalığı seyrinde miliyer tüberküloz gelişen 30 yaşında erkek hasta bu iki hastalığın nadir birlikteliği nedeniyle sunuldu. Hastada miliyer tüberküloz tanısı kemik iliği biyopsisi ve kültür ile doğrulandı. Hastanın klinik bulguları, birlikte yapılan anti-tüberküloz tedavi ve steroid tedavisi ile düzeldi.

Anahtar kelimeler: Erişkin Still Hastalığı, kemik iliği incelemesi, miliyer tüberküloz.

INTRODUCTION

Adult-onset Still's disease (AOSD) presents similar clinical and laboratory features with acute-onset systemic form of juvenile chronic arthritis, and occurs frequently among patients older than 16 years. The mean age for onset is 30 years and a man to women ratio is 1:1 in AOSD. The clinical manifestations are fever (exceeding 39-40°C for two times a day), sore throat, arthralgia, maculopapular rashes, lymphadenopathy, hepato-splenomegaly and serositis. The laboratory findings are leukocytosis, increased ferritin levels; elevated erythrocyte sedimentation rate (ESR), C-reactive protein (CRP), and liver function tests. However, rheumatoid factor (RF) and antinuclear antibody (ANA) are negative in this disease.^{1,2} The differential diagnosis is made with infectious diseases, malignancies, and other connective tissue diseases.

Miliary tuberculosis caused by the spread of plenty of tuberculosis bacilli via bloodstream, and

forms 1% of all tuberculosis cases.³ Radiological modalities (posteroanterior [PA] chest X-Ray, thorax high resolution computed tomography [HRCT]), microbiological methods such as Ziehl-Nelson staining, culture and histopathological diagnostic methods can be used as current diagnostic approach. We herein present a case that miliary tuberculosis developed during the course of AOSD since association of these two diseases in the same patient is very rare.

CASE

A 30-year-old man was consulted to Outpatient Infectious Diseases Clinics with the symptoms of weight loss and high fever lasting for three weeks. In his medical history, he has chronic renal failure (CRF) for eight years and has underwent hemodialysis for two years. His complains were fever, sore throat and maculopapular rashes seen during the fever and disappear when body temperature returned to normal. The laboratory examinations

Correspondence: Dr. Ali Sahin

Ankara University, School of Medicine, Rheumatology Department, Sıhhiye, Ankara, Türkiye Email: dralsahin@hotmail.com

Received: 28.05.2011, Accepted: 30.06.2011

Copyright © Journal of Microbiology and Infectious Diseases 2011, All rights reserved

revealed leukocytosis and increased ferritin level (5,584 ng/mL). He was diagnosed as AOSD according to Yamaguchi criteria.⁴ The other causes of fever were excluded and 40 mg/kg/d methylprednisolone was started. At this time, thorax CT was found as normal. Fever, maculopapular rashes and laboratory findings recovered. However, at approximately 45th day of steroid treatment, he was hospitalized in the Department of Infectious Diseases due to weight loss and recurrent fever. In the physical examination, mucous membranes were found pale, body temperature was 39°C. The breathing sounds were diminished on left basal lung segments. The other systemic examinations were normal.

In the laboratory tests; leukocyte count was 7,000/mm³ (neutrophils 3,000/mm³, lymphocytes 2,000/mm³), platelets count 22,000/mm³, hemoglobin 7.2 g/dL, ESR 113 mm/h, CRP 83.9 mg/L, serum creatinine 3.79 mg/dL, aspartate amino transferase (AST) 9 IU/L, alanine amino transferase (ALT) 10 IU/L. Rheumatoid factor and ANA were negative. Posterior-Anterior chest X-Ray revealed that closed left costophrenic sinus, indistinct contours of hemidiaphragma and homogenous density with open side facing upward. In the thorax CT, conglomerate lymphadenopathies with central necrotic regions located in mediastinal and hilar region, pleural fluid on left side, ground-glass appearance at upper zone and mid-zone of right lung were determined (Figure 1). Due to presence of pancytopenia and fever, bone marrow biopsy was performed for excluding haematological malignancies and hemophagocytic syndrome. It was reported that granulomatous inflammation characterized by fibrinoid necrosis (Figure 2). QuantiFERON®-TB GOLD test was positive. Miliary tuberculosis was diagnosed based on clinical, radiological and cytological findings.

The corticosteroid therapy was stopped. Anti-tuberculosis treatment with four drugs (isoniazid 300 mg/d after dialysis, rifampicin 600 mg/ everyday, ethambutol 1000 mg/d 4 hours before dialysis, pyrazinamid 2000 mg/d 24 hours before dialysis) was administered. On follow-up, it was determined that fever persisted at the 15th day of antituberculosis therapy, pleural fluid at PA chest X-ray increased, and the level of ferritin was 36,691 ng/mL. The activation of AOSD was considered and 0.5 mg/kg/d methylprednisolone therapy was restarted. Together with the

anti-tuberculosis and steroid treatment, fever was handled, and pancytopenia recovered. At the 43rd day of the treatment, *Mycobacterium tuberculosis* was grown in culture of bone marrow aspirate. At the 2nd month of the therapy, control PA chest X-ray revealed that pleural fluid almost recovered. In susceptibility tests, *M.tuberculosis* was found to be susceptible to rifampisin and isoniazid. At the third month of antituberculosis medication, ethambutol and pyrazinamide were stopped and treatment with rifampicin and isoniazid was continued up to 12 months. Control thorax tomography showed that mediastinal and hilar lymph nodes became smaller and calcified (Figure 3). Anti-tuberculosis therapy is considered to last for at least 12 months.

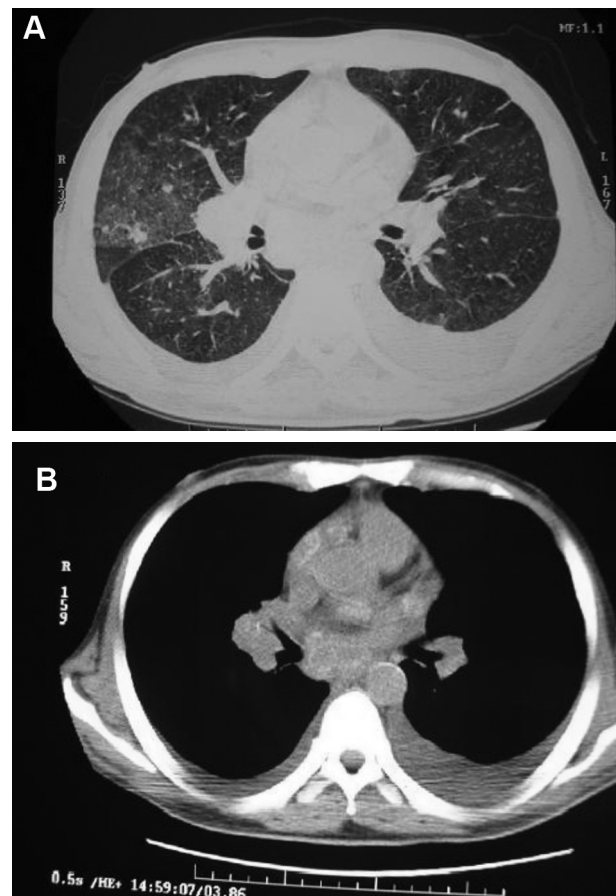


Figure 1. Thorax computed tomography (CT) showing ground-glass appearance at upper zone and mid-zone of right lung (A), conglomerate lymphadenopathy with central necrotic areas located in mediastinal and hilar region, pleural fluid on left side (B).

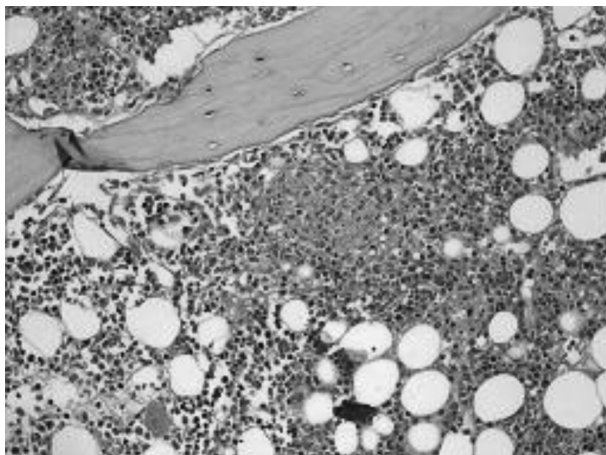


Figure 2. Bone marrow biopsy histopathological examination showing granulomatous inflammation characterized by fibrinoid necrosis (black arrow) (100 x H&E).

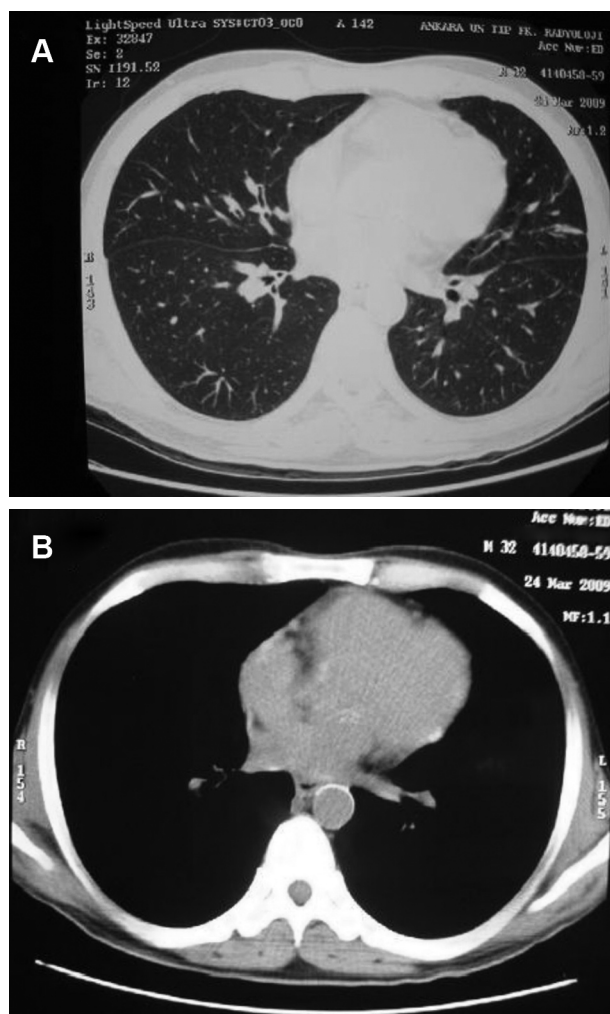


Figure 3. Control thorax CT showing that ground-glass appearance at upper zone and mid-zone of right lung vanished (A). Mediastinal, hilar lymph nodes became smaller and calcified (B).

DISCUSSION

Although pulmonary involvement is not common in AOSD, pneumonia and pleural effusion has been identified.⁴ The clinical and radiological findings of pulmonary involvement are nonspecific and infectious-like.^{5,6} In our case, pleural effusion on PA chest X-ray was determined on the course of AOSD. Histiocytic hyperactivity or hemophagocytic syndrome should be kept in mind in patients especially with high levels of ferritin.⁷ If leukopenia and thrombocytopenia develops on the course of AOSD, the risk of hemophagocytic syndrome should be evaluated.⁸ The present patient, although high levels of ferritin and pancytopenia were present, bone marrow biopsy was compatible with tuberculosis.

Miliary tuberculosis usually occurs as a form of progressive primary disease due to defects in immune system. The incidence of active tuberculosis is 6-16% higher in patients with chronic renal disease and undergoing hemodialysis responsible for impaired immune response.⁹⁻¹³ It was suggested that the incidence of tuberculosis in patients with CRF was found 23.6% in Turkey.¹⁴ The reason of higher incidence of tuberculosis among hemodialysis patients could be the progression of latent tuberculosis to active disease due to impaired cellular immunity.¹⁵ The risk of development of active tuberculosis increases for one fifth times during the use of systemic corticosteroid treatment. Our case was undergoing hemodialysis due to chronic renal failure for two years and he was immunosuppressive because of corticosteroid for AOSD. The miliary tuberculosis in this case was defined as activation of latent tuberculosis due to impaired immune system. The presence of latent tuberculosis was proved by the positive serum QuantiFERON®-Tb GOLD test.

Multiple organ involvement is present in miliary tuberculosis. Fever, night sweating, weight loss, lack of appetite are more prominent symptoms because of systemic involvement. It is a very important cause of fever of unknown origin. In our case, the main initial presenting symptom was recurrent fever exceeding 39-40°C. Although hematological changes such as leukopenia, anemia, monocytosis, leukomoid like reaction, it might be found that thrombocytopenia, agranulocytosis and pancytopenia are seen in miliary tuberculosis. Pancytopenia is rare, whereas leukopenia and thrombocytopenia are seen more commonly.

The presence of fever and weight loss together with pancytopenia suggests miliary tuberculosis. The effect of hematological changes on prognosis has been unclear.¹⁶

The exact diagnosis of tuberculosis needs the presence of acido-resistant bacilli in body fluids and/or tissue samples or growth of bacilli on cultures. In the previous serials, the diagnostic value of bone marrow aspiration is approximately 50%.¹⁴ Pancytopenia was present in our case. Due to presence of weight loss, first of all, hematological malignancies were suspected and bone marrow biopsy was performed. However, *M.tuberculosis* was recovered in the culture of bone marrow biopsy and so the diagnosis was made. Because the levels of thrombocytes were under 10.000/mm³, therefore, bronchoscopic examination could not be performed.

The occurrence of pleural fluid in miliary tuberculosis is approximately 10-30%.¹⁶ The fluid sample that was obtained during thoraco-synthesis was hemorrhagic in appearance. ARB was found negative in pleural fluid. The level of ADA was found 41 U/L (nL 13.3-20.8 U/L). The cytological investigation of pleural fluid revealed that no lymphocyte predominance or no signs of malignancy.

It is very important that demonstration of granulomas in lung, liver and bone marrow samples. It has been showed that the prevalence of granulomas in liver or lung is 80%, whereas it is 50% in bone marrow.¹⁶ The importance of bone marrow biopsy is approximately 50% in diagnosis. The diagnosis of our case was set by growing of causative agent in bone marrow biopsy. If the active form of miliary tuberculosis is not treated immediately, it can be mortal. The duration of treatment is proposed for at least 9-12 months due to the presence of diffuse infective foci and high risk of central nervous system involvement without any signs. The combination of four drugs (isoniazid, rifampicin, pyrazinamide, and ethambutol) in anti-tuberculosis therapy should be administered; pyrazinamide and ethambutol should be stopped at the end of 2nd month. The treatment with isoniazid and rifampicin should be lasted for 9-12 months.¹⁶

In conclusion, tuberculosis should be checked in differential diagnosis of AOSD, especially it has been frequently observed in countries such as Turkey. PPD skin test, ARB in sputum, chest X-ray and QuantiFERON®-Tb GOLD test should be performed for scanning in all patients.

REFERENCES

1. Pouchot J, Sampalis JS, Beaudet F, et al. Adult-onset Still's disease: manifestations, disease course, and outcome in 62 patients. *Medicine (Baltimore)* 1991; 70:118-136.
2. Yamaguchi M, Ohta A, Tsunematsu T, et al. Preliminary criteria for classification of adult-onset Still's disease. *J Rheumatol* 1992; 19: 424-430.
3. Rieder HL, Snider DE, Cauthen GM. Extrapulmonary tuberculosis in the United State. *Am Rev Respir Dis* 1990; 141:347-351.
4. Cheema GS, Quismorio FP. Pulmonary involvement in adult-onset Still's disease. *Curr Opin Pulm Med* 1999; 5:305-309.
5. Biron C, Chambellan A, Agard C, Denis M, Germaud P, Hamidou MA. Acute respiratory failure revealing adult-onset Still's disease. Diagnostic value of low glycosylated ferritin level. *Clin Rheumatol* 2005; 25:766-768.
6. Ollivier Y, Dessan JF, Zoulim A, Leteller P. Legionellosis mimicking adult onset Still's disease. *Rev Med Intern* 2005;26:670-672.
7. Coffernils M, Soupart A, Pradier O, et al. Hyperferritinemia in adult onset Still's disease and the hemophagocytic syndrome. *J Rheumatol* 1992; 19:1425-7.
8. Ravelli A, Magni-Manzoni S, Pistorio A, et al. Preliminary diagnostic guidelines for macrophage activation syndrome complicating systemic juvenile idiopathic arthritis. *J Pediatr* 2005; 146:598-604.
9. Murthy BV, Pereira BJ. A 1990s perspective of hepatitis C, human immunodeficiency virus, and tuberculosis infection in dialysis patient. *Semin Nephrol* 1997;17: 346-363.
10. Sasaki S, Akiba T, Suenaga M, et al. Ten years survey of dialysis-associated tuberculosis. *Nephron* 1979; 24:141-145.
11. Belcon MC, Smith EK, Kahana LM, Shimizu AG. Tuberculosis in dialysis patient. *Clin Nephrol* 1982; 17:14-18.
12. Garcia-Leoni ME, Martin-Scapa C, Rodeno P, et al. High incidence of tuberculosis in renal patients. *Eur J Clin Microbiol Infect Dis* 1990;9:283-285.
13. Malhotra KK, Parashar MK, Sharma RK, et al. Tuberculosis in maintenance hemodialysis patients: study from an endemic area. *Postgrad Med J* 1981;57:492-498.
14. Cengiz K. Increased incidence of tuberculosis in patient undergoing hemodialysis. *Nephron* 1996; 73: 421-424.
15. Touraine JL, Touraine F, Revillard JP, et al. T-lymphocytes and serum inhibitors of cell-mediated immunity in renal insufficiency. *Nephron* 1975;14:195-208.
16. Maartens G, Willcox PA, Benatar SR. Miliary tuberculosis: rapid diagnosis, hematologic abnormalities, and outcome in 109 treated adult. *Am J Med* 1990; 89:291-296.