

The Patient with Ebstein's Anomaly of the Tricuspid Valve Underwent a New Surgical Repair Modified from Carpentier's Procedure



Mustafa Karaçelik¹, Cengiz Sert¹, Selim Özeç¹, Hakan Köksal¹, Yalçın Güvenli², Cengiz Özbek¹

¹Tepecik Research and Training Hospital, Clinic of Cardiovascular Surgery, İzmir, Turkey

²Tepecik Research and Training Hospital, Clinic of Anesthesiology, İzmir, Turkey

ABSTRACT

A new procedure for correction of Ebstein's anomaly that restores to near normal the anatomic and physiologic function of the tricuspid valve and the right ventricle is reported. Through a surgical approach, the displaced anterior leaflet was detached from the annulus. Most of the atrialized portion of the right ventricular wall was suspended; the tricuspid annulus was plicated anteromedially. The leaflet was then reattached to the native anterior annulus. Tricuspid valve was repaired using a 33 mm St. Jude ring. The patient was discharged from hospital uneventfully.

Key Words: Ebstein's anomaly; congenital; tricuspid valve disease

Ebstein Anomalisi Olan Bir Hastada Carpentier Yönteminden Modifiye Edilen Yeni Bir Cerrahi Onarım

ÖZET

Ebstein anomalisinin düzeltilmesinde, trikuspid kapak ve sağ ventrikülün normale yakın işlemesi için yeni bir yöntem bildirilmiştir. Cerrahi yaklaşım ile deplase ön leaflet, annulustan kesilip ayrıldı. Atrialize olmuş sağ ventrikülün çoğu kısmı asıldı. Trikuspid annulusun anteromedial kısmı plike edildi. Daha sonra, ön leaflet kendi anulusuna tekrar dikildi. Trikuspid kapak 33 mm St. Jude ring ile onarıldı. Hasta sorunsuz olarak hastaneden taburcu edildi.

Anahtar Kelimeler: Ebstein anomalisi; konjenital; trikuspid kapak hastalığı

INTRODUCTION

As Ebstein's anomaly is a rare congenital malformation, most center's experience with this lesion is limited to a small number of patients accumulated over decades. Ebstein anomaly is a rare condition (1-5 per 200 000 live births and, 1% of all congenital heart defects)(1).

It often associates with left heart abnormalities involving the myocardium or valves. The most common finding is a myocardial anomaly resembling mild noncompaction, but the uncommon is the presence of hypertrophic cardiomyopathy.

CASE REPORT

We report a case of a patient had Ebstein disease type B, with a large atrialized component of the right ventricle, but the anterior leaflet moves freely, associated with severe tricuspid valve (TV) displacement, no cyanosis, increased cardiothoracic ratio,

severely impaired right ventricular function, and significant functional impairment in NYHA class 2-3 in a 22 year-old man.

Transthoracic echocardiography confirmed the tricuspid incompetence was severe in our patient preoperatively. Informed consent was obtained from patient and surgery was performed through median sternotomy (Figure 1) and under hypothermic (30°C) cardiopulmonary bypass (CPB). Our repair technique is as follows: The displaced anterior leaflet was detached from the annulus totally. Most of the atrialized portion of the ventricular wall was suspended with a 2-0 polyester sutures (Ethibond®) eight single suture supported by 8 mm Dacron® tube vascular graft externally (Figure 2, 3). Posterior leaflet of the tricuspid valve was plicated anteromedially with a 3-0 polypropylene suture (Prolene®). The anterior leaflet was then reattached to the native anterior annulus with a 4-0 polypropylene suture (Prolene®). Tricuspid valve was repaired using a 33 mm St. Jude ring (Figure

Correspondence

Mustafa Karaçelik

E-mail: mkaracelik@hotmail.com

Submitted: 31.05.2013

Accepted : 27.06.2013

©Copyright 2014 by Koşuyolu Heart Journal - Available on-line at www.kosuyolukalpdergisi.com

4). Thus, suture bicuspidization of the tricuspid valve and ring annuloplasty for repair of functional tricuspid regurgitation was done using complete posterior leaflet plication technique. The patent foramen ovale was closed with a 2-0 polyester suture (Ethibond®) running suture primarily. The septal leaflet was not hypoplastic and not necessitated creation of a new leaflet. The anterior and posterior leaflets were not fibrotic. The postoperative course was uneventful and the patient was discharged on fifth post-operative day. Early echocardiograms showed significant reduction of tricuspid insufficiency a central blood flow through the TV orifice and full coaptation of the leaflets, which differentiates

it from the Carpentier's monocusp format and right ventricular morphology restoration. Right ventricular functions were well and the functional class of the patient was in NYHA class 1 at the first month control. The patient did not need any cardiac medication. The echocardiographic findings showed the reduction in the heart size at the control.

DISCUSSION

Posterior annular plication without plication of the atrialized right ventricle and prophylactic cavopulmonary connection are additional surgical options for nonneonatal Ebstein's anomaly;

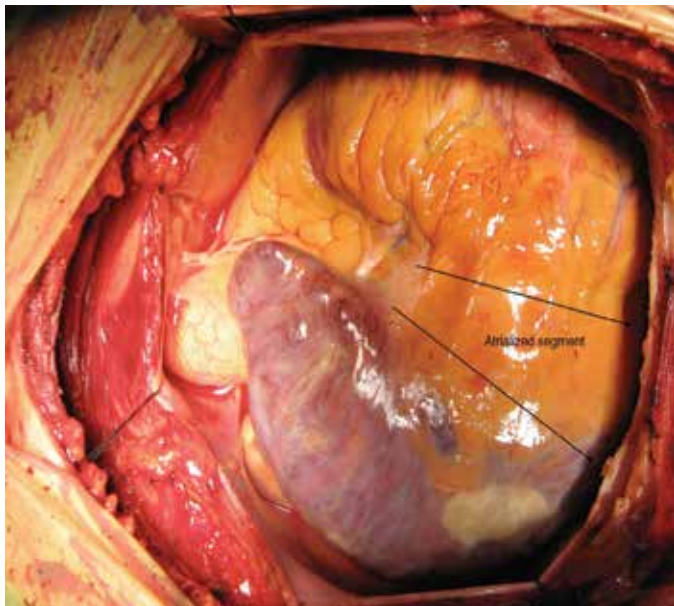


Figure 1. The appearance of the heart

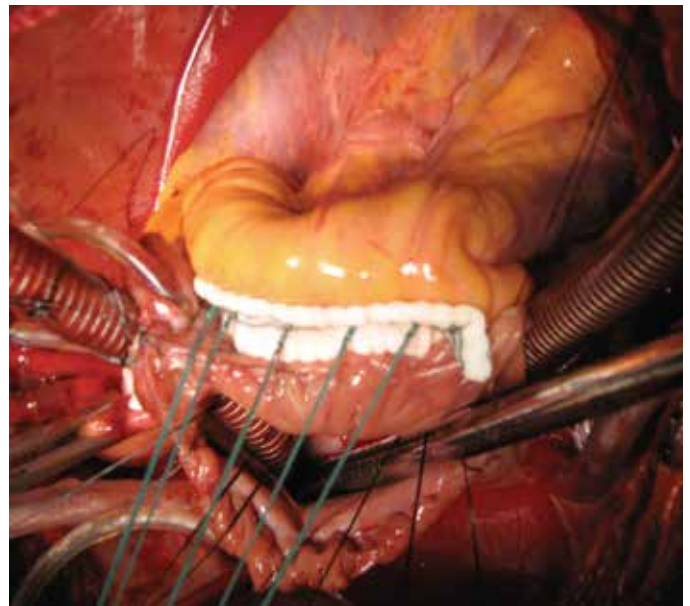


Figure 2. Suspension of atrialized portion of right ventricle

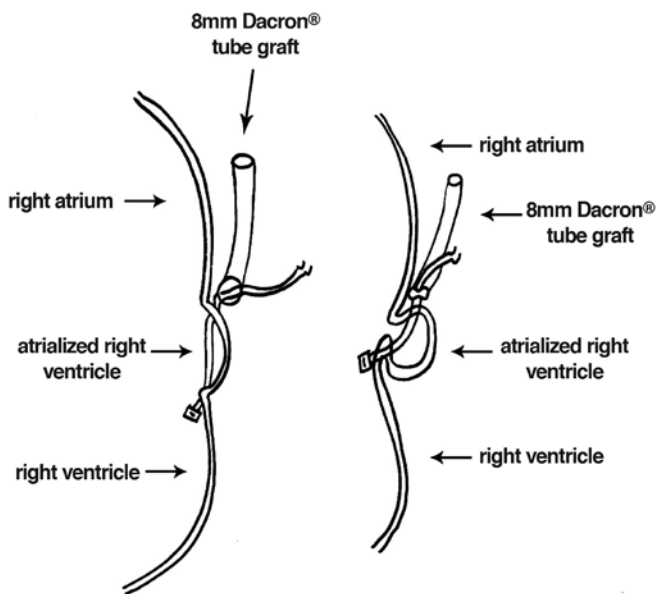


Figure 3. Suspension of atrialized portion of right ventricle

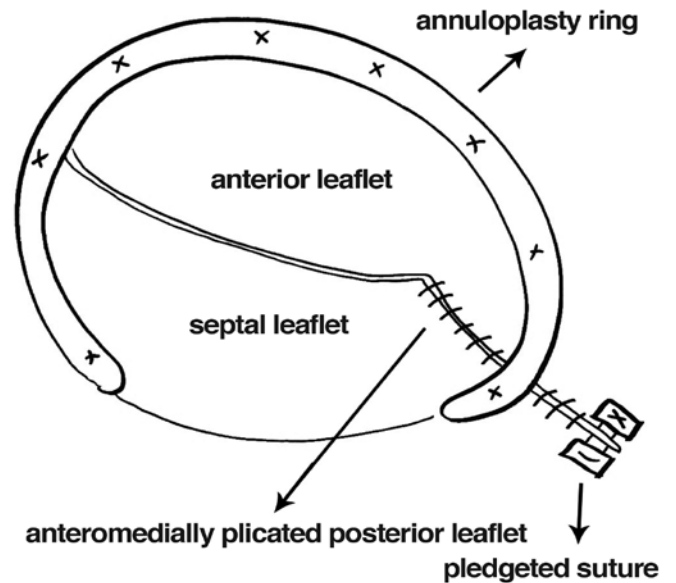


Figure 4. Suture bicuspidization of the tricuspid valve and tricuspid ring annuloplasty

however, no long-term follow-up data are available⁽²⁾. A posterior annular plication is performed to narrow the diameter of the tricuspid annulus and the atrialized right ventricle in our case. Addition of this technique to procedure is provided a total correction of anomaly.

According to Dearani and Danielson that the most important feature for a satisfactory repair is the presence of a mobile and free leading edge of the anterior leaflet likewise in our case⁽³⁾ (Figure 5).

We preferred to the plication of the atrialized RV. Since, when the ventricular wall is not contracting normally (poorly kinetic or dyskinetic), there is an indication for exclusion of the chamber (Figure 6). Longitudinal plication restores a normal shape of the RV as mentioned before by Chauvaud and Carpentier⁽⁴⁾. Combination of this technique and repair methods described by Danielson is to the best advantage method in the adult patients. The advantages of our technique are a) Combination of techniques are possible, b) Reduction in the heart size is predictable after combination of these techniques, c) Repair of tricuspid valve is feasible instead of replacement.

Tricuspid regurgitation (TR) in these patients was a marker for an inadequate size of the right ventricle. Since the Carpentier and Danielson techniques are choices of surgeons to relief the

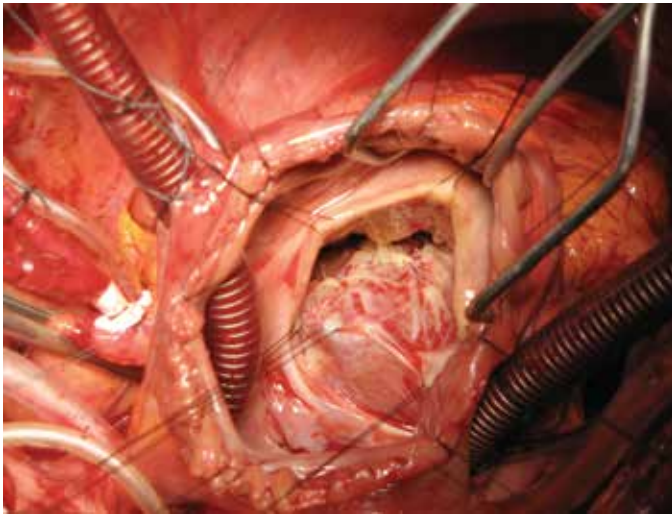


Figure 5. Anterior and posterior leaflet of tricuspid valve

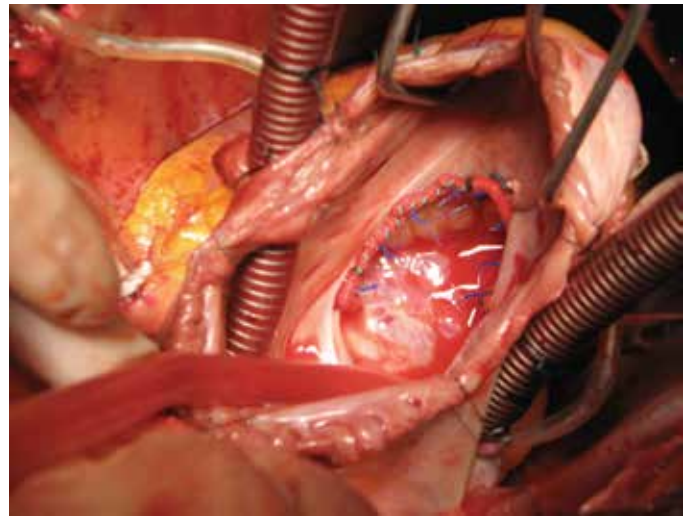


Figure 6. Ring annuloplasty of tricuspid valve

TR, our preference was combination the techniques for avoiding any residual insufficiency of Tricuspid valve. Using this strategy, we had success with this case making a durable repair of the tricuspid valve was maintained by ring annuloplasty as described by Carpentier, anatomical right ventricle morphology was maintained by RV plication as described by Danielson.

We believe that this new procedure to correct Ebstein's anomaly with the satisfactory early results. Most patients can be avoided the tricuspid valve replacement.

CONFLICT of INTEREST

The authors reported no conflict of interest related to this article.

REFERENCES

1. Palmén M, de Jong PL, Klieverik LM, Venema AC, Meijboom FJ, Bogers AJ. Long-term follow-up after repair of Ebstein's anomaly. *Eur J Cardiothorac Surg* 2008;34:48-54.
2. Attenhofer Jost CH, Connolly HM, Dearani JA, Edwards WD, Danielson GK Ebstein's Anomaly. *Circulation* 2007;115: 277-85.
3. Dearani JA, Danielson GK. Surgical Management of Ebstein's Anomaly in the Adult. *Semin Thorac Cardiovasc Surg* 2005;17:148-54.
4. Chauvaud S, Carpentier A. Ebstein's anomaly: the Broussais approach. *Multimed Man Cardiothorac Surg* 2008;doi: 10.1510/mmcts.2007.003038.