

A Large Right Atrial Myxoma Associated With Atrial Flutter Rhythm

Ahmet Şaşmaz MD¹, Türek Onur Ahmet MD², Kavlak Ela Şahinbaş MD³, Buğra Onursal MD¹

¹Kartal, Koşuyolu Heart and Research Hospital, Department of Cardiac Surgery, Istanbul, Turkey

²Arizona, USA

³Hisar Intercontinental Hospital, Department of Cardiology, Istanbul, Turkey

ABSTRACT

A 22 year-old man presented to the emergency unit with the complaint of difficulty in breathing. In the physical exam, dyspnea and orthopnea were found. In the electrocardiographic exam (ECG) atrial flutter rhythm was seen. The transthoracic echocardiographic exam revealed a large atrial mass that was originating from interatrial septum. During surgery, complete surgical removal of the right atrial mass was successfully performed under moderate hypothermia. Histological investigations revealed a mass of 15 x 3 cm in diameter and the pathological examination showed that the lesion is a myxoma. Twelve months after surgical excision, clinical and echocardiographical follow-up showed a satisfactory exercise tolerance, sinus rhythm in ECG exam, and cardiac functions within normal limits.

Key Words: Right atrial myxoma; atrial flutter

ÖZET

Atrial Flutter Ritmi ile Birlikte Görülen Büyük Sağ Atrial Miksoma

22 yaşında erkek hasta solunum sıkıntısı ile acil servimize başvurdu. Fizik muayenesinde, dispne ve ortopne saptandı. Elektrokardiyografisinde (EKG) atrial flutter ritmi gözlendi. Transtorasik ekokardiyografisinde sağ atriya yerleşmiş ve interatrial septumdan kaynaklanan bir kitle görüldü. Operasyon sırasında orta dereceli hipotermi uygulanarak sağ atriumdaki kitle başarılı bir şekilde çıkartıldı. 15 x 3 cm çapındaki kitlenin histolojik incelemesi atrial miksoma olarak değerlendirdi. Cerrahi olarak çıkartılmasından 12 ay sonra, klinik ve ekokardiyografik takiplerinde yeterli egzersiz toleransı, EKG'de sinüs ritmi ve normal sınırlar içinde kardiyak fonksiyonlar gözlendi.

Anahtar Kelimeler: Sağ atrial miksoma, atrial flutter

INTRODUCTION

Right atrial myxoma was first described at the beginning of 20th century (1). Cardiac myxomas are the most frequent benign tumors of the heart. It represents about 50 % of all primary heart tumors (2). 70 % of cardiac myxomas usually arise from the left atrium in the area of fossa ovalis. The remaining 20 % is observed in the right atrium and 5 % is usually reported in the right or left ventricles. In 1954, Crawford first successfully excised a left atrial myxoma and afterwards surgical treatment has become the standard procedure (3). The atrial myxomas can cause constitutional symptoms, such as weight loss, fever and lethargy, obstruction physiology (mitral or tricuspid depending on the side of the tumor) and heart rhythm disturbances (4). We present a case of a right atrial myxoma that was associated with temporary obstruction of inferior vena cava (IVC) and had atrial flutter rhythm.

CASE REPORT

A 22-year-old man with a medical history of dyspnea was admitted to our hospital. The auscultatory findings of the heart include both systolic and diastolic murmurs at the lower right sternal border. Atrial flutter rhythm was seen on the ECG examination. A transthoracic echocardiographic study confirmed a large mass in the right atrium extending into the inferior vena cava, causing temporary obstruction of the eustacian valve orifice. The right ventricle was mildly dilated with a normal function.

Surgery was performed through a median sternotomy and the cardiopulmonary bypass was established between the ascending aorta, superior and inferior vena cava. The myocardium was protected by the use of antegrade cardioplegia. A transverse right atriotomy was performed. A pedunculated mass was found with its base attached to the interatrial septum. This atrial mass was extending into the inferior vena cava (Figure 1).

Address for Reprints

Ahmet Şaşmaz, MD

Department of Cardiac Surgery Kosuyolu Heart and Research Center, 34846 Kartal Istanbul, Turkey

Telefon: 90 216 459 44 40 Faks: 90 216 459 63 21 e-posta: sasmazel@yahoo.com



Figure 1: Intra-operative view of the right atrial myxoma

It was completely excised with its attachment and the consequential atrial septal defect was primarily repaired. No maze procedure was performed. The measurement of the mass revealed a lesion of 10 x 3 cm (Figure 2).

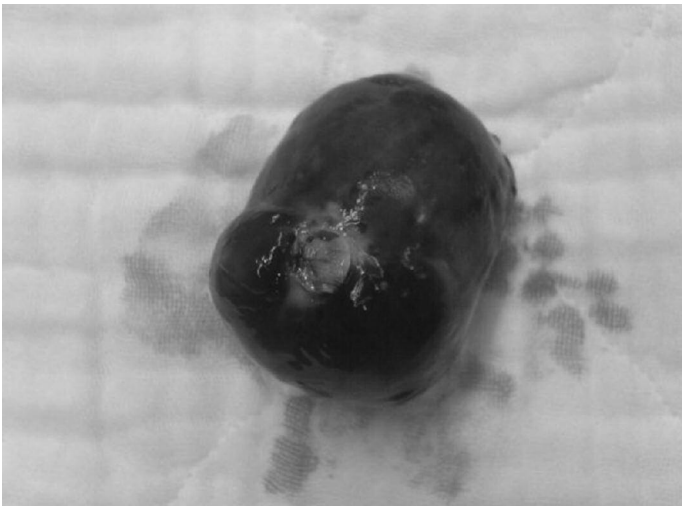


Figure 2: Right atrial myxoma after resection

The patient was easily weaned from cardiopulmonary bypass in sinus rhythm and afterwards he was discharged to home in a week time after an uncomplicated postoperative course.

The histopathological examination revealed that, myxoid stromal cells and small vessels, consistent with myxomatous changes were present. The patient remained asymptomatic twelve months after surgery with no recurrence of a lesion or myxoma. His electrocardiographic exam was consistent with atrial flutter rhythm.

COMMENT

Cardiac myxomas are the most frequent primary cardiac tumors. It is most commonly seen between the third and sixth decades of life (5). Cardiac myxomas are demonstrating 30–50% of all cardiac neoplasms (2). Myxomas are generally attached to the interatrial sep-

tum however in some cases it has connection with the cardiac valves, pulmonary artery, vein or vena cava (6). The symptoms and the clinical presentation of the patients are closely associated with the blood flow obstruction and embolic phenomena that is observed in some of the patients (7,8). These symptoms are determined by the involvement of a specific chamber and also by the size of the tumor. The clinical presentation of a right atrial myxoma can be associated with the findings of the right-sided heart failure. These signs and symptoms include hepatomegaly, ascites, and edema. The tumor may mimic the tricuspid valve stenosis by partially obstructing the valve orifice (9).

Cardiac rhythm disturbances can occur in selected cases. Approximately less than 20 % of patients have atrial fibrillation (10). In our case presentation, the observation of nonspecific electrocardiographic abnormalities caused a differential diagnosis of this suspicious rhythm disturbance and eventually lead to the diagnosis of myxoma. The pathophysiology of these arrhythmias and conduction disturbances in patients with right atrial myxomas has been discussed in the literature and the exact cause remain unclear (7). In our case, the patient remained in sinus rhythm after the surgery and no maze procedure was carried out.

REFERENCES

1. Ribbert H. Über das Myxom (about the myxom). *Frankfurter Zschr Pathol.* 1908;4:30–48
2. Reynen K. Cardiac myxomas *N Engl J Med* 1995;333:1610-161
3. Crafoord C.L. Discussion on the results of mitral commissurotomy. In: Lam C.R., ed. *Proceedings of the International Symposium on Cardiovascular Surgery, Henry Ford Hospital, Detroit, MI.* Philadelphia, PA: W.B. Saunders Co, 1955:202-211
4. Reardon MJ, Smythe WR. Cardiac neoplasms. In: Cohn LH, Edmunds LR, *Cardiac surgery in the adult, Second edition,* 2003:1374
5. Carney JA: Differences between nonfamilial and familial cardiac myxoma. *Am J Surg Pathol* 1985; 64:53.
6. Iga K, Izumi C, Konishi T. Rapid growth of a left atrial myxoma. Serial two-dimensional echocardiographic observation over eighteen months. *Int J Cardiol* 1997;61:85-87
7. Vassiliadis N., Vassiliadis K., Karkavelas G. Sudden death due to cardiac myxoma. *Med Sci Law* 1997;37:76-78
8. Cilliers A.M., van Unen H., Lala S., Vanderdonck K.H., Hartman E. Massive biatrial myxomas in a child. *Pediatr Cardiol* 1999;20:150-151.
9. Powers JC, Falkoff M, Heinle RA, et al: Familial cardiac myxoma: Emphasis on unusual clinical manifestations. *J Thorac Cardiovasc Surg* 1979; 77:782
10. Peters MN, Hall RJ, Cooley DA, et al: The clinical syndrome of atrial myxoma. *JAMA* 1974; 230:695.