

GIANT EUSTACHIAN VALVE ASSOCIATED WITH AN ECHOCARDIOGRAPHIC APPEARANCE OF DIVIDED RIGHT ATRIUM

T. YAVUZ, MD,
C. NAZLI, MD,
O. KINAY, MD,
A. ÖCAL, MD,
E. İBRİŞİM, MD,
A. KUTSAL, MD

From:

Department of
Cardiovascular Surgery,
Faculty of Medicine,
University of Süleyman
Demirel, Isparta, Türkiye
Department of Cardiology,
Faculty of Medicine,
University of Süleyman
Demirel, Isparta, Türkiye

Eustachian valve is an embryologic remnant of the valve of the inferior vena cava. It may be prominent in some individuals but the echocardiographic appearance of a divided right atrium by a large eustachian valve is extremely rare. Here we describe an unusual giant eustachian valve with an echocardiographic appearance of a septal structure dividing the right atrium into two separate chambers. This abnormality should be differentiated from a very rare cardiac malformation called "Cor Triatriatum Dexter".

Key Words: Eustachian valve, divided right atrium, adult

Eustachian valve directs oxygen-rich blood from the inferior vena cava (IVC) toward the foramen ovale and away from the tricuspid valve during the fetal life. After the closure of the foramen ovale, it does not have a specific function. In echocardiographic examinations, the eustachian valve may appear as a thin flap originating from the orifice of the IVC or it may be totally absent. Sometimes, it may appear as a rigid, elongated structure in the inferior portion of the right atrium or may be seen as a membranous, undulating echogenic mass within the right atrial cavity. Here we describe a giant eustachian valve extending from the orifice of the IVC to the interatrial septum, which appears as a septal structure dividing the right atrium into two chambers. This type of eustachian valve has not been previously reported in the literature. Such a giant eustachian valve should be differentiated from Cor Triatriatum Dexter, since the latter requires surgical correction.

CASE

A 51-year old woman was admitted to hospital because of dyspnea on exertion, fatigue and swelling in the legs. Her medical history revealed an attack of acute rheumatic fever during childhood and a

Address for

reprints:

Dr. Turhan YAVUZ
Süleyman Demirel Üniversitesi Tıp
Fakültesi
Kalp ve Damar Cerrahisi Kliniği,
Isparta, Türkiye
Tel: +90 246 232 40 27
e-mail:
turhan.kvc@doctor.com

mitral balloon valvuloplasty when she was 18 years old. She also underwent a closed mitral commissurotomy eleven years after the balloon valvuloplasty. Up on the physical examination, she had bilateral edema in the lower limbs and the liver was palpable up to 4-5 cm below the right substernal border. A rumbling diastolic murmur and a pansystolic murmur (3/6 in intensity) could be heard at the apex and the fourth left intercostal space, respectively. An ejection type loud systolic murmur was also heard at the second left intercostal space. A transthoracic echocardiogram demonstrated mitral stenosis (valve area: 1.5cm², mean transvalvular gradient: 4.5 mmHg, maximum gradient: 11mmHg), mild mitral regurgitation, moderate aortic regurgitation, aortic stenosis (mean gradient: 47mmHg, maximum gradient: 91mmHg), severe tricuspid regurgitation and tricuspid stenosis (mean gradient: 5.5mmHg, maximum gradient:17mmHg). The inferior vena cava and the hepatic veins were dilated. A rigid, membranous structure was observed within the right atrial cavity (Figure 1). This structure was originated from the atrial wall just above the orifice of the IVC and extended into the middle portion of the interatrial septum, giving an echocardiographic appearance of a divided right atrium. A coronary angiogram revealed normal coronary arteries. Cardiac catheterization findings are given in Table 1. There was no pressure rise within the different portions of the right atrial cavity. Left ventricular pressures and the transaortic pressure gradients could not be measured due to the inability of crossing the stenotic aortic valve. The patient was referred for mitral, aortic and tricuspid valve surgery.

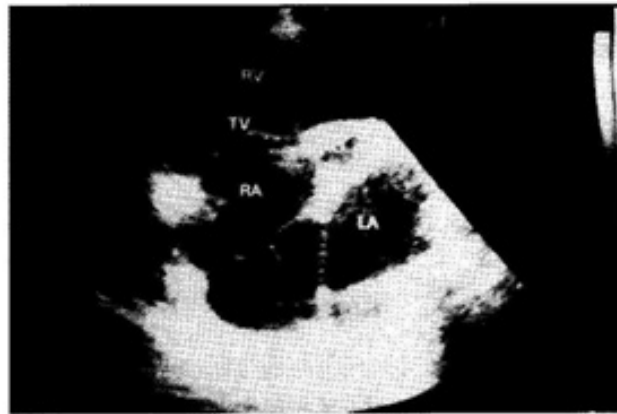


Figure 1. Rigid membranous structure dividing the right atrium.

Operative Procedure

After median sternotomy, by using standard cannulation technique, the patient was cannulated and extracorporeal circulation was initiated. Mitral valve replaced with a Sorin, No. 25 prosthetic valve and aortic valve was replaced with a Sorin, No. 19 prosthetic valve. After the right atriotomy, a giant eustachian valve was observed within the right atrial cavity (Figure 2). The medial extension of the eustachian valve was encroaching on the atrial septum as far as the limbus of the fossa ovalis. The upper endocardial surface of the eustachian valve was covered with a thin layer of partially organized thrombus which was not apparent in the echocardiographic examination. There were no interatrial septum defects. The eustachian valve was excised and a tricuspid commissurotomy was performed with a De Vega annuloplasty. The patient was discharged with no postoperative problems.

Table 1. Cardiac catheterization findings.

Pressures	mmHg
Pulmonary capillary wedge (mean)	20
Pulmonary artery	
Systolic	45
Mean	30
Diastolic	24
Right Ventricle	
Systolic	41
Diastolic	6
Right atrium (mean)	14

DISCUSSION

There is a large variability in size, shape, thickness, and texture of this structure, and even in the extent to which it encroaches on neighboring structures such as the atrial septum. At one end of the spectrum, the embryonic eustachian valve disappears completely or is represented only by a thin

ridge. Most commonly it is a crescentic fold of endocardium arising from the anterior rim of the IVC orifice. The lateral horn of the crescent tends to meet the lower end of the crista terminalis while the medial horn joins the thebesian valve, a semicircular valve fold at the orifice of the coronary sinus. At the other extreme; it persists as a mobile, elongated structure projecting several centimeters into the right atrial cavity. In this case, it may demonstrate an undulating motion in real time echocardiography and when it is quite large, it may be confused with right atrial tumors, thrombi or vegetations. Occasionally, the eustachian valve crosses the floor of the right atrium from the orifice of the IVC and inserts into the lower portion of the interatrial septum adjacent to the atrioventricular valves. However, more upper insertion of a giant eustachian valve, mimicking an echocardiographic appearance of a divided right atrium, is very rare. This type of abnormality may be confused with a cardiac malformation known as "Cor Triatriatum Dexter" (or right sided cor triatriatum). Very rarely, such a configuration of a large eustachian valve may mimic right atrial cystic tumors (1).

Cor triatriatum dexter results from persistence of the entire right sinus venosus valve which forms a large, obstructive flap or a septum across the right atrium and divide it into two separate chambers. The upstream chamber receives superior and inferior vena caval flow, while the downstream chamber incorporates the right atrial appendage. In this situation, the venous flow is directed to the upstream chamber and subsequently crosses the atrial septal defect to the left atrium, resulting in a right to left shunt. As the membrane is usually perforated, there is also some flow across the membrane into the downstream chamber and through the tricuspid valve into the right ventricle. Echocardiographically, the membrane is generally running from the inferior vena cava to the superior vena cava, separating the right atrial appendage and tricuspid valve from the great veins. In elderly patients, this cardiac malformation can be differentiated from the giant eustachian valve dividing the right atrium, by demonstration of



Figure 2. Intraoperative appearance of the giant eustachian valve.

the atrial septal defect and by the presence of cyanosis.

Patients with persistent eustachian valves and without other significant structural heart disease usually require no treatment. It has been demonstrated that symptomatic infants with persistent eustachian valve improved with conservative management alone (2). However, large eustachian valves have been reported to increase right-to-left shunting in patients with atrial septal defect by directing inferior vena caval flow through the defect into the left atrium. This abnormality may cause cyanosis during early infancy and should be corrected surgically (3,4,5). These cases may be also confused with cor triatriatum dexter both clinically and echocardiographically. Occasionally, an eustachian valve is unusually large enough to produce obstruction to flow entering from the IVC. The IVC may be dilated, suggesting that the eustachian valve may be impeding blood flow from the IVC to the right atrium. The patient is usually asymptomatic and no further intervention is required (6). In our case, the hepatic congestion and peripheral edema was most probably due to tricuspid stenosis and regurgitation rather than the obstructing eustachian valve, because pressures within the different sites of the right atrium cavity was not elevated.

Endocarditis and thrombus formation over the eustachian valve are extremely rare complications. In addition, very distinct cases of right atrial myxoma or papillary fibroelastoma originating from the eustachian valve have been also reported (7,8). Endocarditis of the eustachian valve is usually seen in intravenous drug users and can be treated with antibiotic therapy or surgery, depending on the clinical course of the case (9-11). Right atrial thrombus may be attached to the eustachian valve and may result in pulmonary thromboembolism (12). These cases may be successfully treated with thrombolytic therapy. In this particular case of giant eustachian valve, surgical excision of the valve was decided intraoperatively depending on the relatively higher risk of thrombosis and endocarditis. Since the patient was in atrial fibrillation and had a very dilated right atrium, risk of further enlargement of the thrombus over the eustachian valve and subsequent pulmonary embolism was considered to be high. Infective endocarditis risk was also regarded to be higher because of the coexisting tricuspid valve disease.

REFERENCES

1. Malaterre HR, Kalle K, Perier Y. Eustachian valve mimicking a right atrial cystic tumor. *Int J Card Imaging* 2000;16:305-7.
2. Sehra R, Ensing G, Hurwitz R. Persistent eustachian valves in infants: course and management in symptomatic patients. *Pediatr Cardiol* 1998;19:221-4.
3. Morishita Y, Yamashita M, Yamada K, et al. Cyanosis in atrial septal defect due to persistent eustachian valve. *Ann Thorac Surg* 1985;40:614-6.
4. Corno AF, Bron C, von Segesser LK. Divided right atrium. Diagnosis by echocardiography, and consideration on the functional role of the Eustachian valve. *Cardiol Young* 1999;9:427-9.
5. Condoluci C, di Donato RM, Marcelletti C, Guccione P. Central cyanosis in a newborn infant due to a prominence of the eustachian valve. *G Ital Cardiol* 1994;24:151-4.
6. Leon M, Pechacek LW, Solana LG, Massumkhani A, Colley DA. Identification of a prominent eustachian valve by means of contrast two dimensional echocardiography. *Texas Heart Institute J* 1983;10:219.
7. Teoh KH, Mulji A, Tomlinson CW, Lobo FV. Right atrial myxoma originating from the eustachian valve. *Can J Cardiol* 1993;9:441-3.
8. Shigemitsu O, Hadama T, Mori Y, et al. Surgical treatment of right atrial papillary fibroelastoma, originated from the eustachian valve-a case report. *Nippon Kyobu Geka Gakkai Zasshi* 1995;43:403-6.
9. Bowers J, Krinsky W, Gradon JD. The pitfalls of transthoracic echocardiography. A case of eustachian valve endocarditis. *Tex Heart Inst J* 2001;28:57-9.
10. Palakodeti V, Keen WD Jr, Rickman LS, Blanchard DG. Eustachian valve endocarditis: detection with multiplane transesophageal echocardiography. *Clin Cardiol* 1997;20:579-80.
11. Punzo F, Guarini P, De Michele M, et al. Eustachian Valve Endocarditis in an Elderly Woman. *Echocardiography* 1999;16:259-61.
12. Jolly N, Kaul UA, Khalilullah M. Right atrial thrombus over eustachian valve-successfully lysis with streptokinase. *Int J Cardiol* 1991;30:354-6.