

---

# A CASE OF AORTICO-LEFT VENTRICULAR TUNNEL

---

Azmi Özler, M.D.  
Cem Alhan, M.D.  
Fuat Bilgen, M.D.  
Gülşah Teyyareci, M.D.  
Nihan Baturay, M.D.

*Aortico-left ventricular tunnel is a rare congenital anomaly that usually causes severe aortic regurgitation in early childhood. In this article a case of aortico-left ventricular tunnel that has been successfully operated is reported.*

---

**Key words:** *Aortico-left ventricular tunnel, aortic regurgitation.*

**From:** Istanbul Thoracic and Cardiovascular Surgery Center

**Address for reprints:**  
Azmi Özler, M.D.  
Istanbul Thoracic and Cardiovascular Surgery Center, Istanbul, Türkiye

**A**ortico-left ventricular tunnel is a rare congenital anomaly that usually causes severe aortic regurgitation in early childhood. Since the first description of this anomaly in 1963 by Levy and associates<sup>1</sup> more than 50 cases have been reported in the literature<sup>2-5</sup>.

## Case Report

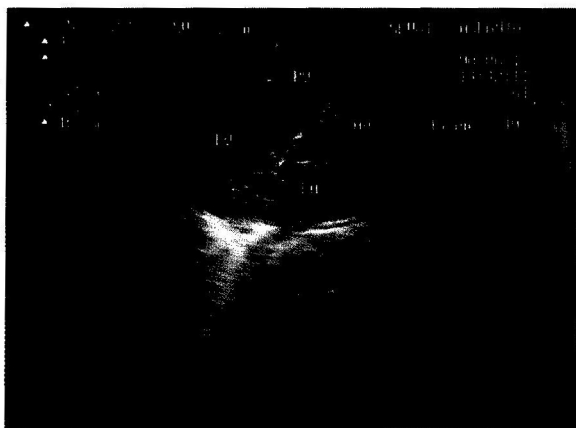
A 8 year old girl was referred for an aortic valve operation because of progressive dyspnea on exertion for the past 2 years. The blood pressure was 130/40 mmHg and the heart rate was 83 beats/min., regular and bounding. A grade of 3/6° decrescendo diastolic murmur and 2/6° systolic murmur loudest at the upper left sternal border were present. The chest roentgenogram revealed cardiomegaly and the ECG showed abnormal left axis deviation with left anterior fascicular block and left ventricular strain.

Two-dimensional and color flow Doppler echocardiographic examination showed a remarkable paravalvular aortic regurgitation. The left ventricle was dilated (end diastolic dimension 6,3 cm, end systolic dimension 5,2 cm.) (Fig.1).

Cardiac catheterization revealed profuse paravalvular aortic regurgitation. There was no evidence of a left-to-right intracardiac shunt.

## Operative Procedure

At operation, the heart was found to be greatly enlarged. The aorta was opened with the aid of cardiopulmonary bypass, moderate systemic hypothermia, and cold potassium cardioplegia. A slitlike opening that was 1 cm. long and that communicated with the left ventricle was seen (Fig. 2-A). The aortic end of the tunnel was at the left of the right coronary artery and outside of the right coronary cusp. This tunnel continued downward in a sacklike manner and opened into the left

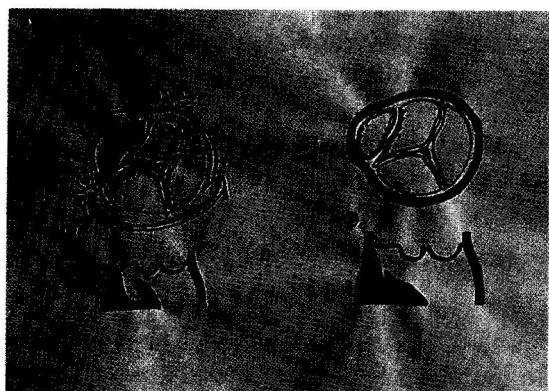


**Fig.1.** Paravalvular aortic regurgitation and LV dilatation due to aortico-left ventricular tunnel.

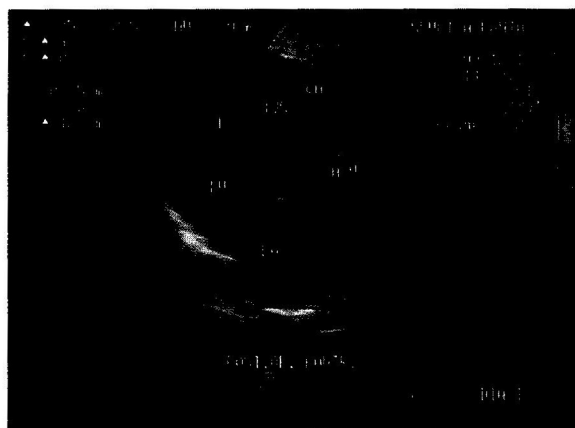
ventricle immediately below the valvular plane. The aortic valve was normal. Surgical closure of the aortic end of the tunnel was accomplished with a gore-tex patch repair (Fig.2-B). The patient had an uncomplicated postoperative course and the postoperative echocardiographic examination showed the patch to be intact (Fig.3).

### Discussion

In their collective review Hovaguimian, Çobanoğlu and Starr<sup>6</sup> reported that the mortality in aortico-left ventricular tunnel with



**Fig.2A.** Communication between aorta and left ventricle. **B:** The aortico left ventricular tunnel is closed after patch repair.



**Fig.3.** Postoperation echocardiographic control.

medical management was 100% whereas surgical mortality being 16%. They also emphasized the fact that aortico-left ventricular tunnel should be treated surgically as soon as the diagnosis is made to prevent deterioration of left ventricular function, sudden death or distortion of the aortic root and valve.

The surgical approach depends on the anatomical findings. In the case of a simple slitlike aortic opening, a simple mattress or continuous suture will be sufficient, provided any degree of valvular malalignment is avoided. In the case of a large aortic opening, as in our patient, patch material should be used to prevent valvular distortion. In the case of an intracardiac tunnel aneurysm, the reinforcing patch technique involving the subvalvular septum and aortic annulus is recommended. There are also very few reports on simultaneous valve replacement and repair of this anomaly, although valve replacement is required in 50% of patients later because of developing aortic regurgitation<sup>7</sup>

### References

- 1- Levy MJ, Lillehei CW, Anderson RC, Amplatz K, Edwards JE: Aortico-left ventricular tunnel. *Circulation* 1963;841-853.

- 2- Ribciro P, Bun-Tan CB, Oakley CM: Management of aortic left ventricular tunnel. Br Heart J 1985;54:333-336.
- 3- Humes RA, Hagler DJ, Julsrud PR, Levy JM, Feldt RH, Schaff HV: Aortico-left ventricular tunnel: diagnosis based on two-dimensional echocardiography, color flow Doppler imaging. Mayo Clin Proc 1986;61:901-904.
- 4- Akalin H, Erol Ç, Oral D, et al: Aortico-left ventricular tunnel: successful diagnostic and surgical approach to the oldest patient in the literature. J Thorac Cardiovasc Surg 1989;97:804-805.
- 5- Saylam A, Özme S, Aşlamacı S, Olga R, Aytaç A: Aortico-left ventricular tunnel. Thorac Cardiovasc Surg 1981;29:259-261.
- 6- Hovaguimian H, Çobanoğlu A, Starr A: Aortico-left ventricular tunnel: a clinical review and new surgical classification. Ann Thorac Surg 1988;45:106-112.
- 7- Medirum HW, Schroff R, Ross DN: Aortico-left ventricular tunnel: late follow-up. Ann Thorac Surg 1986;42:304-306.