

A great mimicker of mastoiditis: Multisystem Langerhans' cell histiocytosis

Foong Seong Kin¹, Ong Cheng Ai¹, Faezahtul Arbaeyah Hussain², Goh Bee See³

1 Department of ORL-HNS, Queen Elizabeth Hospital, Sabah, Malaysia

2 Department of Pathology, School of Medical Sciences, University Sains Malaysia, Health Campus, Kelantan, Malaysia

3 Department of ORL-HNS, University Kebangsaan Malaysia Medical Centre, Kuala Lumpur, Malaysia

Foong Seong Kin, ORCID:0000-0002-1846-5151

Ong Cheng Ai, ORCID: 0000-0002-1277-0905

Faezahtul Arbaeyah Hussain, ORCID:0000-0003-3899-8833

Goh Bee See, ORCID:0000-0002-5535-2930

Abstract

Langerhans' cell histiocytosis (LCH) is a rare group of diseases characterized by abnormal clonal proliferation of Langerhans cells in one or more systems. LCH can occur in any system. We report a case of bilateral otologic LCH that presented as a case of mastoiditis. Despite multiple courses of antibiotics, there was no improvement. Subsequent excision biopsy of a postauricular mass confirmed the diagnosis of LCH. The patient responded well to chemotherapy.

Keywords: Histiocytosis, Langerhans-Cell, otological diseases, mastoiditis.

Introduction

Langerhans' cell histiocytosis (LCH) is a rare group of diseases characterized by abnormal clonal proliferation of Langerhans cells in one or more systems. LCH occurs in all age groups but is most common in children from one to three years old. LCH has a low incidence, around three to five cases per million children each year.^[1] In order to establish a definitive diagnosis, either Birbeck's granules must be identified on electron microscopy or the immunohisto-

chemical staining of the cell must be CD1a, S100 and/or CD207 (Langerin) positive.^[2]

LCH can occur in any system. The most frequently affected area of the head and neck is the flat bones of the skull, followed by the meatal skin of the external auditory canal, the cervical lymph nodes, the temporal bone, the maxilla and the mandible.^[3] Temporal bone involvement occurs in 15-25% of LCH cases with bilateral disease in 25-30% of

Correspondence: Goh Bee See

Department of ORL-HNS, University Kebangsaan Malaysia Medical Centre, Kuala Lumpur, Malaysia

E-mail: beese@ppukm.ukm.edu.my

Received: 14.1.2020; **Accepted:** 10.3.2020

©2020 Continuous Education and Scientific Research Association (CESRA)

Online available at:
www.entupdatesjournal.org



those cases.^[4,5,6] The other possibly involved organs are the skin, pituitary, liver, spleen, lung and lymph nodes.^[7] The clinical course of LCH is unpredictable and can range from spontaneous resolution to rapid progression and even fatal disease. Liver or spleen involvement indicates poor prognosis.^[8]

Case Report

A 9-year-old boy presented with left posterior auricular swelling for 9 months that gradually increased in size but was not painful. Subsequently, he developed bilateral ear discharge one month later. His hearing started to reduce bilaterally and was progressively worsening. However, he denied vertigo or tinnitus. There were no significant nasal symptoms.

He was treated at a district hospital and was given multiple courses of antibiotic ear drops as well as oral antibiotics. However, despite multiple courses of antibiotics he still had persistent ear discharge and the postauricular swelling gradually increased in size.

He was then referred to the otorhinolaryngology team in a tertiary hospital. On examination, there was a postauricular mass measuring about 1cm x 2cm, brownish, smooth surface, soft, friable but non-tender (Figure 1). Otoscopy examination showed pinkish moist soft tissue in both external ear canals. The view of the tympanic membrane was obscured by the soft tissue. Facial nerves were intact bilaterally and there was no palpable neck node. Hearing assessment was performed and showed bilateral profound mixed hearing loss.

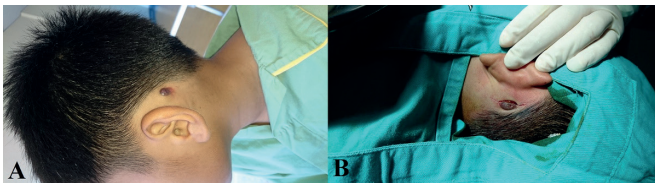


Figure 1. A- Left post auricular mass measuring 1x2cm, brownish, granular surface, soft, friable, non-tender. B- Excision of left postauricular mass

Laboratory studies revealed normal hemoglobin level with normal total white cell count. C-reactive protein and erythrocyte sedimentation rate were both elevated at 22 mg/L and 62 mm/hour, respectively. Mantoux test was negative. Sputum was negative for acid-fast bacilli and chest X-ray was normal.

High-Resolution CT of temporal bone revealed that bilateral external ear canals and bilateral mastoid air cells were filled with soft tissue (Figure 2). The right stapes was eroded but the left stapes and both mallei were present normally. Lytic lesions were seen at the base of the skull and mastoid bone. Brain MRI excluded any brain parenchymal extension, however, there were bilateral adjacent dural and leptomeningeal enhancements noted at the middle temporal fossa.

Bilateral examination under a microscope and excision biopsy of the left post-auricular mass were then performed (Figure 2). Microscopic examination showed pinkish granulation tissue in both external auditory canals. Bilateral tympanic membranes were intact but dull. A post-auricular mass measured 1x2cm, and was brownish, with granular surface, soft and friable. Histopathological examination of the postauricular mass was consistent with LCH and tissue fragments were infiltrated with neoplastic Langerhans cells that were oval in shape, having indented nuclei (Figure 3A). These histiocytes were immunoreactive to CD1a (Figure 3B).




Figure 2. A- High-Resolution Computed Tomography of temporal bone revealed left external ear canals and left mastoid air cells were filled with soft tissue. B- High-Resolution CT of temporal bone revealed right external ear canals and right mastoid air cells were filled with soft tissue.

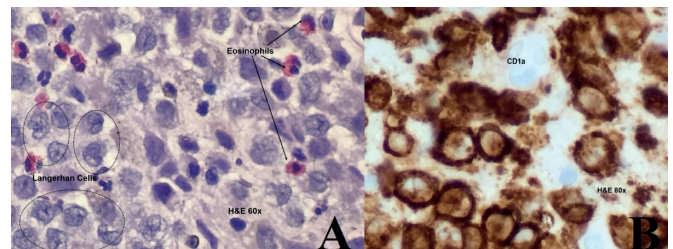


Figure 3. A- Tissue fragments infiltrated with neoplastic Langerhans Cells that are oval in shape, having indented nuclei. B- Langerhans' cell histiocytosis immunoreactive to CD1a.

A skeletal survey was done and revealed no focal lytic lesions in the bilateral upper and lower limbs, pelvic bone,

vertebrae or chest. A bone scan showed increased uptake of tracer in the temporo-mastoid bone region during the delayed phase and was consistent with LCH of the temporo-mastoid bone. Bone Marrow Aspiration Trepine showed no evidence of marrow infiltration. Computed tomography of thoracic abdomen and pelvis showed no evidence of other system involvement.

He was stratified as LCH-MS-RO- (postauricular skin, temporal bone and dura involvement) and was given 4 months of Stratum I chemotherapy, which consisted of vinblastine and prednisolone. However, repeated CT brain, HRCT temporal bone and bone scan noted that the lesion was not responsive to Stratum I chemotherapy. Subsequently, 6 months of Stratum II chemotherapy was given by the paediatric oncology team. The Stratum II chemotherapy consisted of cytarabine, vincristine and prednisolone. Repeated CT brain, HRCT temporal bone and bone scan after completion of Stratum II chemotherapy showed no residual disease. Post stratum II chemotherapy he was given 24 months of continuation therapy consisting of oral methotrexate and oral 7-mercaptapurine, which he is currently on. On follow-up, the patient tolerated the medication well without side effects. Otoscopy examination showed no ear discharge, and soft tissue mass in the external ear canal was resolved. His facial nerve was normal.

Discussion

LCH with otologic involvement is estimated to be around 15-61% of all cases of LCH.^[10,11,12] Unspecific otologic symptoms such as otorrhea, otalgia, dizziness, mastoid swelling or temporal bone mass are the otologic presentations of LCH.^[13] 5-25% of LCH patients present with solely otologic symptoms initially, just like our patient's clinical presentation, mimicking the presentation of mastoiditis.^[10,11,12] Differentiating mastoiditis from LCH can be challenging, however there are some clues that prompt the diagnosis of LCH. Retrospectively, in our patient, there was no fever, and despite topical and systemic antibiotics, ear discharge and postauricular swelling persisted. In both mastoiditis and LCH, soft tissue can be present in the external auditory canal. Tenderness and erythema postauricular swelling are usually present in cases of mastoiditis. However, a postauricular mass may or may not be tender in cases of LCH. In LCH, the tympanic membrane can be normal, signifying the importance of examination under the microscope to differentiate between mastoiditis and LCH.

Besides mastoiditis being a mimicker of LCH, there are

two other histological differential diagnoses, which are extra nodal sinus histiocytosis with massive lymphadenopathy (Rosai-Dorfman disease) and non-Hodgkin malignant lymphoma. If a postauricular mass is present, it is advised to excise the mass and send for histopathological examination to confirm the diagnosis. Rosai-Dorfman disease may occasionally involve the ear and temporal bone region.^[14] Both LCH and Rosai-Dorfman disease are S-100 protein reactive, however, Rosai-Dorfman disease is nonreactive for CD1a and Langerin.^[15] Light microscopy usually can differentiate LCH from malignant lymphoproliferative disease. If necessary, immunohistochemical stains can be used.

Surgically managed otologic LCH has been associated with a high rate of complications.^[3] Normal facial nerve landmarks can be obscured in LCH and hence facial nerve palsy is at risk. Aggressive LCH can expose the sigmoid sinus and dura,^[16,17] thereby increasing the risk of a dura tear if operative management is chosen. LCH-MS-RO- with otologic involvement responded well to Stratum II chemotherapy consisting of cytarabine, vincristine and prednisolone. Repeated HRCT temporal bone post-chemotherapy showed no residual disease. The patient tolerated chemotherapy well without side effects of chemotherapy.

Table 1. Langerhans cell histiocytosis classification according to the Histiocyte society 9

Subtype	Description
LCH – SS	A single organ is affected; no lung or risk organ involved.
LCH lung	Lung involvement but no risk organ.
LCH – MS – RO-	Multiple systems affected but no lung or risk organ involved.
LCH – MS – RO+	Multiple systems affected and at least one risk organ involved.

LCH: Langerhans' cell histiocytosis, MS: multiple systems, RO: risk organs, SS: single system

* Four different subtypes of LCH are defined by the Histiocyte Society depending on the number and kind of organs (systems) involved. Risk organs are the spleen, liver or hematologic system.

Conclusion

Temporal bone LCH presentation is similar to mastoiditis. A high index of suspicion and prompt diagnosis is crucial especially if the condition does not improve with antibiotics. Biopsy should be taken to confirm the diagnosis of

LCH. Multisystem LCH with otologic involvement but without risk to organs or lung involvement when treated with chemotherapy shows good outcomes.

Acknowledgement: None.

Informed Consent: Written informed consent was obtained from the patient who participated in this study.

Author Contributions: Designing the study – F.S.K., G.B.S.; Collecting the data – F.S.K., O.C.A., F.A.H.,

G.B.S.; Analyzing the data – O.C.A., F.A.H., G.B.S.; Writing the manuscript – F.S.K., G.B.S.; Confirming the accuracy of the data and the analyses – O.C.A., F.A.H., G.B.S.

Conflict of Interest: The author has no conflicts of interest to declare.

Financial Disclosure: The author declares that this study has received no financial support.

References

- Nicholson HS, Egeler RM, Nesbit ME. The epidemiology of Langerhans cell histiocytosis. *Hematol Oncol Clin North Am* 1998;12:379-84.
- Leung AKC, Lam JM, Leong KF. Childhood Langerhans cell histiocytosis: a disease with many faces. *World J Pediatr* 2019;15:536-45.
- Irving RM, Broadbent V, Jones NS. Langerhans' cell histiocytosis in childhood: management of head and neck manifestations. *Laryngoscope* 1994;104:64-70.
- Saliba I, Sidani K, El Fata F, Arcand P, Quintal MC, Abela A. Langerhans' cell histiocytosis of the temporal bone in children. *Int J Pediatr Otorhinolaryngol* 2008;72:775-86.
- Azouz EM, Saigal G, Rodriguez MM, Podda A. Langerhans' cell histiocytosis: pathology, imaging and treatment of skeletal involvement. *Pediatr Radiol* 2005;35:103-15.
- Fernández-Latorre F, Menor-Serrano F, Alonso-Charterina S, Arenas-Jiménez J. Langerhans' cell histiocytosis of the temporal bone in pediatric patients: imaging and follow-up. *AJR Am J Roentgenol* 2000;174:217-21.
- Howarth DM, Gilchrist GS, Mullan BP, Wiseman GA, Edmonson JH, Schomberg PJ. Langerhans cell histiocytosis: diagnosis, natural history, management, and outcome. *Cancer* 1999;85:2278-90.
- Minkov M. Multisystem Langerhans cell histiocytosis in children: current treatment and future directions. *Paediatr Drugs* 2011;13:75-86.
- Haupt R, Minkov M, Astigarraga I, et al. Langerhans cell histiocytosis (LCH): guidelines for diagnosis, clinical work-up, and treatment for patients till the age of 18 years. *Pediatr Blood Cancer* 2013;60:175-84.
- Goldsmith AJ, Myssiorek D, Valderrama E, Patel M. Unifocal Langerhans' cell histiocytosis (eosinophilic granuloma) of the petrous apex. *Arch Otolaryngol Head Neck Surg* 1993;119:113-6.
- Hermans R, De Foer B, Smet MH, et al. Eosinophilic granuloma of the head and neck: CT and MRI features in three cases. *Pediatr Radiol* 1994;24:33-6.
- McCaffrey TV, McDonald TJ. Histiocytosis X of the ear and temporal bone: review of 22 cases. *Laryngoscope* 1979;89:1735-42.
- D'Ambrosio N, Soohoo S, Warshall C, Johnson A, Karimi S. Craniofacial and intracranial manifestations of langerhans cell histiocytosis: report of findings in 100 patients. *AJR Am J Roentgenol* 2008;191:589-97.
- Wenig BM, Abbondanzo SL, Childers EL, Kapadia SB, Heffner DR. Extranodal sinus histiocytosis with massive lymphadenopathy (Rosai-Dorfman disease) of the head and neck. *Hum Pathol* 1993;24:483-92.
- Lau SK, Chu PG, Weiss LM. Immunohistochemical expression of Langerin in Langerhans cell histiocytosis and non-Langerhans cell histiocytic disorders. *Am J Surg Pathol* 2008;32:615-9.
- Levy R, Sarfaty SM, Schindel J. Eosinophilic granuloma of the temporal bone. Two cases with bilateral involvement. *Arch Otolaryngol* 1980;106:167-71.
- Mardi K, Thakur RC, Negi L. Intradural Eosinophilic Granuloma Involving Skull: Case Report and Review of the Literature. *Asian J Neurosurg* 2017;12:698-700.

This is an open access article distributed under the terms of the Creative Commons Attribution-NonCommercial-NoDerivs 3.0 Unported (CC BY-NC-ND3.0) Licence (<http://creativecommons.org/licenses/by-nc-nd/3.0/>) which permits unrestricted noncommercial use, distribution, and reproduction in any medium, provided the original work is properly cited.

Please cite this article as: Foong SK, Ong CA, Hussain FA, Goh BS. A great mimicker of mastoiditis: Multisystem Langerhans' cell histiocytosis. *ENT Updates* 2020;10(1):296-299.