

Effect of dexpanthenol on patient comfort in treatment of traumatic corneal abrasions

Travmatik korneal abrazyon hastalarında dekspantenol kullanımının hasta konforuna olan etkisi

Deniz Kilic, Esra Vural, Gamze Albayrak, Mahmut Erkam Arslan

Gönderilme tarihi:01.05.2020

Kabul tarihi:11.09.2020

Abstract

Purpose: The aim in this study was to investigate if the use of dexpanthenol could play a role in the relief of pain in the treatment of corneal abrasions (CA).

Materials and methods: Patients presenting to the ophthalmology department and had a diagnosis of CA were conducted in this retrospective, case-control study. A detailed ocular examination was done and pain severity was assessed using a visual analogue scale (VAS) score. In group 1, subjects were treated with only topical ofloxacin 0.3% while subjects in group 2 were treated with topical ofloxacin 0.3% and dexpanthenol. Foreign body sensation, photophobia, excessive lacrimation and VAS were documented on the first, third and seventh days of follow up examinations.

Results: 70 patients were allocated into group 1 and 68 patients were allocated into group 2. There were significant differences in VAS scores between the groups on the first, third and seventh days of follow up ($p=0.002$, $p<0.001$ and $p<0.001$, respectively). VAS scores were lower in group-2. There were no statistically significant differences between two groups in terms of photophobia, foreign body sensation, excessive lacrimation ($p>0.05$). All patients were free of any complications.

Conclusion: Although it was shown that adding topical dexpanthenol to the treatment regimen could permit faster pain relief in treating CAs, the prospective studies should be done.

Key words: Traumatic corneal abrasion, dexpanthenol, visual analogue scale.

Kilic D, Vural E, Albayrak G, Arslan MA. Effect of dexpanthenol on patient comfort in treatment of traumatic corneal abrasions. Pam Med J 2021;14:43-48.

Özet

Amaç: Bu çalışmada amaç, dekspantenol kullanımının travmatik kornea abrazyonlarının (KA) tedavisinde ağrının giderilmesinde etkili olabileceğini araştırmaktır.

Gereç ve yöntem: Bu vaka-kontrol çalışmasında göz hastalıkları bölümüne başvuran ve KA tanısı alan hastalar retrospektif olarak incelendi. Ayrıntılı oküler muayene yapıldı ve ağrı şiddeti görsel analog skala (GAS) skoru ile değerlendirildi. 1. grup sadece topikal ofloksasin %0,3 ile tedavi edilirken, grup 2'deki hastalar topikal ofloksasin %0,3 ve dekspantenol ile tedavi edildi. Birinci, üçüncü ve yedinci günlerde yapılan takip muayenelerinde yabancı cisim hissi, fotofobi, aşırı lakrimasyon ve GAS kaydedildi.

Bulgular: 70 hasta ilk grupta yerilirken, ikinci grupta 68 hasta vardı. Tüm vizitlerde GAS 2. grupta anlamlı olarak düşük bulundu (sırasıyla; $p=0,002$, $p<0,001$ ve $p<0,001$). İki grup arasında fotofobi, yabancı cisim hissi, aşırı lakrimasyon açısından istatistiksel olarak anlamlı fark yoktu ($p>0,05$). Hiçbir hastada komplikasyon saptanmadı.

Sonuç: KA tedavisinde dekspantenol eklemek ağrının azaltılmasında rol oynadığı gösterilmiş olsa da, bulguların prospektif çalışmalarla desteklenmesi gerekmektedir.

Anahtar kelimeler: Travmatik korneal abrazyon, dekspantenol, görsel ağrı skalası.

Kilic D, Vural E, Albayrak G, Arslan MA. Travmatik korneal abrazyon hastalarında dekspantenol kullanımının hasta konforuna olan etkisi. Pam Tıp Derg 2021;14:43-48.

Deniz Kilic, MD, FEBO, Health Science University, Kayseri City Training and Research Hospital, Department of Ophthalmology, Kayseri, Turkey, e-mail: dnz_kilic@hotmail.com (orcid.org/0000-0003-4153-5127) (Corresponding Author)

Esra Vural, MD, Health Science University, Kayseri City Training and Research Hospital, Department of Ophthalmology, Kayseri, Turkey, e-mail: vural_esra@yahoo.com (orcid.org/0000-0002-0890-5360)

Gamze Albayrak, MD, Kayseri Government Hospital, Department of Ophthalmology, Kayseri, Turkey, e-mail: gamzedkts@gmail.com (orcid.org/0000-0003-1850-8972)

Mahmut Erkam Arslan, MD, Health Science University, Kayseri City Training and Research Hospital, Department of Ophthalmology, Kayseri, Turkey, e-mail: merkam38@hotmail.com (orcid.org/0000-0002-0238-6782)

Introduction

Cornea is the transparent part of the globe and it has five layers. The corneal epithelium is the outermost layer where there are sensory nerve endings [1]. Corneal abrasions (CA) are epithelial defects due to various causes such as trauma secondary to fingernails, papers, branches, or metallic foreign bodies [2]. CA is a severely painful clinical condition because of the epithelial location of the most sensitive sensory nerve endings in the body [2]. The traditional treatment of traumatic, noncontact lens-related CAs has been antibiotic administration and patching [3]. Patching is thought to relieve the pain and provide a stable ocular surface for epithelial healing, but there are some disadvantages for patients. Because of reduced corneal oxygenation and increased corneal temperature, epithelial healing deteriorates and secondary infections can occur [4]. Besides, patients can be uncomfortable wearing an eye pad [5-7].

Since pharmaceutical companies have invented ophthalmic products containing dexpanthenol, they are now used in many ophthalmology departments to take advantage from their epithelial healing effect on the corneal epithelium layer [8-11]. After administration of dexpanthenol to an epithelial surface it is absorbed easily because of its alcoholic structure [12]. A series of metabolic processes are done enzymatically and it is converted to pantothenic acid which is the main structure of coenzyme A [12]. Coenzyme A acts as a catalyzer in syntheses of fatty acids and sphingolipids for the cell membranes [13]. Hence, pantothenic acid is an important essential molecule to maintain the physiological integrity for the cells in the body as well as corneal epithelium.

Although there are many studies investigating the effectiveness of different treatment modalities for pain relief in CAs, to the best of our knowledge, this is the first study to evaluate the effectiveness of dexpanthenol for the pain control in the treatment of CA.

Material and methods

In this retrospective case-control study, patients' medical records presenting to the Eye Clinic at Kayseri City Hospital between January 1, 2018, and December 1, 2018 with traumatic CAs of less than 24 hours' duration

were analyzed Kayseri City Hospital Ethical Committee approved the study and the study was conducted in accord with the principles of the Declaration of Helsinki. One-hundred-thirty eight patients with a diagnosis of CA and the patients who had available detailed medical records were included. Inclusion criteria were patients older than 8 years, with no evidence of corneal stromal edema and stromal infiltrates, with no history of ocular surgery, trauma or ocular disease. Contact lens wearers were also excluded from the study. All patients were asked about their age, sex, the cause of CA. Foreign body sensation, photophobia, and excessive lacrimation was recorded. A detailed ocular examination was done using a slit lamp biomicroscopy. At the same time, pain severity was assessed using a visual analogue scale (VAS) score (Figure 1). The patients were assigned into two groups. Subjects in the first group were treated with only topical ofloxacin 0.3% while subjects in the second group were treated with topical ofloxacin 0.3% and dexpanthenol (Recugel®, Bausch & Lomb, Quebec, Canada). Foreign body sensation, photophobia, and excessive lacrimation were documented at follow up examinations (first, third and seventh day after trauma). On each visit, VAS was used to assess the pain severity. The time for ending the study for both groups was the tenth day after trauma.

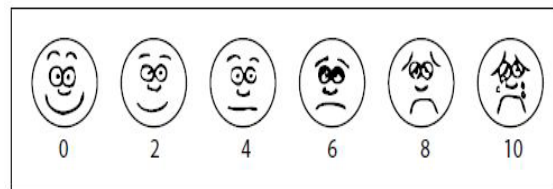


Figure 1. Visual analogue scale
0 for no pain to 10 for the maximum pain

Statistical analysis

Statistical Package for the Social Sciences (SPSS) 22.0 version, on a Windows Software (IBM Corporation, New York, USA) based PC was used for statistical analysis. Wilcoxon rank-sum test and Chi-squared test were applied to compare demographic characteristics. Differences between study groups, scales for pain severity and the other symptoms were assessed using Fisher's exact test. A $p < 0.05$ was considered statistically significant.

Results

In this study, we evaluated 162 medical records of the patients presenting with CAs from which 24 patients (five had no information about the treatment strategies, seven had other ocular pathologies or history of ocular surgeries, nine were missing in follow up and three were under the age of 8) were excluded. Of the 138 patients; 70 patients were allocated into group 1 and 68 patients were allocated into group 2. The median age of patients was 29.4 (8-49). The mean age of the patients was 30 ± 2.31 (range 8-48) in group-1 and 28.33 ± 1.83 (range 9-49) in group-2 ($p=0.868$). Ninety-eight of these patients were men (71.01%) and there was no significant difference between groups in gender; there were 50 males (71.42%) in group 1 whereas 48 (70.06%) in group 2 ($p=0.754$). After follow up examinations; we have found out that the corneal epitheliums

of all patients were healed. No statistically significant differences were observed between two groups with respect to epithelial healing rates and healing durations considering the size of defects and the ages of the subjects. On the day of trauma, VAS scores were similar in each group (6.45 ± 1.23 vs 7 ± 1.2 , $p=0.277$). At each visit, there were significant differences in VAS scores between the groups. On the first day, it was 4.22 ± 1.2 in group 1 whereas 2.36 ± 1.1 in group 2 ($p=0.002$). On the third day VAS score was 2.22 ± 2.58 in group 1 and 0.81 ± 1.82 in group 2 ($p<0.001$). On the seventh day, VAS score was 1.22 ± 0.12 in group 1 and 0.18 ± 0.82 in group 2 ($p<0.001$). VAS scores were lower for group 2 (Figure 2). There were no statistically significant differences between two groups in terms of photophobia, foreign body sensation, excessive lacrimation ($p>0.05$). All patients were free of any complications and they were all healed at the end of the study.

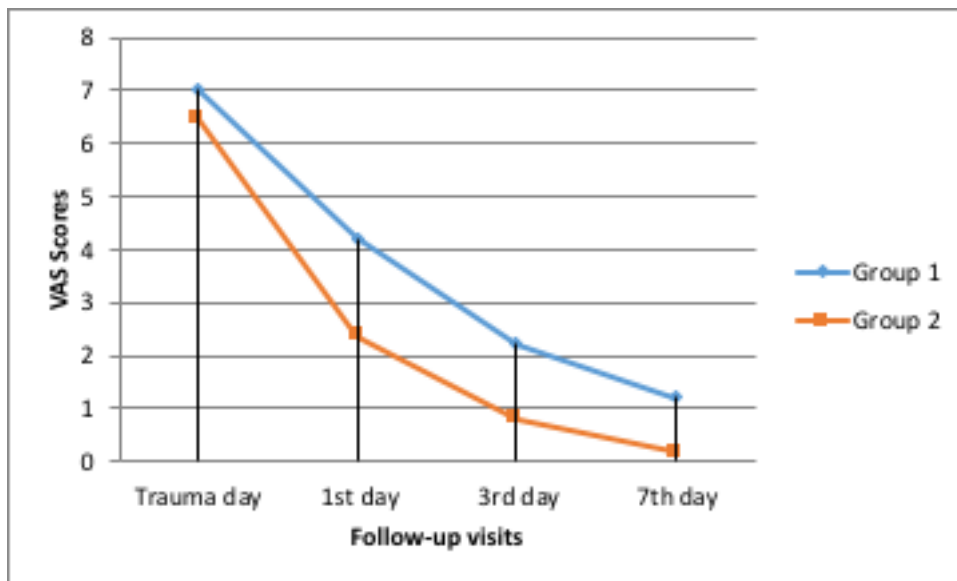


Figure 2. Changes in the scores of Visual analogue scale for each group

Discussion

In our study, we found that adding dexpanthenol to the treatment regime significantly lowered the VAS scores in patients with traumatic CAs.

CAs are non-penetrating ocular injuries and according to a recent study they are

ranked as the eighth most common condition in the emergency departments [14]. Delayed epithelial healing may cause bacterial keratitis, corneal ulcers and perforations and may impair daily activities of the patients by causing ocular pain [15, 16]. Therefore, ocular pain control and immediate treatment of epithelial defect with an antibiotic are important steps in the management of CAs [15].

Most of our patients were male similar to a report by Boberg-Ans [17]. The local area in which our study held is an industrial area. Although not all abrasions occurred from job-related injuries, the reason why male patients were more could be the higher proportion of the male workers in our district and they could immediately refer to an emergency department.

The antibiotic we used was ofloxacin drop. In CAs we routinely prescribe quinolones 4 times a day because of their broad-spectrum coverage and low toxicity [18]. Ahmad et al. [19] suggested that the use of fluoroquinolone as antibiotic prophylaxis should be considered according to the cause of abrasions. If the CA occurs from trauma to fingernails, or vegetable/organic plant matters quinolones should be the first antibiotic to use according to the some other authors [20, 21].

We used ofloxacin drop instead of ointment form of any other drugs. It is known that an ointment formula of a drug has advantages for its long acting duration after administration in corneal infections [7, 20]. In addition to their advantage of long-term durability, ointments serve as a barrier to the abrasion area [19]. According to a study reported by Eke et al. [22], recurrent epithelial erosions after CAs, especially related to fingernails, were more prevalent in the group receiving additional lubricating ointment. They suggested that weak adhesion of the epithelium, rather than the treatment regimen, might be the main cause of recurrence. Therefore, we chose dexpanthenol not only for its epithelial healing effect but also for its ointment effects.

In a recent study evaluating the effect of dexpanthenol on corneal epithelial healing after laser ablation for refractive surgery, the healing time did not differ among the treatment groups [8]. This similarity was parallel to our findings that the CAs in our study healed well and recovered at the same time in each group. Contrary to our study, Raczyńska et al. [10], found that dexpanthenol is more effective in epithelial healing. However, the patients they included were all had a surgery somehow for conjunctival or corneal injury.

In our study VAS scores were significantly lower in the dexpanthenol group at each visit. The VAS score is commonly used for assessing

the pain in CAs [3, 7, 23-25]. A VAS is a 10-cm long horizontal line with verbal descriptors that measures the extremes of the feelings psychometrically [26, 27] (Figure 1). The patients state their pain status along the line. It can easily be done by the patients and it provides monitoring the treatment effects on symptom severity day by day [26]. One of the major disadvantages of such measurements is the high individual variability and low reproducibility [28].

We assessed the relief of other symptoms e.g. photophobia, grittiness or watering of the eyes and found no significant difference among the groups. Goyal et al. [29], reported a study refuting their own hypothesis that ketorolac can provide relief to symptoms other than pain. Similar to our findings they found no difference between ketorolac and control groups for photophobia, watering, grittiness, or blurring of the eyes [29].

Our study has definite limitations that should be discussed. Although the number of patients in each group was small, it was sufficient to show a significantly decreased pain in patients treated with dexpanthenol. An increase in patient numbers might give us more certain results. The CA areas were not objectively measured in this study. However, we feel that total population of corneal injuries seen in our department is equal in size and thus all measurable abrasions were included. Another important criticism is that the observers knew which treatment the patients were given and thus there is possibility of observer bias.

On the basis of our results, broad-spectrum antibiotic drop or ointment should be the first step for treatment of superficial CAs due to trauma or foreign body removal. Then clinicians should think to help the patients to return to daily activities by decreasing the pain they suffer. For those patients with CAs, adding topical dexpanthenol to the treatment regimen will permit faster pain relief and offers the physician another option in treating corneal abrasions. Further investigations should be performed with a larger number of patients to evaluate the incidence of complications and epithelial healing associated with dexpanthenol.

Conflict of interest: The authors report no conflicts of interest in this work.

References

1. Wright ED. Traumatic corneal abrasion. *Lancet* (London, England) 1987;2:1250. [https://doi.org/10.1016/S0140-6736\(88\)90317-0](https://doi.org/10.1016/S0140-6736(88)90317-0)
2. Kaiser PK. A comparison of pressure patching versus no patching for corneal abrasions due to trauma or foreign body removal. Corneal Abrasion Patching Study Group. *Ophthalmology* 1995;102:1936-1942. [https://doi.org/10.1016/s0161-6420\(95\)30772-5](https://doi.org/10.1016/s0161-6420(95)30772-5)
3. Kirkpatrick JNP, Hoh HB, Cook SD. No eye pad for corneal abrasion. *Eye* 1993;7:468-471. <https://doi.org/10.1038/eye.1993.95>
4. Hart A, White S, Conboy P, Quinton D. The management of corneal abrasions in accident and emergency. *Injury* 1997;28:527-529. [https://doi.org/10.1016/s0020-1383\(97\)83472-9](https://doi.org/10.1016/s0020-1383(97)83472-9)
5. Wakai A, Lawrenson JG, Lawrenson AL, et al. Topical non-steroidal anti-inflammatory drugs for analgesia in traumatic corneal abrasions. *Cochrane database Syst Rev* 2017;5:CD009781. <https://doi.org/10.1002/14651858.CD009781.pub2>
6. Puls HA, Cabrera D, Murad MH, et al. Safety and effectiveness of topical anesthetics in corneal abrasions: systematic review and meta-analysis. *J Emerg Med* 2015;49:816-824. <https://doi.org/10.1016/j.jemermed.2015.02.051>
7. Rao GP, Scott JA, King A, et al. No eye pad for corneal abrasion. *Eye* 1994;8:371-372. <https://doi.org/10.1038/eye.1994.85>
8. Hamdi IM. Effect of D-Panthenol on corneal epithelial healing after surface laser ablation. *J Ophthalmol* 2018;2018:6. <https://doi.org/10.1155/2018/6537413>
9. Hahne M, Reichl S. Simulation of corneal epithelial injuries by mechanical and corrosive damage: influence of fetal bovine serum and dexpanthenol on epithelial regeneration in a cell culture model. *Ophthalmologie* 2010;107:529-532,534-536. <https://doi.org/10.1007/s00347-009-2079-x>
10. Raczynska K, Iwaskiewicz Bilikiewicz B, Stozkowska W, Sadlak Nowicka J. Clinical evaluation of provitamin B5 drops and gel for postoperative treatment of corneal and conjunctival injuries. *Klin Oczna* 2003;105:175-178.
11. Brzheskiy VV, Popov VY, Kalinina NM, Brzheskaya IV. Prevention and treatment of degenerative changes in ocular surface epithelium in patients with dry eye syndrome. *Vestn Oftalmol* 2018;134:126-134. <https://doi.org/10.17116/oftalma2018134051126>
12. Abiko Y, Tomikawa M, Shimizu M. Enzymatic conversion of pantothenylalcohol to pantothenic acid. *J Vitaminol* 1969;15:59-69. <https://doi.org/10.5925/jnsv1954.15.59>
13. Proksch E, Holleran WM, Menon GK, Elias PM, Feingold KR. Barrier function regulates epidermal lipid and DNA synthesis. *Br J Dermatol* 1993;128:473-482. <https://doi.org/10.1111/j.1365-2133.1993.tb00222.x>
14. Lai TYY, Wong VWY, Leung GM. Is ophthalmology evidence based? A clinical audit of the emergency unit of a regional eye hospital. *Br J Ophthalmol* 2003;87:385-390. <https://doi.org/10.1136/bjo.87.4.385>
15. Lin T, Gong L. Sodium hyaluronate eye drops treatment for superficial corneal abrasion caused by mechanical damage: a randomized clinical trial in the People's Republic of China. *Drug Des Devel Ther* 2015;9:687-694. <https://doi.org/10.2147/DDDT.S77270>
16. Thiel B, Sarau A, Ng D Efficacy of topical analgesics in pain control for corneal abrasions: a systematic review. *Cureus* 2017;9:e1121. <https://doi.org/10.7759/cureus.1121>
17. Boberg Ans G, Nissen KR. Comparison of Fucithalamic viscous eye drops and Chloramphenicol eye ointment as a single treatment in corneal abrasion. *Acta Ophthalmol Scand* 1998;76:108-111. <https://doi.org/10.1034/j.1600-0420.1998.760121.x>
18. De Kaspar HM, Chang RT, Shriver EM, et al. Three-day application of topical ofloxacin reduces the contamination rate of microsurgical knives in cataract surgery: a prospective randomized study. *Ophthalmology* 2004;111:1352-1355. <https://doi.org/10.1016/j.ophtha.2003.10.032>
19. Ahmed F, House RJ, Feldman BH. Corneal abrasions and corneal foreign bodies. *Prim Care* 2015;42:363-375. <https://doi.org/10.1016/j.pop.2015.05.004>
20. Hobden JA, O'Callaghan RJ, Insler MS, Hill JM. Ciprofloxacin ointment versus ciprofloxacin drops for therapy of experimental *Pseudomonas* keratitis. *Cornea* 1993;12:138-141. <https://doi.org/10.1097/00003226-199303000-00008>
21. Chojnacki M, Philbrick A, Wucher B, et al. Development of a broad-spectrum antimicrobial combination for the treatment of staphylococcus aureus and pseudomonas aeruginosa corneal infections. *Antimicrob Agents Chemother* 2019;63:e01929-18. <https://doi.org/10.1128/AAC.01929-18>
22. Eke T, Morrison DA, Austin DJ. Recurrent symptoms following traumatic corneal abrasion: prevalence, severity, and the effect of a simple regimen of prophylaxis. *Eye* 2019;63:e01929-18. <https://doi.org/10.1038/eye.1999.87>
23. Le Sage N, Verreault R, Rochette L. Efficacy of eye patching for traumatic corneal abrasions: a controlled clinical trial. *Ann Emerg Med* 2001;38:129-134. <https://doi.org/10.1067/mem.2001.115443>
24. Michael JG, Hug D, Dowd MD. Management of corneal abrasion in children: a randomized clinical trial. *Ann Emerg Med* 2002;40:67-72. <https://doi.org/10.1067/mem.2002.124757>
25. Patterson J, Fetzer D, Krall J, Wright E, Heller M. Eye patch treatment for the pain of corneal abrasion. *South Med J* 1996;89:227-229. <https://doi.org/10.1097/00007611-199602000-00015>

26. Heller GZ, Manuguerra M, Chow R. How to analyze the visual analogue scale: myths, truths and clinical relevance. *Scand J Pain* 2016;13:67-75. <https://doi.org/10.1016/j.sjpain.2016.06.012>
27. Klimek L, Bergmann KC, Biedermann T, et al. Visual analogue scales (VAS): measuring instruments for the documentation of symptoms and therapy monitoring in cases of allergic rhinitis in everyday health care: Position Paper of the German Society of Allergology (AeDA) and the German Society of Aller. *Allergo J Int* 2017;26:16-24. <https://doi.org/10.1007/s40629-016-0006-7>
28. Menghini M, Knecht PB, Kaufmann C, et al. Treatment of traumatic corneal abrasions: a three-arm, prospective, randomized study. *Ophthalmic Res* 2013;50:13-18. <https://doi.org/10.1159/000347125>
29. Goyal R, Shankar J, Fone DL, Hughes DS. Randomised controlled trial of ketorolac in the management of corneal abrasions. *Acta Ophthalmol Scand* 2001;79:177-179. <https://doi.org/10.1034/j.1600-0420.2001.079002177.x>

Acknowledgments: Word counts for the abstract and text: 200 and 1521 respectively. Number of figures and references: 1 and 29 respectively. The first part of this study was presented orally at the first International Ahi Evran Medical and Health Science Congress (IAMHC) held between 11 and 14 April 2019 in Turkey.

Ethics approval: Kayseri City Hospital Ethical Committee approved the study (date: 08/01/2020 and number 09).

Author Contributions Statements

D.K., E.V. made the study concept and design collected the data; drafted and revised the manuscript; and approved the final version to be published. M.A. analysed the data and revised the manuscript; and approved the final version to be published. G.A. collected the data, revised and approved the final version to be published.