

EDİTÖRE MEKTUP / LETTER TO THE EDITOR

Tonsil metastasis of lung adenocarcinoma: a rare case

Akciğer adenokarsinomu tonsil metastazı: nadir bir olgu

Levent Yücel¹, Muhammed Fatih Gökmen², Zahide Çiler Büyükkatalay³, Serpil Dizbay Sak⁴, Süha Beton³

¹Gülhane Training and Research Hospital, University of Health Sciences, Department of Otorhinolaryngology, Ankara, Turkey

²Darende Hulusi Efendi Hospital, Department of Otorhinolaryngology, Malatya, Turkey

³Ankara University Faculty of Medicine, Department of Otorhinolaryngology, ⁴Department of Pathology, Ankara, Turkey

Cukurova Medical Journal 2020;45(3):1250-1252

To the Editor,

Tonsil cancers account for 0,3% of all cancers and 6,7% of head and neck cancers. However, metastasis to tonsil is extremely rare¹. The kidney, skin, lung and breast are most common sites of primary tumor². Different histological types of lung cancer can metastase to tonsil. We present a case with left tonsil metastasis of lung adenocarcinoma.

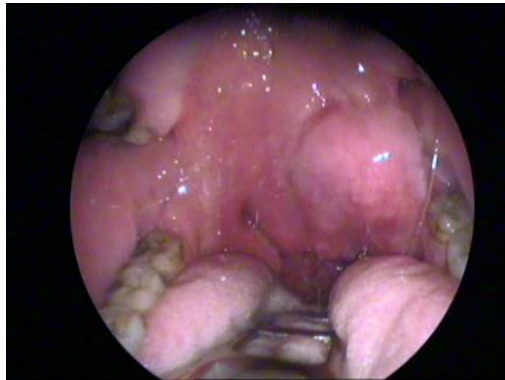

Figure 1. Endoscopic examination of patient. Asymmetric, hipertrophic appearance resembling peritonsillar abscess, necrosis in inferior pole of left tonsil.

A 50-year-old male was admitted to Department of Otorhinolaryngology, Faculty of Medicine, University of Ankara with oneyear history of sore throat, dysphagia and halitosis. He had been treated with antibiotics a few times before being admitted to

our clinic. There was no history of tobacco or alcohol. In surgical history, he underwent operation for lung adenocarcinoma 2,5 years before and there was no chemotherapy or radiotherapy history. In physical examination, left tonsil was asymmetric and hypertrophic resembling a peritonsillar abscess and inferior and posterior pole of the left tonsil were necrotic (Figure 1). CT and MR scans showed 2,5 x3x5 cm cystic and necrotic mass on left tonsil (Figure 2,3).

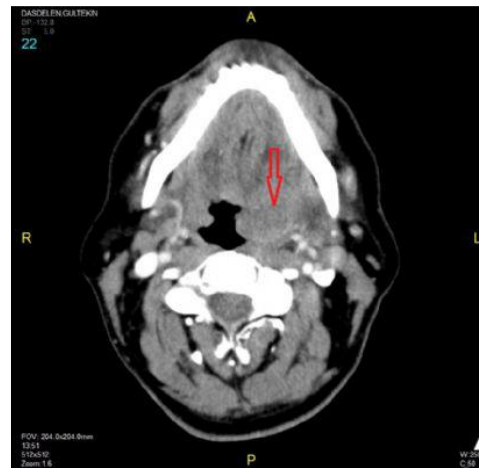

Figure 2. Axial CT scan of patient.

Arrow shows us cystic and necrotic mass in left tonsil.

Yazışma Adresi/Address for Correspondence: Dr. Levent Yücel, Gülhane Training and Research Hospital, University of Health Sciences, Department of Otorhinolaryngology, Ankara, Turkey E-mail: leventyucel51@hotmail.com
Geliş tarihi/Received: 01.04.2020 Kabul tarihi/Accepted: 02.05.2020 Çevrimiçi yayın/Published online: 31.08.2020

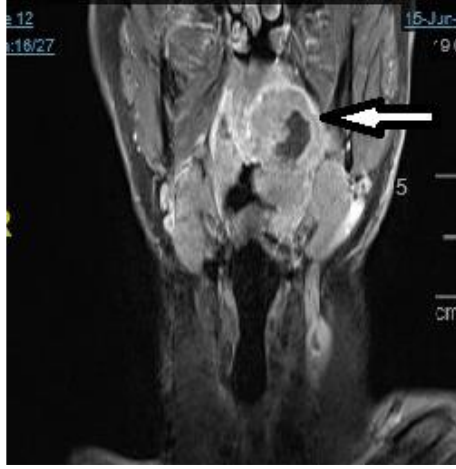


Figure 3. T2 weighted coronal MR scan.

Arrow shows cystic necrotic mass which compromising the airway in left tonsil.

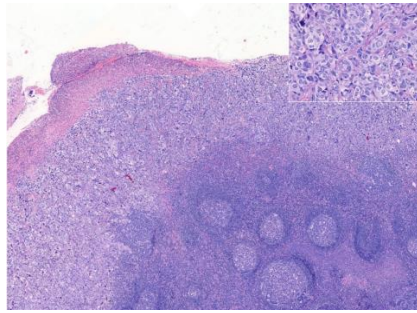


Figure4. Malignant epithelial cells infiltrating lymphoid tissue of tonsil and ulcerating the mucosal surface

(HE, digital image X4.5; insetX44.5).

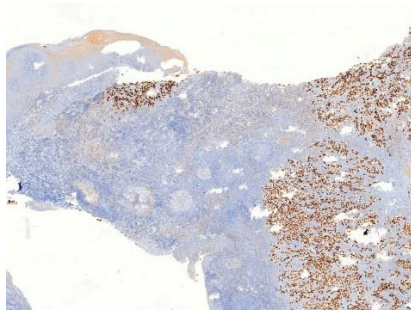


Figure 5. Nuclear TTF1 staining of tumor cells, showing pulmonary origin

(TTF1, digital image X13.8).

We performed biopsy on left tonsil which revealed lung adenocarcinoma metastasis (Figure 4,5). After the diagnosis, PET/CT scan showed pathological involvement in left tonsil and left neck lymph nodes and there was no recurrence of primary tumor site. The patient was recommended surgery, however didn't accept. Afterwards, he was admitted to another hospital and underwent tumor tonsillectomy, neck dissection and pectoralis major flap for reconstruction and died after 10 days after surgery because of respiratory failure.

Metastatic tonsil tumor accounts for 0,8% of malignant tonsil neoplasms. Many organs and histological types have been described in the literature but there are less than 100 cases from lung³. Tonsillar metastasis from lung are mainly from small cell carcinoma. First tonsillar metastasis from lung adenocarcinoma was described by Mastronikolis et al¹. The route of spread of carcinoma is controversial, because palatine tonsil has only efferent pathways. For intraabdominal primary tumors hematogeneous spread may be responsible for metastasis⁴. Retrograd spread has also been proposed but is considered unusual. The prognosis of metastatic tonsil tumor is very poor. There is no standard treatment methods on metastases to tonsils from lung cancer. Surgery, radioterapy, chemotherapy, chemoradiotherapy and immunotherapy have all been tried before⁴. The most important point with our case is that the patient had his complaints for 1 year and received irrelevant treatments. As in our case, tonsil neoplasms may present with peritonsillar abscess. However, patients with history of cancer and prolonged complaints need a thorough evaluation of suspicious tonsil enlargement. Metastases may be synchronous with the lung tumor or may be observed before or after the treatment of primary tumor⁵. Careful examination and radiological evaluation are very important in cancer patients; and biopsy must be performed in all cases with clinical suspicion.

Yazar Katkıları: Çalışma konsepti/Tasarımı: LY, MFG, ZÇB, SDS, SB; Veri toplama: LY, MFG, ZÇB; Veri analizi ve yorumlama: LY, ZÇB, SDS, SB; Yazı taslağı: LY, SB; İçeriğin eleştirel incelenmesi: LY, MFG, ZÇB, SDS, SB; Son onay ve sorumluluk: LY, MFG, ZÇB, SDS, SB; Teknik ve malzeme desteği: LY, MFG; Süpervizyon: LY, MFG, ZÇB, SDS, SB; Fon sağlama (mevcut ise): yok.

Hakem Değerlendirmesi: Dış bağımsız.

Çıkar Çatışması: Yazarlar çıkar çatışması beyan etmemişlerdir.

Finansal Desteği: Yazarlar finansal destek beyan etmemişlerdir.

Yazarın Notu: Makalenin 38. Ulusal Kulak Burun Boğaz baş ve Boyun Cerrahisi Kongresi'nde e-poster sunumu olarak sunulduğunu da not ettik, 26-30 Ekim 2016-Ankara

Author Contributions: Concept/Design : LY, MFG, ZÇB, SDS, SB; Data acquisition: LY, MFG, ZÇB; Data analysis and interpretation: LY, ZÇB, SDS, SB; Drafting manuscript: LY, SB; Critical revision of manuscript: LY, MFG, ZÇB, SDS, SB; Final approval and

accountability: : LY, MFG, ZÇB, SDS, SB; Technical or material support: LY, MFG; Supervision: LY, MFG, ZÇB, SDS, SB; Securing funding (if available): n/a.

Peer-review: Externally peer-reviewed.

Conflict of Interest: Authors declared no conflict of interest.

Financial Disclosure: Authors declared no financial support

Acknowledgement: We also note that the manuscript had been presented in 38th National Otorhinolaryngology Head & Neck Surgery Congress as an e-poster presentation, 26-30 October 2016- Ankara, Turkey.

REFERENCES

1. Mastronikolis NS, Tsiropoulos GE, Chorianopoulos D, Liava AC, Stathas T, Papadas TA. Palatine tonsillar metastasis from lung adenocarcinoma. *Eur Rev Med Pharmacol Sci.* 2007;11:279-82.
2. Sellars SL. Metastatic tumours of the tonsil. *J Laryngol Otol.* 1971;85:289-92.
3. Chen CC, Lee CT, Chang SL., Tsai MC. A case of palatine tonsillar metastasis of lung adenocarcinoma: A CARE-compliant article. *Medicine (Baltimore).* 2019;98(22):e15763..
4. Unsal M, Kutlar G, Sullu Y, Yurtlu S. Tonsillar metastasis of small cell lung carcinoma. *Clin Respir J,* 2016;10:681-3.
5. Tian Y, Han Y, Du J, Zhang Y, Liu N, Du X et al. Palatine tonsillar metastasis of lung adenocarcinoma: an unusual immunohistochemical phenotype and a potential diagnostic pitfall. *Int J Clin Exp Pathol.* 2019;12:2288.