

## SEZARYEN SONRASI ABDOMİNAL DUVAR SKAR ENDOMETRİOZİSİ; ÇOKLU ODAK İÇEREN NADİR BİR OLGU SUNUMU

### ABDOMINAL WALL SCAR ENDOMETRIOSIS AFTER CESAREAN SECTION; A RARE CASE REPORT WITH MULTI FOCUS

Ayhan ATIGAN<sup>1</sup>, Derya KILIÇ<sup>1</sup>, Yeliz ARMAN KARAKAYA<sup>2</sup>, Ömer Tolga GÜLER<sup>1</sup>

<sup>1</sup>Pamukkale Üniversitesi Tıp Fakültesi, Kadın Hastalıkları ve Doğum Ana Bilim Dalı

<sup>2</sup>Pamukkale Üniversitesi Tıp Fakültesi, Patoloji Ana Bilim Dalı

#### ÖZET

Endometriozis, uterus kavitesinin dışında fonksiyonel endometriyal dokunun varlığı olarak tanımlanır. Skar endometriozisi (SE), genellikle rahim ve fallop tüplerini içeren pelvik operasyonlardan sonra gelişen nadir bir durumdur. Semptomlar spesifik değildir. Genellikle başvuru şikayeti menstruasyon sırasında insizyon bölgesine lokalize ağrıdır. Teşhisi bazen zor olabilir ve diğer çeşitli cerrahi sonrası komplikasyonlar ile karışabilir. Tanı genellikle histopatolojik inceleme ile konulur. Bu yazıda sezaryen sonrası insizyonel bölgede gelişen, en büyüğü 5x4x3 cm boyutlara ulaşan çoklu sayıda odak içeren endometriozis olgusu sunulmuştur. Abdominal operasyon öyküsü ve siklik ağrılı solid kitlesi olan hastalarda karın duvarı kitlelerinin ayırıcı tanısında skar endometriozisdüşünülebilir.

**ANAHTAR KELİMELE:** Skar endometriozis, Sezaryen, Siklik ağrı

#### ABSTRACT

Endometriosis is described as the presence of functional endometrial tissue outside the uterine cavity. Scar endometriosis (SE) is a rare condition which usually develops after gynecologic operations involving the uterus and fallopian tubes. The symptoms are usually nonspecific and cyclic incisional pain increasing by menstruation is the most common symptom. Diagnosis of the disease can be difficult and may be confusing with various other post-surgical conditions. Histopathological examination reveals the final diagnosis. This article presents a case with cesarian SE of which the largest reaches 5x4x3 cm with multiple foci. Scar endometriosis should be considered in the differential diagnosis of abdominal wall masses in the patients with a history of abdominal surgery and cyclic painful solid mass.

**KEYWORDS:** Scar endometriosis, Cesarean section, Cyclic pain

**Geliş Tarihi / Received:** 15.05.2020

**Kabul Tarihi / Accepted:** 06.01.2021

**Yazışma Adresi / Correspondence:** Dr. Ayhan ATIGAN

Pamukkale Üniversitesi Tıp Fakültesi, Kadın Hastalıkları ve Doğum Ana Bilim Dalı

**E-mail:** dratigan@hotmail.com

**Orcid No (Sırasıyla):** 0000-0002-7257-0593, 0000-0001-8003-9586, 0000-0002-6669-9972, 0000-0001-6673-8604

## INTRODUCTION

Endometriosis is a chronic gynecologic disorder, defined as the presence or growth of ectopic endometrial tissue (1 - 3). Endometriosis first described by German pathologist Carl von Rokitansky in 1860 as cystosarcoma adenoids uterinum. It is defined as presence of endometrial glands and stroma outside of uterine cavity with a prevalence of 5-10% in women with reproductive age (4). Endometriosis is usually found in the pelvic location, such as the ovaries, posterior cul-de-sac, utero-sacral ligaments, pelvic peritoneum and rectovaginal septum (5). However, subcutaneous and/or abdominal wall endometriosis is one of the rare gynecological conditions.

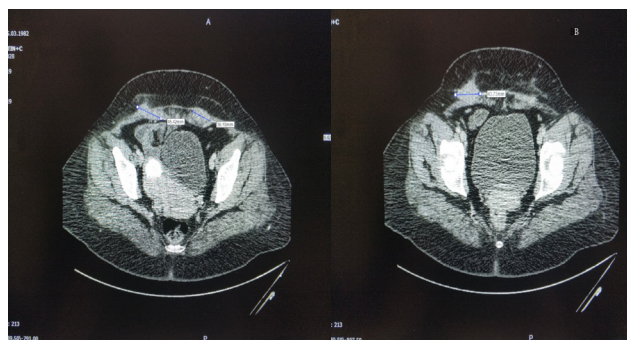
Scar endometriosis (SE), an extremely rare type of extra pelvic endometriosis with an incidence of 0.03-3.5%, is the presence of endometriosis at/or near previous surgery scar site as a painful discreet tumoral mass (4). SE after cesarean section is a rare complication and difficult to diagnose. It should be considered in the evaluation of painful abdominal masses in women with previous pelvic surgery history (5). During the evaluation painful abdominal wall masses, it is usually assumed to be a suture granuloma, incisional hernia, lipoma, abscess, cyst, or a strange body. Although the symptoms are not specific, it is noteworthy that cyclic abdominal wall pain is seen at incisional region during menstruation (6).

Herein, we present a case who had two previous cesarean sections and diagnosed with 5x4x3 cm, 4x3x2 cm, 3x2x1 cm heterogeneous hypoechoic three masses on the pfannenstiell incision site at the suprapubic region anterolateral to the rectus abdominis muscle.

## CASE PRESENTATION

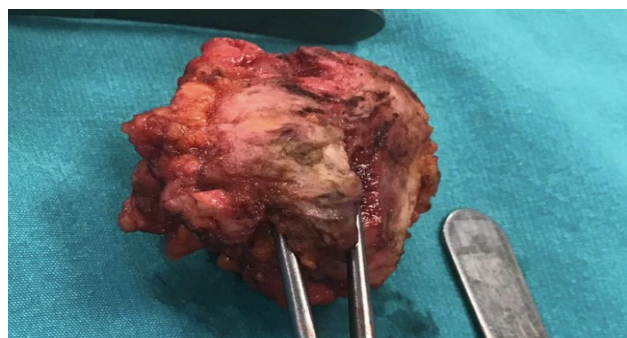A 37-year-old female patient presented with a cyclic painful and palpable three solid masses in the suprapubic region at the pfannenstiell incision site. Although she admitted with persistent pelvic pain, she also complained about cyclic pain increasing with menstruation. She had two prior cesarean sections. She has no history of additional surgery and endometriosis. Written informed consent was obtained from the patient.

Physical examination revealed a fibrotic nodule on the right side of the cesarean section scar (pfannenstiell incision). She also described drug resistant abnormal uterine bleeding. Multiple myomas were present on ultrasonography (USG) and bilateral ovaries were in the usual appearance. Her serum cancer antigen 125 (CA-125) level was measured as 100 IU/ml. Computed tomography (CT) before the surgery revealed three subcutaneous and intrafascial nodular lesions in which the biggest one was 5x4x3 cm (**Figure 1 a-b**).



**Figure 1 a-b:** Multi-focused nodular hyperdense lesions seen in CT

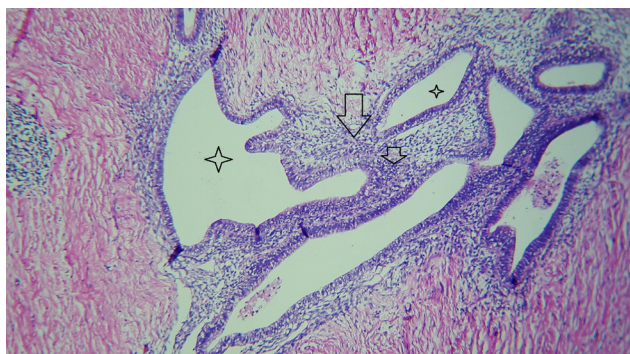
The patient underwent hysterectomy for menometrorrhagia resistant to conventional treatment and uterus myomatosis. At the same session subcutaneous masses was removed from the same incision. The macroscopic image of the biggest mass of approximately 5x4x3 cm is presented in the **Figure 2**.



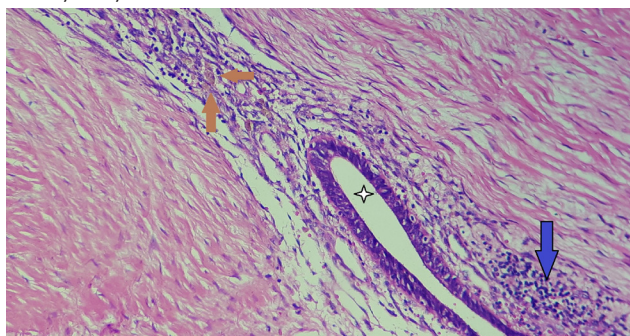
**Figure 2:** Macroscopic view of the abdominal mass excision

Final pathological examination confirmed the diagnosis of uterus myomatosis of hysterectomy material and revealed endometriosis for the abdominal masses. Endometrial gland and stroma were observed in the microscopic examination of fibrous tissue with hematoxylin eosin (H&E) (**Figure 3**). In addition, hemosiderin laden macrophages were also observed in the stroma (**Figure 4**). Lesions were totally excised with negative surgical margins in all three biopsy specimens. Patient underwent dienogest

therapy for 6 months period after surgery. No recurrence was observed at the first year follow-up.



**Figure 3:** Endometrial gland (star) and stroma (arrow) in fibrous tissue, H&E, x200



**Figure 4 :** Endometrial gland (star), stroma (blue arrow) and hemosiderin laden macrophages (brown arrow) in the stroma, H&E, x100

## DISCUSSION

Scar endometriosis is commonly confined to the superficial layers of the abdominal wall as seen in our case. However it can also infiltrate deeper layers (7). Although scar endometriosis is a rare phenomenon, it should be considered in the differential diagnosis of abdominal wall masses in women. In accordance with our case, the mean size of the mass has been 3.1 cm (1.5-4.8 cm) in literature (8). Our case is also interestingly multi-focused.

The imaging techniques such as CT, magnetic resonance imaging (MR) or USG with a well-received medical history and detailed physical examination help the clinicians to identify the condition; however, the pathological evaluation of a node is required for final diagnosis (9).

These lesions may also result from other gynecologic or obstetric procedures, such as, hysterectomy, laparoscopy, amniocentesis, surgery for ectopic pregnancy. Although currently it is very rare, its incidence may increase by increasing rates of caesarean section in the near future.

In our case report, the patient had two previous cesarean sections and no history of endometriosis, which is in accordance with the transplantation theory. Since our patient has no history of endometriosis, iatrogenic transportation of endometrial glands to the wound edge during the procedure seems like the potential mechanism. These implants requires subsequently stimulation by estrogen to produce endometriosis in an appropriate hormonal status.

Consistent with the literature, our patient had palpable abdominal wall masses and cyclic increasing pelvic pain with menstruation. In the differential diagnosis of SE; hematoma, incisional hernia, granuloma, abscess, cheloids, lipoma, sebaceous cyst, as well as neoplastic tissue or metastatic carcinoma should be kept in mind.

In conclusion, a cesarian scar endometriosis is a condition that presents with cyclic painful solid mass near the pfannenstiell scar and it should be considered in the differential diagnosis of abdominal wall masses.

## REFERENCES

1. Goel P, Sood SS, Romilla, Dalal A. Cesarean scar endometriosis - Report of two cases. *Indian J Med Sci.* 2005;59(11):495-8.
2. Brosens I, Benagiano G. Endometriosis, a modern syndrome. *The Indian Journal of Medical Research.* 2011;133(6):581-93.
3. Benagiano G, Brosens I. Who identified endometriosis? *Fertil Steril.* 2011;95:13-6.
4. Gupta P, Gupta S. Scar Endometriosis: a case report with Literature review. *Acta Medica Iranica.* 2015;53(12):793-5.
5. Adriaanse B, Natté R, Hellebrekers B. Scar endometriosis after a caesarean section: a perhaps underestimated complication. *Gynecological Surgery.* 2013;10(4):279-84.
6. Mistrangelo M, Gilbo N, Cassoni P, et al. Surgical scar endometriosis. *Surg Today.* 2014;44: 767-72.
7. Celik M, Bülbüloglu E, Büyükbese MA, Cetinkaya A. Abdominal Wall Endometrioma: Localizing in Rectus Abdominus Sheath. *Turk J Med Sci.* 2004;34:341-3.
8. Sengul I, Sengul D, Kahyaoglu S, Kahyaoglu I. Incisional endometriosis: a report of 3 cases. *Can J Surg.* 2009;52(5):444-5.
9. Ding DC, Hsu S. Scar endometriosis at the site of cesarean section. *Taiwan J Obstet Gynecol.* 2006;45:247-9.