

An Unexpected Pathological Result Of A Large Odontogenic Cyst With Impacted Teeth In The Anterior Mandible

Alt Çenenin Ön Bölgesinde Yer Alan Çevresinde Büyük Bir Kist Olan Gömülü Dişlerin Beklenmedik Patolojik Bulgusu

ABSTRACT

Radicular cyst is the most common odontogenic cyst that developed due to an inflammation in the jaws. It is occurred bacterial infection and necrosis of the dental pulp are caused by the growth of apical lesion and mostly due to the involvement of tooth decay. In this case, a 54-year-old male patient's images presented large radiolucent area with three impacted teeth and distortion of the cortical bone at the base of the mandible on anterior region, suggesting an odontogenic dentigerous cyst.

This report aims to present rarely seen radiography and tomography findings of the case of unexpectedly diagnosed radicular cyst.

Key words: Large radicular cyst, odontogenic cyst, impacted teeth

ÖZ

Çene kemiklerinde inflamasyon kaynaklı oluşan kistler içerisinde en yaygın görüleni radiküler kisttir. Pulpanın bakteriyel enfeksiyonu ve nekrozu sonucu oluşan apikal lezyondan köken alarak gelişmektedir ki bu da çoğunlukla diş çürükleri nedeniyle oluşur. Bu vakada, 54 yaşındaki erkek hastanın görüntülerinde mandibula anteriorunda üç adet gömülü diş ve mandibula tabanındaki kortikal kemiği distorsiyona uğratan radyolusent alan gözlemlendi, bu görüntü odontojenik dentigeröz kisti düşündürdü.

Bu rapor beklenmedik bir şekilde radiküler kist tanısı alan vakanın çok nadir gözlenen radyografi ve tomografi bulgularını sunmayı amaçlamaktadır.

Anahtar sözcükler: Büyük radiküler kist, Odontojenik kist, Gömülü diş

Bilgün ÇETİN¹

ORCID: 0000-0002-1577-5568

Fatma Büşra DOĞAN¹

ORCID: 0000-0002-9229-1559

Faruk AKGÜNLÜ¹

ORCID: 0000-0002-3427-1381

1 Oral and Maxillofacial Radiology
Department, Dentistry Faculty of
Selçuk University,
Konya/TURKEY



Geliş tarihi / Received: 23.02.2019

Kabul tarihi / Accepted: 16.04.2019

DOI:

İletişim Adresi/Corresponding Adress;

Bilgün Çetin

Selçuk Üniversitesi Diş Hekimliği

Fakültesi A blok Zemin Kat. Ağız,

Diş ve Çene Radyolojisi Selçuklu/

KONYA

E-posta/e-mail: bilgun_cetin@hotmail.com

INTRODUCTION

In all odontogenic cysts; radicular cyst is the most common cystic lesions of oral and maxillofacial region showing the highest incidence (1). It is mostly seen at the apices of the necrotic teeth. Radicular cyst is formed from the Malassez epithelial remnants in the periodontal ligament, due to inflammation caused by pulp infection (2). It is usually asymptomatic and detected incidentally on diagnostic radiographs obtained from the region (2). It appears as a well-defined, unilocular, radiolucent field on radiographs (3). The treatment of this cyst varies according to cyst size; enucleation, tooth extraction, root canal treatment or marsupialization (2).

On the other hand, dentigerous cyst is the most common developmental odontogenic cyst to appear. Also, its radiographic appearance has a well-defined unilocular and radiolucent area, however, the radiolucent area is always around an impacted tooth crown (4).

We aim to present an odontogenic residual radicular cyst case report that has three impacted anterior teeth and ruptured the cortical bone of mandibula base, even if the radiographic appearance looks more like odontogenic dentigerous cyst.

CASE

A 54-year-old male and systemically healthy patient was referred to Selcuk University, Dentistry Faculty, Oral and Maxillofacial Radiology Department because of inflammation and pus drainage in his mandibular symphysis region. He noticed a swelling and pus formation on his mandible symphysis region two weeks before coming to our clinic and he was referred to another dental clinic. The clinician diagnosed his condition as a dental abscess and prescribed antibiotics and anti-inflammatory drugs. After antibiotic therapy and extraction of a permanent incisor tooth (or very likely a persistent temporary incisor tooth), the pus started to come into the mouth from the alveolar socket; that is, the extraoral sinus tract had been healed.

In our clinic, firstly, intra-oral and extraoral examinations were performed; a horizontal slit on top of the anterior crest and pus drainage from the slit were observed when palpation was performed.

There was neither pain nor swelling and the adjacent teeth to the complaint area were vital (Figure 1).

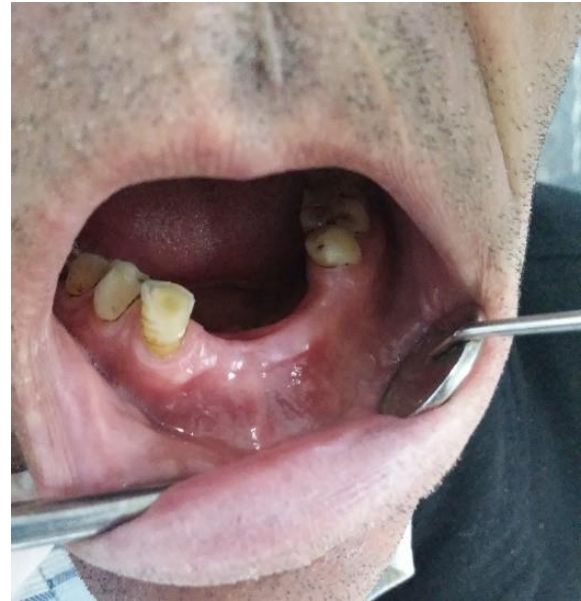

Figure 1: Intraoral photograph of the patient shows the slit on the top of alveolar crest

Furthermore, the sub-mental or the neck lymph nodes were not palpable and extra-oral examination was almost normal, but only the hard bone spur at the anterior base of the mandible was palpated (Figure 2).

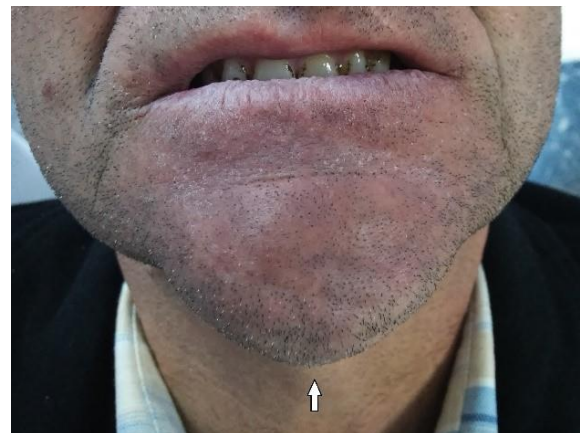

Figure 2: The extraoral photograph shows the palpable hard bone spur (white arrow)

Secondly, a periapical radiograph was taken from the complaint region, but unfortunately the radiograph was too insufficient to determine the lesion. For this reason, we decided to take panoramic radiograph. We observed a large radiolucent area on the mandibular anterior region with three unerupted incisor teeth and a continuity of the cortical bone at the base of the distorted mandible on the panoramic radiograph (Figure 3). After evaluating the image,

we believed that this image may be a dentigerous cyst and that it later infected and ruptured the mandibular basalis.

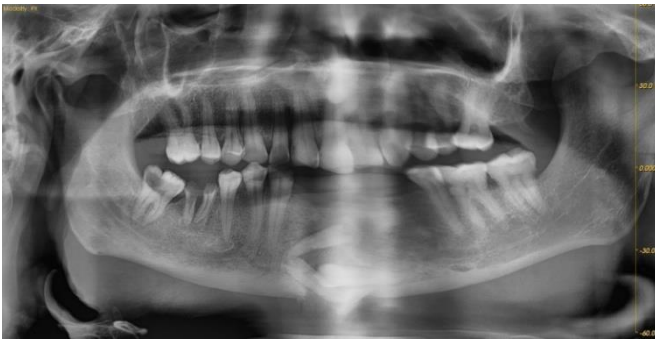


Figure 3: The panoramic radiograph shows cystic lesion with three impacted teeth

Finally, for surgery planning and determining the cysts borders completely, 3D images were required; thus, CT images were obtained. The images showed a well-defined unilocular, cystic lesion that reached from right canine tooth to the left canine region, with unerupted three teeth (Figure 4-5).

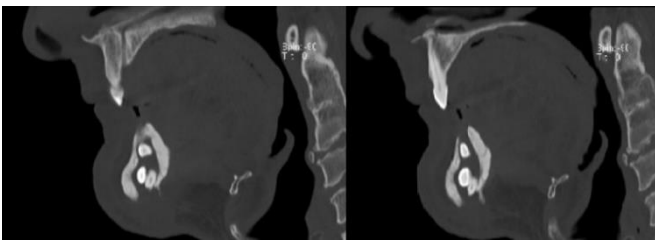


Figure 4: Sagittal sections of the CT images show the antero-posterior size of the ruptured cyst with impacted teeth

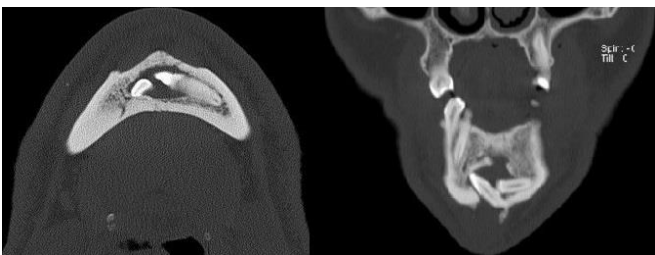


Figure 5: Axial section on the left side and coronal section on the right side of the CT images show impacted teeth and borders of the cyst

The cyst was enucleated and the impacted teeth were extracted. The enucleated tissue of the cyst was sent to the pathology laboratory of the Medical Faculty of Selcuk University for pathological examination.

The pathologic result was surprisingly ruptured residual radicular cyst and bone tissue with osteomyelitis.

The prognosis of the lesion was fairly good on a panoramic radiograph taken for control purpose 6 months later.

DISCUSSION

According to The World Health Organization's (WHO) current classification of odontogenic lesions (2017), two types of odontogenic cysts occur from inflammatory origin; these are radicular cyst and collateral inflammatory cyst (5). Radicular cyst is the most common odontogenic cyst, which also appears more frequently in the maxilla and the maxilla anterior region. It is mostly in the premolar and molar regions when such a lesion is found in the mandible (6). Its radiological appearance is a well-defined radiolucent, unilocular lesion. The term unilocular lesion, which also includes odontogenic cysts, is defined as a non-aggressive, slow-growing, benign intra-osseous image, which can assume an aggressive character when super infection occurs. Contrary to our case, unilocular intra-osseous lesions are rare in mandibular anterior and also among male patients (7). It has been reported that cysts grow and expand the cortical bone in some cases of radicular cyst (6,8). However, in our case, the mandibular basal cortical bone was resorbed by growing cyst instead of expansion. At the end of this event, the lesion was super infected and the content of the cyst began to drain out from the skin of inferior symphysis region. The cortical bone resorption is very rare since radicular cyst exhibits a benign behavior. Probably, the radical cyst in our case had been around for a very long time and it grew bigger without symptoms.

Radicular cyst, which is the appearance, size and presence of a non-vital tooth, can be easily distinguished from other similar lesions, such as apical granuloma and lateral periodontal cyst. However, the residual remains of the unilocular image of the cyst with the extraction of the non-vital tooth can be confused to be a developmental odontogenic cyst (1). In the current case, there were lots of confusing factors too, thereby making it

difficult to make differential diagnosis from dentigerous cyst. Definitive diagnosis was made by pathological test. Histopathologically, an inflamed connective tissue wall with lymphocyte infiltration, non-keratinized squamous cyst epithelium, and bone tissue with osteomyelitis were observed.

When the literature was searched; the observed cases of radicular cysts associated with the impacted teeth developed from pulpal infection of the maxillary deciduous teeth or from mandibular deciduous posterior teeth were common among younger individual patients (2,9,10,11,12), while the cyst with three impacted teeth in our case was in anterior mandible and the patient was an adult individual. Although we could not obtain clear information from the patient, it is not wrong to estimate that the cyst originated from any primary tooth that had been persistent for many years as a result of examining the radiograph and CT images and the surgically removed impacted permanent anterior teeth. Moreover, the permanent teeth may have become impacted because of the cyst, yet it could be also that a cyst developed from a permanent incisor, since there are no previous records before the other teeth were extracted.

In conclusion, it is possible to observe the odontogenic cysts without the usual images and symptoms. For this reason, every examination should be done with great care and diagnostic imaging should be used in every case that is suspected. Any possible situation should be taken into account when making differential diagnosis.

REFERENCES

- Martin LHC, Speight PM. Odontogenic cysts: an update. *Diagnostic Histopathology*. 2017; 23: 260-265
- Mahesh BS, Shastry SP, Murthy PS, Jyotsna TR. Role of Cone Beam Computed Tomography in Evaluation of Radicular Cyst mimicking Dentigerous Cyst in a 7-year-old Child: A Case Report and Literature Review. *Int J Clin Pediatr Dent*. 2017; 10: 213-216.
- Ramos-Perez FMM, Pontual AA, França TRT, Pontual MLA, Beltrao RV, Perez DEC. Mixed Periapical Lesion: An Atypical Radicular Cyst with Extensive Calcifications. *Brazilian Dental Journal*. 2014; 25: 447-450.
- Li N, Gao X, Xu Z, Chen Z, Zhu L, Wang J, Liu W. Prevalence of developmental odontogenic cysts in children and adolescents with emphasis on dentigerous cyst and odontogenic keratocyst (keratocystic odontogenic tumor). *Acta Odontologica Scandinavica*. 2014; 72: 1-6.
- Suluk-Tekkeşin M, Wright JM. The World Health Organization Classification of Odontogenic Lesions: A Summary of the Changes of the 2017 (4th) Edition. *Turkish Journal of Pathology*. 2018; 34: 1-18.
- Bava FA, Umar D, Bahseer B, Baroudi K. Bilateral Radicular Cyst in Mandible: An Unusual Case Report. *J Int Oral Health*. 2015; 7: 61-63.
- Mohanty S, Gulati U, Mediratta A, Ghosh S. Unilocular radiolucencies of anterior mandible in young patients: A 10 year retrospective study. *National Journal of Maxillofacial Surgery*. 2013; 4: 66-72.
- Martin L, Speight PM. Odontogenic cysts. *Diagnostic Histopathology*. 2015; 21: 359-369.
- Narsapur SA, Chinnanavar SN, Choudhari SA. Radicular cyst associated with deciduous molar: A report of a case with an unusual radiographic presentation. *Indian Journal of Dental Research*. 2012; 23: 550-553.
- Uloopi KS, Shivaji RU, Vinay C, Pavitra, Shrutha SP, Chandrasekhar R. Conservative management of large radicular cysts associated with non-vital primary teeth: A case series and literature review. *Journal of Indian Society of Pedodontics and Preventive Dentistry*. 2015; 33: 53-56.
- Castro LA, Maia SRC. Maxillary osteolytic lesion in a 10-year-old girl: A dentigerous or radicular cyst? A case report and discussion. *Rev Port Estomatol Med Dent Cir Maxillofac*. 2012; 53: 24-28.
- Gupta SS, Shetty DC, Urs AB, Nainani P. Role of inflammation in developmental odontogenic pathosis. *J Oral Maxillofac Pathol*. 2016; 20: 164-164.