

Complex Odontoma: A Case Report

Kompleks Odontoma: Bir Olgu Sunumu

ABSTRACT

Odontomas are the most common of the odontogenic tumors of the jaws. They are usually discovered on routine radiographical examinations during the second and third decades of life. They are characterized by their slow growth and no aggressive behavior. Based on radiographic and microscopic characteristic, odontomas are subdivided into compound and complex types. The compound odontoma forms multiple irregular tooth like structures. The complex type is characterized by dental tissues in a disorderly pattern without any anatomic resemblance to a tooth. The exact etiology is not well known, however, local trauma, infections and genetic factors have been suggested. Complex odontomas rarely erupt into the mouth. Despite their asymptomatic nature, their eruption into the oral cavity can give rise to pain, inflammation, infection and ulceration. Additionally large odontomas can cause cortical expansion, facial asymmetry and traumatic ulcers. Odontomas are treated by simple local excision. The purpose of this report is to present a case of complex odontoma in a 16 year old male patient.

Key words: Odontoma; complex odontoma; case report; cone beam computed tomography; panoramic radiography.

ÖZ

Odontomlar çenelerin en yaygın görülen odontojenik tümörleridir. Genellikle yaşamın ikinci ve üçüncü dekadında, rutin radyografik muayene sırasında tesadüfen keşfedilirler. Yavaş büyüyen ve agresif olmayan tümörlerdir. Radyografik ve mikroskopik özelliklerine göre ayrılan kompaund ve kompleks tipleri mevcuttur. Kompaund odontom, çok sayıda irregüler diş benzeri yapılar içerirken; kompleks odontom, diş dokularının düzensiz kitlesi şeklinde görülür. Etiyolojisi tam olarak bilinmemekle birlikte lokal travma, enfeksiyon ve genetik faktörlerin etkili olabileceği düşünülmektedir. Genellikle asemptomatik seyreden kompleks odontomlar, nadiren ağız içine sürerek ağrı, enflamasyon, enfeksiyon ve ülserasyona yol açabilir veya büyük boyutlara ulaştığında kortikal ekspansiyon, fasyal asimetri ve travmatik ülsera sebep olabilir. Odontomların tedavisinde basit eksizyon uygulanır. Bu çalışmanın amacı 16 yaşında erkek hastada görülen kompleks odontom vakası ile ilgili bilgi vermektir.

Anahtar Kelimeler: Odontom; kompleks odontom; olgu sunumu; konik ışınlı bilgisayarlı tomografi; panoramik radyografi.

Fatmanur Ketenci¹

ORCID: 0000-0002-9618-1082

Rüştü Gedik²

ORCID: 0000-0001-9688-6157

Ömer Fahrettin Göze³

ORCID: 0000-0002-6451-2967

1 Yeditepe Üniversitesi Diş Hekimliği
Fakültesi, Ağız, Diş ve Çene Radyolojisi
Anabilim Dalı,
İstanbul, Türkiye

2 Cumhuriyet Üniversitesi Diş Hekimliği
Fakültesi, Ağız Diş ve Çene Radyolojisi
Anabilim Dalı,
Sivas, Türkiye

3 Cumhuriyet Üniversitesi Tıp Fakültesi,
Patoloji Anabilim Dalı,
Sivas, Türkiye



Geliş tarihi / Received: 09.08.2019

Kabul tarihi / Accepted: 18.09.2019

DOI:

İletişim Adresi/Corresponding Adress:

Fatmanur Ketenci

Yeditepe Üniversitesi Diş Hekimliği

Fakültesi, Ağız, Diş ve Çene Radyolojisi AD,
İstanbul, Türkiye

E-posta/e-mail: fatmanur.ketenci90.fk@gmail.com

INTRODUCTION

Odontomas are the most common of the odontogenic tumours the jaws and are characterized by their slow growth and no aggressive behaviour. They are mixed tumours, consisting of both epithelial and mesenchymal cells, that present a complete dental tissue differentiation (enamel, dentin, cementum and pulp)(1).

Odontomas are considered a tumor-like malformation (hamartoma), not a true neoplasm (2). They are in variably asymptomatic and usually discovered on routine radiographical examinations during the second and third decades of life with no significant sex predilection (1,3). Based on radiographic and microscopic characteristics, odontomas are subdivided into compound and complex types. The complex type is characterized by dental tissues in a disorderly pattern without any anatomic resemblance to a tooth (2).

The exact a etiology is not well known, however, local trauma, infections and genetic factors have been suggested (4).

Odontomas generally consist of unerupted or impacted teeth and retained deciduous teeth. Although rare, but there may be spontaneous eruption of an odontoma into the oral cavity which leads to pain and inflammation of adjacent soft tissues (5). 70% of odontomas areas sociated with pathologic change such as impaction, malpositioning, aplasia, malformation and devitalization of adjacent teeth(6). Odontomas are treated by simple local excision and the prognas is excellent(7).

The purpose of this report is to present a case of complex odontoma in a 16 year old male patient.

CASE REPORT

A 16 year old male patient presented to Cumhuriyet University Faculty of Dentistry, Department of Oral and Maxillofacial Radiology for orthodontic treatment. The patient didn't have any diseases. Intraoral examination revealed missing mandibular right first molar tooth. A panoramic radiograph was acquired (by Kodak 8000 Digital Panoramic System, France with 73 kVp, 8mA, 13.8 seconds exposure parameters). The panoramic radiograph showed a multiple radiopaque mass surrounded by a thin radiolucent rim associated with the lower right third molar (Fig. 1).

The patient didn't have any pain or swelling. The first diagnostic hypothesis was a complex odontoma and CT scan was advised. Prior to the start of the study, the informed consent of his parents were obtained.

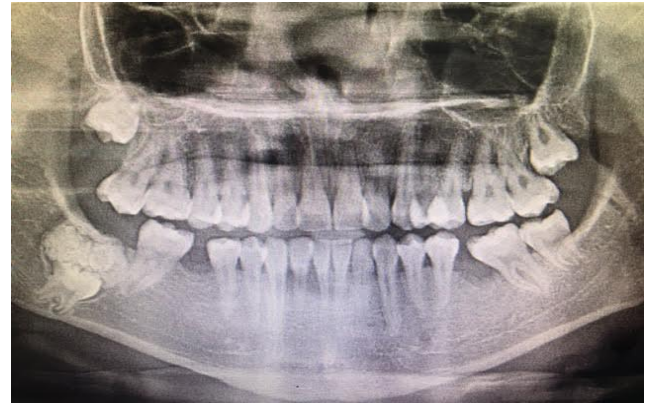

Fig. 1: Panoramic radiograph shows a multiple radiopaque mass surrounded by a thin radiolucent rim associated with the lower right third molar tooth.

A CT scan was obtained (by Planmeca Romexis machine, Finland with 90 kVp, 8mA, 13.5 seconds exposure parameters). The CT scan revealed the size and extent of the lesion in three dimensions (Fig. 2A,B,C,D). There was slight expansion in buccolingual direction. There was no evidence of soft tissue extension. Then the patient was referred to the Department of Oral Surgery for surgical treatment.

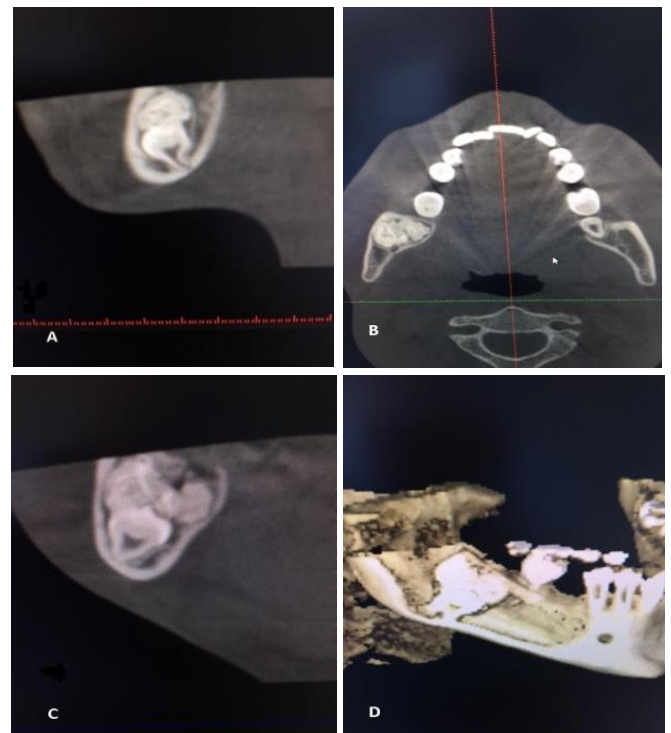


Fig. 2: A. Sagittal section of CBCT shows the relation of the impacted third molar tooth and the lesion. B. Axial section of CBCT shows a slight buccolingual expansion of the mandible. C. Coronal section of CBCT shows similar features of the axial and sagittal sections. D. Three-dimensional image of the lesion in the lateral view shows the lesion and the impacted tooth.

Under local anesthesia, the lesion was completely excised with the impacted third molar tooth. The specimen was sent for histopathological evaluation.

Histologic sections revealed miniature tooth structures and decalcification spaces in the alveolar bone (Fig. 3). It is also seen a fibrovascular core and odontoblasts around it (Fig. 4). Histopathologic examination confirmed the diagnosis of complex odontoma.

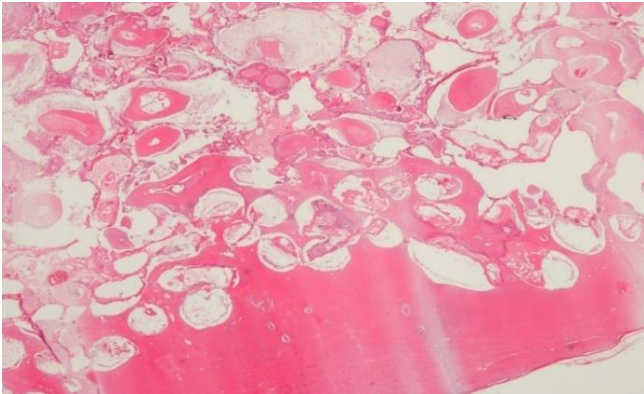


Fig. 3: A general view of the complex odontoma: It is seen miniature tooth structures and decalcification spaces in the alveolar bone (HE;X40).

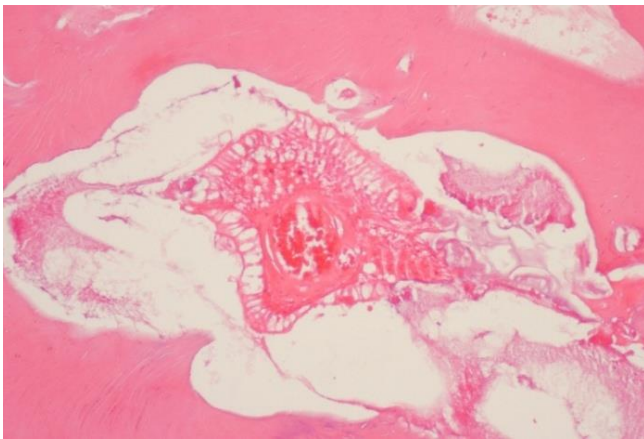


Fig. 4: A cellular detail of another field of the kompleks odontoma: It is seen a fibrovascular core (arrow mark) and odontoblasts around it.

DISCUSSION

Odontomas are benign tumors which contain various component tissues of the teeth and they are the most common odontogenic tumours which constitute 22% of all the odontogenic tumours of the jaws. There are two types of odontomas: complex odontomas and compound odontomas - the latter being twice as frequent as the former. Compound odontomas show a predilection in the anterior section of the upper maxilla, while complex odontomas are typically found in mandibular first and second molar region. Differently in this case, the complex odontoma was associated with the mandibular impacted third molar tooth. They may be discovered at any age, although less than 10% of them are found in patients over 40 years of age (1).

The compound odontoma forms multiple irregular tooth

like structures, whereas the complex odontoma forms amorphous calcification, with dysplastic dentin covered by enamel (8). 60% of complex odontomas occur in women (6), however in this case, the lesion was seen in male patient.

Complex odontomas are usually asymptomatic and are associated with change such as malformation, impaction, delayed eruption, malposition, cyst formation, displacement, resorption of the adjacent teeth and expansion of the cortical plate. In this case, the patient was asymptomatic, there was slight cortical expansion, the lesion prevented the eruption of the mandibular third molar tooth and all of these were compatible with the literature. Symptoms that may be present include numbness in the lower lip, frontal head aches, swelling in the affected areas and facial asymmetry.

The radiological appearance of complex odontomas depends on their development stage and degree of mineralization. The first stage is characterized by radiolucency due to a lack of calcification. Partial calcification is observed in the intermediate stage, while in the third stage, the lesion usually appears radiopaque with amorphous masses of the dental hard tissue surrounded by a thin radiolucent zone corresponding to the connective capsule histologically (9). We thought that our case was in the third stage. Because it was radiopaque with amorphous masses of the dental hard tissue and the radiolucent zone was surrounding the lesion.

Histologically the complex odontoma is characterized by sheets of immature tubular dentin with encased hollow tooth like structures. Ghost cells are especially seen in complex odontoma (6).

A differential diagnosis of complex odontoma must be established with lesion such as cementoblastoma, osteoidosteoma and cemento-ossifying fibroma.

A cementoblastoma presents as a well-defined radiopaque mass attached to the tooth root and surrounded by a radiolucent rim. Osteoid osteomas are characterized by a small ovoid or round radiolucent areas surrounded by a rim of sclerotic bone; the central radiolucency exhibits some calcification. Cemento-ossifying fibroma presents as a well-defined radiolucency with increasing flecks of calcification as it matures; it is not surrounded by a radiolucent rim and it is diffused with normal bone. Also, none of these is associated with an impacted tooth (3).

Complex odontomas rarely erupt into the mouth and tend to be associated with impacted teeth. Despite their benign nature, their eruption into the oral cavity can give rise to pain, inflammation, infection and ulceration but large odontomas can cause cortical expansion, facial

asymmetry and traumatic ulcers. Therefore it is important to diagnose these lesions as soon as possible and treat them appropriately as to avoid complications (9).

REFERENCES

1. Lakshmi Kavitha N, Venkateswarlu M, Geetha P. Radiological Evaluation of a Large Complex Odontoma by Computed Tomography. *J Clin Diagnostic Res.* 2011;5:1307-1330.
2. Santos L, Lopes L, Roque-Torres G, Oliveira V, Freitas D. Complex Odontoma: A Case Report with Micro-Computed Tomography Findings. *Case Reports in Dentistry.* 2016.
3. Chrcanovic BR, Jaeger F, Freire-Maia B. Two-Stage Surgical Removal of Large Complex Odontoma. *Oral and Maxillofacial Surgery.* 2010;14(4):247-252.
4. Kobayashi T, Gurgel C, Cota A, Rios D, Machado M, Oliveira T. The usefulness of cone beam computed tomography for treatment of complex odontoma. *European Archives of Paediatric Dentistry.* 2013;14(3):185-189.
5. Nisha D, Rishabh K, Ashwarya T, Sukriti M, Gupta S. An Unusual Case of Erupted Composite Complex Odontoma. *Journal of Dental Sciences and Research.* 2011;2(2):1-5.
6. Reddy G, Sidhartha B, Sriharsha K, Koshy J, Sultana R. Large Complex Odontoma of Mandible in a Young Boy: A Rare and Unusual Case Report. *Case Reports in Dentistry.* 2014.
7. Neville D, Allen, Bouquot. *Oral and Maxillofacial Pathology.* 3 ed. Missouri: Saunders Elsevier; 2009. p.724-725.
8. Sun L, Sun Z, Ma X. Multiple Complex Odontoma of the Maxilla and the Mandible. *Oral Surgery, Oral Medicine, Oral Pathology and Oral Radiology.* 2015;120(1):e11-e16.
9. Bagewadi SB, Kukreja R, Suma GN, Yadav B, Sharma H. Unusually Large Erupted Complex Odontoma: A Rare Case Report. *Imaging Science in Dentistry.* 2015;45(1):49-54.