

A case of acute renal failure requiring emergency hemodialysis due to hypothermia-associated rhabdomyolysis

Hipotermi ilişkili rabdomiyoliz nedeniyle acil hemodiyaliz ihtiyacı gelişen akut böbrek yetmezliği olgusu

Abdussamed Vural¹, Mehmet Ekiz¹, Mücahit Günaydın¹

¹ Giresun University, Medicine of School,
Emergency Medicine Department, Giresun,
Turkey

ORCID ID of the author(s)

AV: 0000-0003-4506-916X
ME: 0000-0002-9299-0018
MG: 0000-0002-2215-986X

Abstract

Hypothermia is described as a decrease in body temperature below 35 °C. Although the body reacts neuroendocrinally, behaviourally, and cardiovascularly against sudden changes in temperature, uncontrolled hypothermia can lead to severe complications such as rhabdomyolysis, acute renal failure, coma, coagulopathy, malignant cardiac arrhythmia, and cardiac collapse. Herein, we aimed to emphasize hypothermia, its serious complications such as rhabdomyolysis and related acute kidney injury in a 60-year-old male patient exposed to environmental cold.

Keywords: Emergency, Hemodialysis, Hypothermia, Rhabdomyolysis, Renal failure

Öz

Hipotermi vücut iç sıcaklığının 35 °C'nin altına düşmesi olarak tanımlanmaktadır. Çevredeki ani ısı değişimlerine karşı vücut nöroendokrin, davranışsal ve kardiyovasküler olarak tepki göstermekle birlikte kontrol altına alınamayan hipotermi rabdomiyoliz, akut böbrek yetmezliği, koma, koagülopati, malign kardiyak aritmi, kardiyak kollaps vb. ciddi komplikasyonlara neden olabilmektedir. Bu olgu sunumu ile soğuğa maruz kalan altmış yaşındaki erkek hastada gelişen hipotermi ve hipotermimin potansiyel komplikasyonlarına vurgu yapılmak istenmiştir.

Anahtar kelimeler: Acil, Hemodiyaliz, Hipotermi, Rabdomiyoliz, Böbrek yetmezliği

Introduction

Hypothermia occurs when the internal body temperature drops below 35 degrees [1-3]. According to the standard classification, hypothermia is classified as mild, moderate, and severe according to body core temperature being between 32-35 °C, 28-32 °C and <28 °C, respectively [4,5]. Although the body reacts neuroendocrinally, behaviorally, and cardiovascularly against sudden changes in temperature, uncontrolled hypothermia can lead to severe complications such as rhabdomyolysis, acute renal failure, coma, coagulopathy, malignant cardiac arrhythmia, and cardiac collapse. To date, several cases of acute renal failure requiring emergency hemodialysis after hypothermia due to rhabdomyolysis have been reported in the literature. In this respect, our case is remarkable.

Corresponding author / Sorumlu yazar:
Abdussamed Vural

Address / Adres: Giresun Üniversitesi Tıp
Fakültesi Acil Tıp Anabilim Dalı, Giresun,
Türkiye

E-mail: abdussamedvural@gmail.com

Informed Consent: The authors stated that the written consent was obtained from the patient presented with images in the study.

Hasta Onamı: Yazarlar çalışmada görüntüleri ile sunulan hastadan yazılı onam alındığını ifade etmiştir.

Conflict of Interest: No conflict of interest was declared by the authors.

Çıkar Çatışması: Yazarlar çıkar çatışması bildirmemişlerdir.

Financial Disclosure: The authors declared that this study has received no financial support.

Finansal Destek: Yazarlar bu çalışma için finansal destek almadıklarını beyan etmişlerdir.

Previous presentation: The study was presented as an oral presentation at the 15th Turkish Emergency Medicine Congress, November 21-24, 2019, Regnum Carya Convention Center, Antalya, Turkey

Published: 11/29/2020
Yayın Tarihi: 29.11.2020

Copyright © 2020 The Author(s)
Published by JOSAM

This is an open access article distributed under the terms of the Creative Commons Attribution-Non Commercial-NoDerivatives License 4.0 (CC BY-NC-ND 4.0) where it is permissible to download, share, remix, transform, and buildup the work provided it is properly cited. The work cannot be used commercially without permission from the journal.



Case presentation

A 60-year-old male patient with a history of chronic renal failure and a psychiatric problem (psychotic disorder without treatment) was transported to our emergency department by the 112 emergency team. We determined that the patient lived alone. After a fire, the patient, who had no protective clothing on him, was found semi-unconscious by the locals about 6 hours later. On the day of the incident, the weather in Giresun, a coastal province in Turkey that borders the Black Sea, was very cloudy, the coastal areas were rainy, the heights of the inner parts were snowy, and the highest temperature was 8 °C. The patient's general condition was poor when he was admitted to the emergency department. Glasgow coma scale value (GCS) of the patient was 14 (E4M6V4). The vital signs were as follows: Blood pressure: 110/70 mm-Hg, Heart Rate: 41 beats per minute (bpm), respiratory rate: 16 /minute, fever: 33.2 °C and finger blood glucose: 150 mg/dl. On neurological examination, he was confused, and his in-depth tendon reflex examination was hypoactive. In other systemic examinations, respiratory sounds were mildly coarse, heart sounds were (S1 + S2 +) rhythmic and bradycardic, and abdominal examination was normal. The patient had dry and hard skin, stiffness in body muscles, and severe sensitivity to touch after prolonged exposure to cold. No tremor was detected. There was mild cyanosis, bruising, and severe pain in bilateral foot and toes, more prominent in the first and second fingers of the right foot.

In the pre-hospital period, the body temperature was not measured, and the patient was given passive external heating with the help of heat bags and blankets by 112. During hospitalization, the patient was provided active external heating with a forced-air warming system through the blanket and minimally invasive heating with intravenous fluid support heated to 40-42 °C and bladder lavage. The patient's body core temperature increased to 36.2 °C within 30 minutes after heating supports.

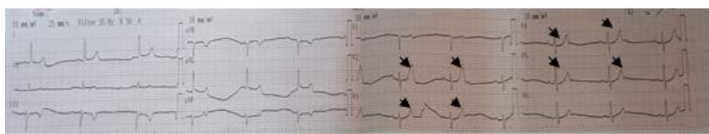


Figure 1: The patient's ECG at admission time to the emergency department, Electrocardiography (ECG) revealed sinus bradycardia (41 bpm) and peaked T waves (black arrows) more prominent in anterior leads (V2 - V5)

Electrocardiography (ECG) revealed sinus bradycardia (41 bpm), and peaked T waves more prominent in chest leads (Figure 1). There was no pathology in the chest radiograph. In the laboratory findings, the blood urea level was higher than 455 mg/dl, creatinine was 7.61 mg/dl, creatine kinase (CK) level was higher than 2149 U/L and potassium level was 8.23 mmol/L. These findings were in favor of acute renal failure (ARF) and rhabdomyolysis. In the blood gas analysis, Ph, PCO₂, HCO₃, were in favor of severe metabolic acidosis with an increased anion gap. The patient's laboratory findings are summarized in Table 1 A, B. The patient had acute renal failure associated with rhabdomyolysis, which is based on chronic renal failure. Therefore, emergency hemodialysis support was given in two sessions (3 hours at the first session and 2 hours at the second session). After one week of follow-up, the patient was discharged without sequelae. Informed consent for treatment was

assumed through the doctrine of implied consent, and also verbal consent was obtained from the patient for the study.

Table 1: Laboratory findings of the patient admitted to the emergency department

A) Patient's hemogram and biochemistry results		Reference range
WBC (/L)	26.42 x 10 ⁹	4.3-10.3 X 10 ⁹
Platelet (/L)	188 x 10 ⁹	150-400 x10 ⁹
HCT (%)	47.7	41-53
AST (U/L)	24	<40
ALT (U/L)	6	<40
PT (s)	15.8	10-14
aPTT (s)	34.7	23-35
D-Dimer (ng/ml)	3337	<500
LDH (U/L)	281	135-225
CK (U/L)	>2149	39-308
urea(mg/dL)	>455	15-42
Creatinine(mg/dL)	7.61	0.7-1.2
Amylase(U/L)	116	28-100
Calcium(mg/dL)	9.9	8.5- 10.2
Sodium(mEq/L)	138	135-145
Potassium(mEq/L)	8.23	3.5-5.5
Glucose (mg/dL)	150	70-110
B) Other laboratory findings		Reference range
Venous Blood Gas		
Ph	7.129	7.35-7.45
PCO ₂ (mm-Hg)	38.7	35-45
PO ₂ (mm-Hg)	32.9	80-100 (arterial blood gas)
HCO _{3act} (mmol/L)	12.6	22-26
HCO _{3std} (mmol/L)	12.1	22-26
AnGap (mEq/L)	29.6	8-16
Lactate(mmol/L)	4.97	<2
Blood ethanol level (mg/dL)	<0.1	Negative
Urine	Dark, concentric	

AnGap: Anion Gap, WBC: White blood cell, HCT: hematocrit, AST: Aspartate aminotransferase, ALT: Alanine aminotransferase, PT: Prothrombin time Aptt: Activated partial thromboplastin time, LDH: Lactate dehydrogenase, CK: Creatine kinase

Discussion

In our case, the temperature of the patient was measured as 33.2 °C. According to the classical description, the degree of hypothermia of the patient was Stage 1 (mild). However, we believe that the hypothermia of the patient was Stage 2 (moderate) based on the patient's severe clinical findings and since the emergency team immediately began to warm the patient. Hypothermia-related deaths are associated with some risk factors including advanced age (>65 years), male gender, falls, cold environment, insufficient protective clothing, a history of drug use that changes consciousness, and cardiovascular diseases [5,6]. In parallel, there were the risk factors mentioned above related to hypothermia in our patients.

There are many causes of rhabdomyolysis leading to acute renal failure but drug abuse, alcohol intoxication, and compression injuries are the most common causes of rhabdomyolysis [7]. In rare cases, hypothermia may cause rhabdomyolysis due to excessive tremor, prolonged vasoconstriction, and profound hypoxia [8]. Rhabdomyolysis also developed in our patient as a result of prolonged tremor and immobilization after exposure to cold.

There are a few cases of hypothermia-related rhabdomyolysis in the literature [9,10]. Similar to our case, Chase et al. [8] reported that a 29-year-old male patient who developed rhabdomyolysis after accidental hypothermia was discharged with only heating techniques. In our case, however, the patient was provided active external heating with a forced-air warming system through the blanket, minimally invasive heating with intravenous fluid support heated to 40-42 °C and bladder lavage. Moreover, emergency hemodialysis was performed.

Conclusion

Hypothermia is a life-threatening condition. Early recognition and rapid treatment of this clinical condition are vital to prevent complications. Also, rhabdomyolysis and acute renal failure should be considered as potential complications in patients presenting with hypothermia.

References

1. Hanania NA, Zimmerman JL. Accidental hypothermia. *Crit Care Clin.* 1999 Apr;15(2):235-49. doi: 10.1016/s0749-0704(05)70052-x. PMID: 10331126.
2. van der Ploeg GJ, Goslings JC, Walpoth BH, Bierens JJ. Accidental hypothermia: rewarming treatments, complications and outcomes from one university medical centre. *Resuscitation.* 2010 Nov;81(11):1550-5. doi: 10.1016/j.resuscitation.2010.05.023. Epub 2010 Aug 11. PMID: 20702016.
3. Brown DJ, Brugger H, Boyd J, Paal P. Accidental hypothermia. *N Engl J Med.* 2012 Nov 15;367(20):1930-8. doi: 10.1056/NEJMr1114208. Erratum in: *N Engl J Med.* 2013 Jan 24;368(4):394. PMID: 23150960.
4. Danzl DF, Pozos RS. Accidental hypothermia. *N Engl J Med.* 1994 Dec 29;331(26):1756-60. doi: 10.1056/NEJM199412293312607. PMID: 7984198.
5. Biem J, Koehncke N, Classen D, Dosman J. Out of the cold: management of hypothermia and frostbite. *CMAJ.* 2003 Feb 4;168(3):305-11. PMID: 12566336; PMCID: PMC140473.
6. Baumgartner EA, Belson M, Rubin C, Patel M. Hypothermia and other cold-related morbidity emergency department visits: United States, 1995-2004. *Wilderness Environ Med.* 2008 Winter;19(4):233-7. doi: 10.1580/07-WEME-OR-104.1. PMID: 19099327.
7. Bomor R, Siddiqui M, Ahuja TS. Rhabdomyolysis associated with near-drowning. *The American Journal of the Medical Sciences.* 1999 Sep;318(3):201-2. DOI: 10.1097/0000441-199909000-00018.
8. Chase CD, Smith RA. Hypothermia-induced Rhabdomyolysis: A Case Report. *J Emerg Med.* 2015 Dec;49(6):e177-8. doi: 10.1016/j.jemermed.2015.07.015. Epub 2015 Sep 26. PMID: 26416131.
9. Dearing N, Norgard NB. Rhabdomyolysis in a patient receiving high-dose simvastatin after the induction of therapeutic hypothermia. *Ann Pharmacother.* 2010 Dec;44(12):1994-7. doi: 10.1345/aph.1P352. Epub 2010 Nov 2. PMID: 21045169.
10. Hung CF, Huang TY, Lin PY. Hypothermia and rhabdomyolysis following olanzapine injection in an adolescent with schizophreniform disorder. *Gen Hosp Psychiatry.* 2009 Jul-Aug;31(4):376-8. doi: 10.1016/j.genhosppsy.2008.09.009. Epub 2008 Oct 18. PMID: 19555799.

This paper has been checked for language accuracy by JOSAM editors.

The National Library of Medicine (NLM) citation style guide has been used in this paper.