



■ Case Report

Successful cervical cerclage in a pregnant woman with a large cervical myoma

Dev servikal myomu olan gebelikte başarılı servikal serklaj uygulanması

*Yunus Emre Topdağı¹ , Emsal Pınar Topdağı Yılmaz² , Seray Kaya Topdağı² , Ali İrfan Güzel³ 

¹Sanko University School of Medicine, Department of Obstetrics and Gynecology, Gaziantep, Turkey

²Atatürk University School of Medicine, Department of Obstetrics and Gynecology, Erzurum, Turkey

³ Private Doctor, Izmir, Turkey

Abstract

Cervical insufficiency or early cervical dilation is a fundamental cause of second-trimester pregnancy loss. Cervical cerclage is the principal treatment for women with cervical insufficiency. Uterine myoma is the most common benign gynaecologic tumour, occurring in approximately 20% of reproductive age women, whereas uterine cervical myoma is rare and constitutes 5% of all myomas. One of the most important aetiological factors for premature labour is cervical insufficiency. Emergency cerclage can be effective, although according to the literature cerclage placement as a means of prolonging the duration of pregnancy has provided conflicting results. Here, we aimed to present successful implementation of cerclage process in a pregnant patient with a large cervical myoma.

Key words: Emergency cerclage; cervical myoma; cervical insufficiency

Öz

Servikal yetmezlik veya erken servikal dilatasyon ikinci trimester gebelik kaybının önemli bir nedenidir. Servikal serklaj servikal yetmezlik olan kadınlar için temel tedavidir. Uterin myom üreme çağındaki kadınların yaklaşık %20'sinde görülen en sık benign jinekolojik tümördür, servikal myom ise nadirdir ve tüm myomların %5'ini oluşturur. Prematüre doğum için en önemli etiyolojik faktörlerden biri servikal yetmezliktir. Literatüre göre serklaj uygulamasının gebelik sürelerini uzatmadaki sonuçları çelişkili bildirilmekle birlikte, acil serklaj hamilelik süresini uzatmada etkilidir. Bu olguda, büyük servikal myomu olan gebede başarılı bir şekilde serklaj uygulanmasını sunmayı amaçladık.

Anahtar Kelimeler: Acil serklaj; servikal myom; servikal yetmezlik

Corresponding Author*: Yunus Emre Topdagi, Sanko University School of Medicine, Department of Obstetrics and Gynecology, 27090, Gaziantep, Turkey
e-mail: emr-topdagi@hotmail.com

ORCID: 0000-0003-0656-0765

Received: 24.05.2020 Accepted: 17.09.2020

DOI: 10.46969/ezh.742146

1. Introduction

The concept of cervical insufficiency classically refers to a painless cervical opening in the second trimester. Cervical insufficiency or early cervical dilation is a predominant factor in second-trimester pregnancy loss and preterm birth (1). Cervical cerclage is the principal treatment for women with cervical insufficiency; it is recommended to perform a cerclage in high-risk women when transvaginal sonography shows cervical shortening <25 mm (1). There are two types of cerclage, the McDonald and Shirodkar. There is no consensus on how late the procedure can be performed during pregnancy (2).

Uterine myoma, also known as a leiomyoma or fibroid, is the most common benign gynaecologic tumour occurring in approximately 20% of reproductive age women, whereas uterine cervical myoma is rare and constitutes 5% of all myomas (3). Cervical myomas are classified as type 8 according to the International Federation of Gynecology and Obstetrics classification, arising from the muscular structure of the cervix instead of the uterine corpus. These can grow into both the parametrium and vagina (4). Myometrial prevalence in pregnancy usually ranges from 0.1% to 3.9%, but in some studies is reported as high as 10.7% (5, 6). Although leiomyomas can cause a wide variety of symptoms, they are mostly asymptomatic. Symptoms depend on the location, size and number of leiomyomas (7). Uterine leiomyoma is associated with preterm delivery, stillbirth and ectopic pregnancy. If a leiomyoma is close to the placental region, the incidence of pregnancy-related complications increases. Complications include bleeding, pain, premature labour and postpartum haemorrhage. Small fibroids in pregnancy do not usually cause symptoms, and there is no need for surgery. However, successful myomectomy procedures during pregnancy have been reported (8).

In this case report, we report the use of cerclage in a pregnant woman with a large cervical myoma and discuss the current literature.

2. Case report

A 25-year-old woman was admitted to our clinic with a history of inguinal and abdominal pain in the 21st week of her first pregnancy. The patient permitted her medical data and images to be used if needed. She had experienced pain and brown vaginal spotting for two days. She had no systemic disease or history of surgery but was previously known to have a cervical myoma. Transvaginal ultrasonography detected a large cervical myoma approximately 10 × 11 cm in size (**Figure 1**). Fetal measurements were consistent with a 21-week pregnancy on

obstetric ultrasonography. Fetal movements and cardiac activity were positive. The amniotic fluid was normal. The cervical canal length could not be clearly evaluated due to the cervical myoma. On vaginal examination, the cervix was 3 cm dilated and 50–60% effaced. Biochemical and urinalysis tests were within normal limits. No fetal anomaly was detected on ultrasonography, and it was decided to perform an emergency cervical cerclage. The major problem was the large myoma in the cervical canal. A McDonald cerclage technique was performed; the cervix was sutured with a mersilene type cerclage suture at the 4-7-12 positions. Prophylactic antibiotherapy was initiated, tocolysis was administered, and the patient was hydrated. At about 33 weeks gestation, the patient started the early stages of labour, and because the birth canal was closed by the cervical myoma, caesarean section was performed, with the safe birth of a 2250 g baby. The myoma was not removed due to its location and the risk of bleeding during the caesarean section.

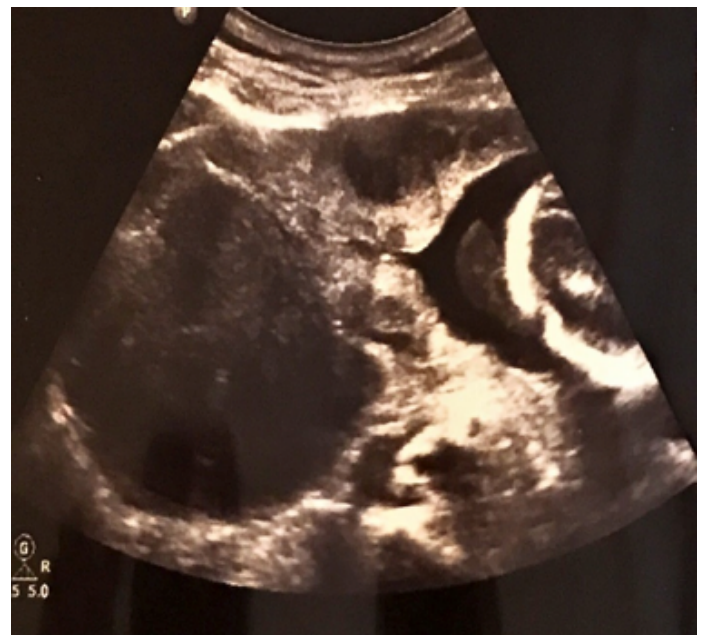

Figure 1. Ultrasonographic image of a 10 × 11 cm myoma in the cervix. Although the procedure was complicated due to the large cervical myoma in this patient who had developed cervical insufficiency, the McDonald cerclage procedure was successful.

3. Discussion

Reviewing the literature, cerclage procedures for the treatment of cervical insufficiency have varying success rates. A shortened cervix is a strong indicator of preterm delivery in women with singleton and twin pregnancies; the shorter the cervical length, the higher the risk of spontaneous preterm delivery was reported (9). In a systematic review, the perinatal results after



cerclage were more successful in women who did not have a previous history (10). When cerclage results were evaluated, there was an 86% success rate with elective cerclage in 2662 patients in 22 studies (11). In a study conducted by Owen et al. (12), approximately one-third of pregnant women gave birth before 35 weeks gestation, and fewer surgical complications were observed. As Karl and Katz (13) stated that it was vital to place the sutures as high as possible and tight into the cervical stroma. In the presence of a cervical myoma, it becomes challenging to perform the procedure. Tilting the operating table head down and inflating the bladder with 600 mL of saline via a Foley catheter can facilitate the procedure.

Uterine leiomyoma significantly increases the risk of spontaneous abortion. In a study by Buttram and Reiter (7) the rate of abortion was 41% in uterine leiomyoma patients, and this rate decreased to 19% after myomectomy. Uterine leiomyomas tend to grow in pregnancy, display involution in the third month postpartum, and usually return to their pre-pregnancy dimensions (14). Leiomyomas can cause an obstruction and a dysfunctional birth process, leading to presentation anomalies. Postpartum severe bleeding may be seen with submucous leiomyomas, and a hysterectomy may be necessary for control of the haemorrhage. It is crucial to keep in mind that adhesions can cause infertility. Therefore, myomectomy should be performed in selected cases such as spontaneous abortions and premature births if this is considered a cause of infertility (15). In our patient, myomectomy was not performed due to the risk for the patient before pregnancy. However, successful myomectomy operations in pregnancy have been reported (8). Differences in outcome may be due to inaccurate assessment of the gestational weeks, the selected cerclage technique, timing of the procedure and infection of the amniotic cavity (16, 17). Despite the difficulty of this procedure, cerclage was successfully performed in this 21 weeks pregnant woman at high risk of preterm delivery.

Declaration of Interest

The authors declare no conflict of interest.

References

1. Cunningham GF, Leveno KJ, Bloom SL et al. Williams Obstetrics, Twenty-Fifth Edition, 2018.
2. Cockwell HA, Smith Gn. Cervical incompetence and role of emergency cerclage. *J Obstet Gynaecol Can* 2005; 27:123-129.
3. Matsuoka S, Kikuchi I, Kitade M, et al. Strategy for laparoscopic cervical myomectomy. *J Minim Invasive Gynecol* 2010; 17:301-305.
4. Munro MG, Critchley HOD, Fraser IS, FIGO Menstrual Disorders Working Group. The FIGO classification of causes of abnormal uterine bleeding in the reproductive years. *Fertil Steril* 2011; 95:2204-2208.
5. Khaund A, Lumsden MA. Impact of fibroids on reproductive function. *Best Pract Res Clin Obstet Gynaecol* 2008; 22:749-760.
6. Laughlin, SK, Baird DD, Savitz DA, Herring AH, Hartmann KE. Prevalence of uterine leiomyomas in the first trimester of pregnancy: an ultrasound-screening study. *Obstet Gynecol* 2009; 113:630-635.
7. Buttram VC, Reiter RC. Uterine leiomyomas: etiology, symptomatology, and management. *Fertil Steril* 1981; 36:433-445.
8. Kilpatrick, CC, Adler MT, Chohan L. Vaginal myomectomy in pregnancy: a report of two cases. *South Med J* 2010; 103:1058-1060.
9. O'Hara, S, Zelesco M, Sun Z. Cervical length for predicting preterm birth and a comparison of ultrasonic measurement techniques. *Australas J Ultrasound Med* 2013; 16:124-134.
10. Ehsanipoor R, Selligman N, Szymanski LI, Wissinger C, Werner E, Berghella V. Physical exam indicated cerclage versus expectant management: a systematic review and metaanalysis. *Am J Obstet Gynecol* 2013; 208:S76.
11. Şen C, Çelik E. Erken doğumun önceden belirlenmesi. *Perinatoloji Dergisi* 2002; 10:88-89.
12. Owen J, Hankins G, Iams JD, et al. Multicenter randomized trial of cerclage for preterm birth prevention in high-risk women with shortened midtrimester cervical length. *Am J Obstet Gynecol* 2009; 201:375.e1-8.
13. Karl K, Katz M. A stepwise approach to cervical cerclage. *OBG Manag* 2012; 24:30-37.
14. Rock AJ, Jones WH (eds). *Te Linde's Operative Gynecology* 9th ed. Chap 30. Philadelphia: Williams & Wilkins Lippincott 2003; 753-798.
15. Wallach E, Vu K. Myomata uteri and infertility. *Obstet Gynecol Clin North Am* 1995; 22:791-799.
16. Sapmaz E, Çelik H, Altıngül A. Servikal yetmezlik vakalarında acil ve elektif serklaj operasyonu. *Türkiye Klinikleri J Gynecol Obst* 2001; 11:314-318.
17. Vidaeff AC, Ramin SM. From concept to practice: the recent history of preterm delivery prevention. Part II: Subclinical infection and hormonal effects. *Am J Perinatol* 2006; 23:75-84.