

Effects of Semi-Fowler Position on Cerebral Oxygenation During Thyroidectomy

Tiroidektomi Sırasında Semi Fowler Pozisyonunun Serebral Oksijenizasyona Etkileri

¹Ferda Yaman, ²Faruk Pehlivanlı, ³Gulcin Aydın

¹Department of Anesthesiology and Reanimation, Eskisehir Osmangazi University Faculty of Medicine, Eskisehir, Turkey

²Kirikkale University, Department of General Surgery, Faculty of Medicine, Kirikkale, Turkey

³Kirikkale University, Department of Anesthesiology and Reanimation, Faculty of Medicine, Kirikkale, Turkey

Abstract: Patients are positioned with hyperextension of head and neck at Semi-Fowler state during general anaesthesia to facilitate the surgical procedure. We aimed to determine the changes of serebral oxygenation in this position during thyroidectomy surgery. 22 patients were recruited prospective observational study. Cerebral oxygenation were monitored, left and right cerebral regional oxygen saturation were measured continuously. Heart rate, mean arterial pressure, end-tidal carbondioxide were measured and evaluated at baseline, after positioning at 15th, 30th, 90th minutes and after surgery at corrected position. After 90 minutes, significant decrease was seen cerebral oxygenization right side compared to the baseline ($p < 0.05$). 30th minute cerebral oxygenization right value decreased significantly compared to the 15th minute. 30th minute, cerebral oxygenization left value decreased significantly compared to 15 minutes ($p > 0.05$). 90th minute cerebral oxygenization left value decreased significantly compared to the 30th minute ($p < 0.05$). Significant decrease in cerebral oxygen saturation in both cerebral sides had been shown in relation to prolonged surgery time. Cerebral oxygenation was effected by the position given for thyroidectomy surgery. High-risk patients can be detected by regional cerebral oxygen saturation and prevent cerebral ischemia. Precautions should be taken for high-risk patients.

Keywords: Cerebral oxygenation; Thyroidectomy; Semi-Fowler position; General anesthesia

Özet: Cerrahi prosedürü kolaylaştırmak için hastalara genel anestezi sırasında, Semi-Fowler durumunda baş ve boynun hiperektansiyona getirilerek pozisyon verilir. Bu çalışmada tiroidektomi cerrahisi sırasında bu pozisyonda serebral oksijenizasyondaki değişiklikleri belirlemeyi amaçladık. 22 hasta prospektif gözlemsel çalışmaya dahil edildi. Serebral oksijenizasyon monitorize edildi, sol ve sağ serebral bölgesel oksijen saturasyonları devamlı ölçüldü. Kalp hızı, ortalama arteriyel basınç, end-tidal karbondioksit değerleri ve başlangıçta, 15., 30., 90. dakikalarda ve ameliyat sonrası düzeltilmiş pozisyonda değerlendirildi. 90 dakika sonra, bazal değer ile karşılaştırıldığında sağ serebral oksijenizasyonda anlamlı düşüş görüldü ($p < 0.05$). 30. dakika serebral oksijenizasyon değeri, 15. dakikaya göre anlamlı olarak düştü. 30. dakikada sol serebral oksijenizasyon değeri 15 dakikaya göre anlamlı olarak düştü ($p < 0.05$). 90. dakika sol serebral oksijenizasyon değeri 30. dakikaya göre anlamlı olarak azaldı ($p < 0.05$). Her iki serebral tarafta da serebral oksijen saturasyonunda belirgin azalma, uzamış cerrahi süresi ile ilişkili olarak gösterilmiştir. Tiroidektomi cerrahisi için verilen pozisyon serebral oksijenasyonu etkiler. Yüksek riskli hastalarda pozisyonun etkileri bölgesel serebral oksijen saturasyonu ile belirlenebilir ve serebral iskemi önlenir. Yüksek riskli hastalar için önlemler alınmalıdır.

Anahtar Kelimeler: Serebral oksijenizasyon; Tiroidektomi; Semi-Fowler position; Genel anestezi

ORCID ID of the author: F.Y 0000-0001-6847-1720, F.P 0000-0002-2175-8756, G.A 0000-0001-9672-7666

Received 18.05.2020

Accepted 01.06.2020

Online published 22.06.2020

Correspondence: Ferda YAMAN - Department of Anesthesiology and Reanimation, Eskisehir Osmangazi University Faculty of Medicine, Eskisehir, Turkey
e-mail: ferdayaman@gmail.com

Cite this article as:

Yaman F, Pehlivanlı F, Aydın G. Effects of Semi-Fowler Position on Cerebral Oxygenation During Thyroidectomy, Osmangazi Journal of Medicine, 2020;42(6):645-651 Doi: 10.20515/otd.739333

1. Introduction

Near-infrared spectroscopy (NIRS) has been used to monitor regional cerebral oxygen saturation (rScO₂). The measurement of cerebral oximetry that has been shown to determine cerebral ischemia (1). NIRS is non-invasive, accessible device and often used intraoperatively to provide patient safety from related with a high risk of neurologic complications. Cerebral oxygenation depends on blood pressure and cerebral perfusion, which are challenged by postural changes (2). Regardless of surgical operation, the patient's surgery position, cerebral oxygenation and perfusion is important. Autoregulation provides the cerebral blood perfusion by intra-cerebral collateral flow and maintain the cerebral oxygenation nevertheless Semi-Fowler position with hyperextension of head and neck may be provoked the cerebral ischemia if the collateral flow is insufficient (3). In the assessment the oxygen levels of cerebral tissue, benefits of NIRS had been shown in different studies such as cardiac surgeries, hypotensive long-term follow-up in surgeries and shoulder surgeries (4,5). Intraoperative cerebral desaturation events may result with neurocognitive complications.

Thyroidectomy surgery is performed in Semi-Fowler position with hyperextension of the head.

The aim of this study was to use NIRS technology to determine whether rScO₂ is affected by Semi-Fowler position and head hyperextension.

2. Methods

22 patients were enrolled after the approval of the Regional Scientific Ethics Committee (No:15/06) with signed written informed consent forms. Patients at the age of 18-65 who were planned to be operated for thyroidectomy under general anesthesia were included this prospective observational study. Patients who had hypertension, severe pulmonary disease, anaemia, cardiac disease, ischaemic cerebrovascular disease, renal disease, hepatic disease, pregnancy, uncontrolled diabetes mellitus were excluded the study.

All patients were euthyroid at the preoperative period. No premedication was administered before the anaesthesia procedure. At the operating room before induction of anesthesia, standard monitoring peripheral oxygen saturation, non-invasive blood pressure, electrocardiogram were performed. The monitorisation of cerebral oxygen saturation was performed by connecting the pads on the forehead of the patient over the right (RSO₂) and left (LSO₂) frontal regions, 1 cm lateral to the midline and distant from the temporalis muscle and 1 cm above the eyebrow by cerebral oximeter (INVOS, Somanetics Corporation, Troy, MI, USA). After 10 minutes in a supine position, baseline values were noted, including hemodynamic parameters such as heart rate (HR), mean arterial pressure (MAP) and peripheral and cerebral regional oxygen saturation (SpO₂, rSO₂). End-tidal carbon dioxide (EtCO₂) was also monitored. General anaesthesia was administered by a standardized protocol. Propofol 2-3 mg kg⁻¹, neuromuscular block to intubate; rocuronium 0.6 mg kg⁻¹ and fentanyl 2 µg kg⁻¹ were performed for induction of anesthesia. Maintenance of anesthesia was obtained by 2% sevoflurane in 40% oxygen with 60% air. Patients were positioned hyperextension of the neck and head at a 30-45 degree of angle of Semi-Fowler position. Measurements were noted after 15 (T₂), 30(T₃), 60(T₄) minutes after positioning and at the end of the operation after the Semi-Fowler position was neutralised before the extubation of patient (T₅). Five series of measurements were obtained.

Statistical Methods

Mean, standard deviation, median, minimum, maximum value, frequency and percentage were used for descriptive statistics. Paired samples t test and Wilcoxon test were used for the repeated measurement analysis. SPSS 26.0 was used for statistical analyses.

3. Results

Demographic data is presented in Table 1 together with values of Hemoglobin,

Hematocrite and length of surgery. Right cerebral oxygenization was compared the baseline at the times after 15 minutes, 30 minutes and the end of the surgery when corrected position (supine) did not change significantly ($p > 0.05$). After 90 minutes, significant drop was seen cerebral

oxygenization right compared to the baseline ($p < 0.05$). 30th minute cerebral oxygenization right value decreased significantly compared to the 15th minute ($p < 0.05$). When the position corrected, cerebral oxygenization right value changed in to higher, significantly ($p < 0.05$) compared to 90 minutes. (Table 2).

Table 1. Demographic data, levels of hemoglobin and hematocrit, duration of surgery

	Min-Max	Median	Mean±s.d./n-%
Age	28.0 - 67.0	48.0	49.2 ± 8.6
Female			18.0 86%
Male			3.0 14%
Weight	60.0 - 100.0	80.0	78.5 ± 11.7
Height	153.0 - 174.0	160.0	161.9 ± 5.6
BMI	23.0 - 36.3	29.7	30.0 ± 4.3
Hemoglobin	10.4 - 16.7	13.7	13.7 ± 1.3
Hematocrit	29.6 - 50.0	42.7	41.7 ± 4.9
Duration Of Surgery	85.0 - 354.0	156.0	166.0 ± 60.3

Table 2. The changes in right cerebral oxygenation compared to the preoperative period

	Min-Max	Median	Mean±s.d.	p*	p**
<i>Cerebral Oxygenization Right</i>					
Baseline	57.0 - 89.0	73.0	72.3 ± 9.6		
15 Minute	44.0 - 90.0	69.0	68.4 ± 10.7	0.125 ^E	
30 Minute	44.0 - 82.0	69.0	68.1 ± 9.2	0.068 ^E	0.851 ^E
90 Minute	42.0 - 80.0	68.0	67.4 ± 9.5	0.047 ^E	0.447 ^E
Correct Position	50.0 - 85.0	70.0	70.3 ± 8.2	0.289 ^E	0.202 ^E

^E Paired samples t test

p* Difference with baseline / p** Difference with previous measurement

After 15 minutes, 30 minutes, 90 minutes, corrected position, cerebral oxygenization left value did not change significantly compared to baseline ($p > 0.05$). 30th minute, cerebral oxygenization left value decreased significantly compared to 15 minutes ($p <$

0.05). 90th minute cerebral oxygenization left value decreased significantly compared to the 30th minute ($p < 0.05$). When the position corrected, cerebral oxygenization left value increased significantly compared to 90 minutes ($p < 0.05$). (Table 3)

Table 3. The changes in left cerebral oxygenation compared to the preoperative period

	Min-Max	Median	Mean±s.d.	p*	p**
<i>Cerebral Oxygenization Left</i>					
Baseline	58.0 - 90.0	70.0	70.3 ± 8.1		
15 Minute	43.0 - 90.0	70.0	71.1 ± 9.3	0.727 ^E	
30 Minute	44.0 - 92.0	68.0	69.1 ± 10.0	0.590 ^E	0.104 ^E
90 Minute	45.0 - 94.0	69.0	68.5 ± 10.6	0.417 ^E	0.512 ^E
Correct Position	57.0 - 95.0	71.0	72.3 ± 10.1	0.310 ^E	0.080 ^E

^E Paired samples t test
 p* Difference with baseline / p** Difference with previous measurement

Cerebral Oxygenation Right and Left figured in figure 1 and 2, respectively.

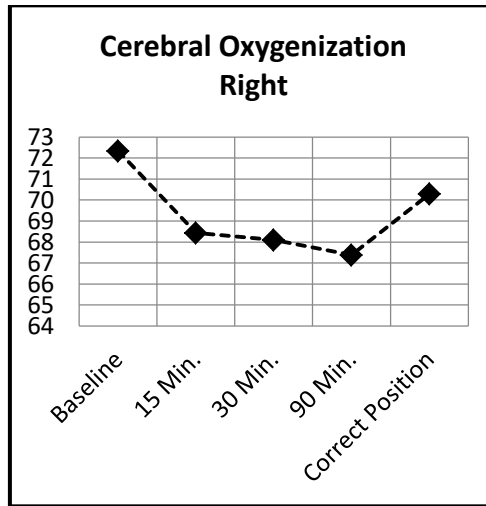


Figure 1. The changes in right cerebral oxygenization.

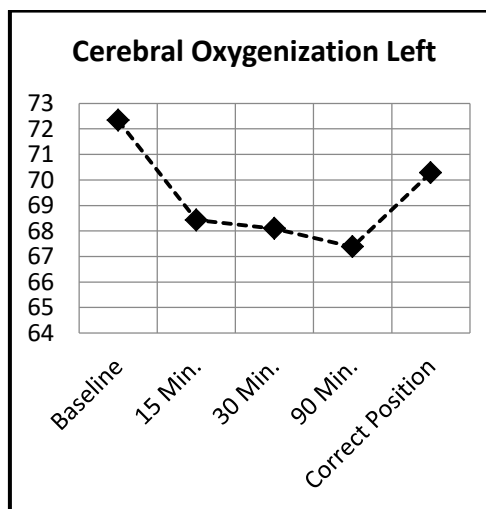


Figure 2. The changes in left cerebral oxygenization.

Mean Arterial Pressure (MAP) and Heart Rate, decreased significantly compared to baseline ($p < 0.05$). (Table 4,5).

Table 4. The changes in mean arterial pressure (mean±SD).

	Min-Max	Median	Mean±s.d.	p*	p**
Mean Arterial Pressure (MAP)					
Baseline	75.0 - 139.0	92.0	95.0 ± 17.2		
15 Minute	56.0 - 124.0	79.0	79.5 ± 14.4	0.006 ^w	
30 Minute	52.0 - 120.0	91.0	82.1 ± 19.1	0.035 ^w	0.626 ^w
90 Minute	53.0 - 106.0	82.0	80.4 ± 17.4	0.007 ^w	0.808 ^w
Correct Position	11.0 - 124.0	86.0	86.7 ± 24.1	0.455 ^w	0.135 ^w

^w Wilcoxon test

p* Difference with baseline / p** Difference with previous measurement

Table 5. Heart Rate changes.

	Min-Max	Median	Mean±s.d.	p*	p**
Heart Rate (HR)					
Baseline	66.0 - 106.0	82.0	85.5 ± 10.7		
15 Minute	57.0 - 106.0	75.0	76.7 ± 13.0	0.011 ^E	
30 Minute	52.0 - 98.0	74.0	75.2 ± 10.7	0.009 ^E	0.533 ^E
90 Minute	54.0 - 98.0	77.0	75.7 ± 13.4	0.012 ^E	0.861 ^E
Correct Position	52.0 - 103.0	83.0	82.2 ± 13.0	0.350 ^E	0.065 ^E

^E Paired samples t test

p* Difference with baseline / p** Difference with previous measurement

End Tidal Carbondioxide compared with baseline values and presented in Table 6.

Table 6. End tidal Carbondioxide changes.

	Min-Max	Median	Mean±s.d.	p*	p**
End Tidal Carbondioxide					
Baseline	0.0 - 0.0	0.0	0.0 ± 0.0		
15 Minute	28.0 - 38.0	32.0	32.5 ± 2.2	0.00	^w
30 Minute	28.0 - 36.0	32.0	32.4 ± 2.5	0	^w 0.790 ^w
90 Minute	27.0 - 38.0	32.0	32.2 ± 2.5	0	^w 0.918 ^w
Correct Position	26.0 - 44.0	34.0	34.7 ± 4.3	0	^w 0.034 ^w

^w Wilcoxon test

p* Difference with baseline / p** Difference with previous measurement

4. Discussion

The study showed that compared to the baseline measurement, the decrease of the both sides of cerebral oxygenation was significant. This significant decrease may

have hazardous effects by reducing cerebral blood flow. Cerebral ischemia may occur. Theoretically, cerebral oxygenation below 45% may lead to neurological damage

postoperatively, none of our patients was observed (6). No clinical signs of neurological sequelae was encountered on post-procedure control of the surgeon. Therefore no need to further neurological examination. The risk of cerebral hypoperfusion and significant reduction in cerebral tissue oxygenation during semi-fowler position lead to clinical sequelae for the patients with cerebrovascular disease or atherosclerosis with plaques. None of our patients have co-morbidities.

Baroreceptors increase activation of the sympathetic nervous system and decrease activation of the parasympathetic nervous system to maintain blood pressure when a person moves from supine to upright (7). In anesthetized patients, the vasodilating effects of intravenous and inhaled anesthetics may suppress the effects of autonomic nervous system (8). Also hypotensive anesthesia, which has been used to reduce intraoperative bleeding for improved intraoperative visibility leads to ischemia. Healthy individuals undergoing shoulder surgery in the beach chair position have been published on catastrophic neurocognitive complications (9,10).

Similar to our study, examined the changes in blood flow with carotis doppler with positional cerebral oxygenation in thyroidectomy patients and reported that there was a 35% reduction in carotid blood flow but no significant difference in cerebral oxygenation also demonstrated that no correlation was found between the decrease in blood pressure, cerebral oxygenation and change in the carotid blood flow (11).

Another study investigated the hyperextension at rose position affects on cerebral tissue oxygenation in children during cleft palate

surgery. They found a significant drop in cerebral oxygenation after positioning. However it is not clear whether this drop is truly significant physiologically in the American Society of Anaesthesiologists' (ASA) class 1 and 2 patients and none of the children had a neurological disturbance (12).

Preoperative evaluation is the important part to determine the high risk patients such as diabetics and further examinations like transcranial doppler may be helpful. Transcranial Doppler is a non-invasive ultrasound which provides neuromonitoring and evaluation of the middle cerebral artery flow velocity, which carries 75 to 80% of the carotid artery blood flow that responsible of the cerebral blood flow (13).

The limitations of our study is that carotid blood flow was not evaluated by doppler preoperatively and also no cognitive tests were used to determine neurocognitive differences postoperatively. If such tests had been performed, clinical effects of decreases in cerebral oxygenation may be seen. According to the results of our study; the decrease in cerebral oxygenation may cause of complications in old patients with hyperlipidaemia, atherosclerosis, carotid plaques.

5. Conclusion

This study demonstrated that Semi-Fowler position with hyperextension of head and neck who undergo thyroidectomy leads to a significant decrease in cerebral tissue oxygenation. The significant drop in cerebral oxygenation after positioning was seen. However, cerebral desaturation were not seen severely during surgery. It is crucial for the patients in high risk group with relevant co-morbidity such as elderly patients.

REFERENCES

1. Murkin JM, Arango M. Near-infrared spectroscopy as an index of brain and tissue oxygenation. *Br J Anaesth.* 2009;103:3-13.
2. Kurihara K, Kikukawa A, Kobayashi A. Cerebral oxygenation monitor during head-up and -down tilt using near-infrared spatially resolved spectroscopy. *Clin Physiol Funct Imaging.* 2003;23:177-81.
3. Aristokleous N, Seimenis I, Georgiou GC, Nicolaidis A, Anayiotos AS. The effect of head rotation on the geometry and hemodynamics of

- healthy vertebral arteries. *Ann Biomed Eng.* 2015;43:1287-97.
4. Deschamps A, Hall R, Grocott H, Mazer CD, Choi PT, Turgeon AF et al. Cerebral Oximetry Monitoring to Maintain Normal Cerebral Oxygen Saturation during High-risk Cardiac Surgery: A Randomized Controlled Feasibility Trial. *Anesthesiology.* 2016;124:826-36
 5. Salazar DH, Davis WJ, Ziroğlu N, Garbis NG. Cerebral Desaturation Events During Shoulder Arthroscopy in the Beach Chair Position. *J Am Acad Orthop Surg Glob Res Rev.* 2019;3:e007.
 6. Hou X, Ding H, Teng Y, Zhou C, Tang X, Li S, Ding H. Research on the relationship between brain anoxia at different regional oxygen saturations and brain damage using near-infrared spectroscopy. *Physiol Meas.* 2007;28:1251-65.
 7. Salazar DH, Davis WJ, Ziroğlu N, Garbis NG. Cerebral Desaturation Events During Shoulder Arthroscopy in the Beach Chair Position. *J Am Acad Orthop Surg Glob Res Rev.* 2019;3:e007
 8. Kim JY, Lee JS, Lee KC, Kim HS, Kim SH, Kwak HJ. The effect of desflurane versus propofol on regional cerebral oxygenation in the sitting position for shoulder arthroscopy. *J Clin Monit Comput.* 2014;28:371-6.
 9. Garnaud T, Muheish M, Cholot M, Austruy T. Cranial nerves VII and XII palsy after shoulder surgery. *Anaesth Crit Care Pain Med.* 2019;38:281-4.
 10. Kocaoglu B, Ozgen SU, Toraman F, Karahan M, Guven O. Foreseeing the danger in the beach chair position: Are standard measurement methods reliable? *Knee Surg Sports Traumatol Arthrosc.* 2015;23:2639-44.
 11. Saraçoğlu A, Altun D, Yavru A, Aksakal N, Sormaz İC, Camcı E. Effects of Head Position on Cerebral Oxygenation and Blood Flow Velocity During Thyroidectomy. *Turk J Anaesthesiol Reanim.* 2016;44:241-6.
 12. Smarius BJA, Breugem CC, Boasson MP, Alikhil S, van Norden J, van der Molen ABM, de Graaff JC. Effect of hyperextension of the neck (rose position) on cerebral blood oxygenation in patients who underwent cleft palate reconstructive surgery: prospective cohort study using near-infrared spectroscopy. *Clin Oral Investig.* 2020 Mar 26.
 13. Özgök A, Ulus AT, Karadeniz Ü, Demir A, Kazancı D, Özyalçın S, Aydın Y, Ünal U. Does uncontrolled diabetes mellitus affect cerebral hemodynamics in heart surgery? *Turk Gogus Kalp Damar Cerrahisi Derg.* 2020;28:84-91.