

The Examination Results of Lymph Nodes in a Tertiary Health Center

Sevilay Özmen^{1*}, Sare Şipal¹, Elif Demirci¹, Esra Çınar Tanrıverdi², Zülal Özkurt³,
Remzi Arslan¹, Onur Ceylan¹

¹ Department of Pathology, School of Medicine, Atatürk University, Erzurum, Turkey

² Department of Medical Education, School of Medicine, Atatürk University, Erzurum, Turkey

³ Department of Infectious Diseases, School of Medicine, Atatürk University, Erzurum, Turkey

Article History

Received 31 May 2020

Accepted 03 June 2020

Published Online 15 June 2020

*Corresponding Author

Dr Sevilay Özmen

Department of Patology,

School of Medicine,

Atatürk University,

Erzurum, Turkey

Phone: +905337254072

E-mail: ertekozmen@gmail.com

ORCID:<http://orcid.org/0000-0002-1973-6101>

Abstract: Lymphadenopathy is the rapid or slow growth of lymph nodes. The differential diagnosis of lymphadenopathy frequently encountered in internal diseases, and department of otorhinolaryngology, has a wide range. The growth of lymph nodes is a common finding during physical examination and most of them are benign. They usually develop due to infectious, neoplastic or autoimmune diseases. Localization of lymphadenopathies may also provide important clues in diagnosis. Lymphoma, toxoplasma, rubella, tuberculous lymphadenitis in cervical lymphadenopathies; gastrointestinal system malignancies or lymphoma in supraclavicular lymphadenopathies; in patients with axillary lymphadenopathies, infections such as lymphoma, brucellosis and cat scratch fever disease are common. To review the diagnostic data of lymphadenopathies in the pathology department of the Faculty of Medicine of Atatürk University. The diagnostic results of lymph node excisions in Atatürk University Faculty of Medicine Pathology Department were retrospectively analyzed, categorized, and the number of cases was determined according to the ages. Of the 1658 patients, 835 (52.7%) were reactive lymphadenitis, 462 (29.1%) were malignant tumor metastasis positive lymph node and 165 (10.4%) were lymphoid malignancy, 122 (7.7%) Non-Hodgkin lymphoma, 41 (2.5%) were reported as Hodgkin lymphoma and 2 (0.1%) as plasma cell dyscrasias. 96 (6.0%) of the cases were diagnosed as necrotizing granulomatous lymphadenitis and 27 (1.7%) were diagnosed as non-necrotizing granulomatous lymphadenitis. No histomorphological details of the lymph node were found in 73 specimens (4.6%) that were sent as lymph node excision. Most of the cases were excised from the cervical region and the second line was axillary region. Lymphadenopathies may be the first manifestation of infections and various cancers. In these patients, delayed diagnosis may cause significant medical problems and should be excised without delay for histopathological diagnosis. © 2020 NTMS.

Keywords: Lymphadenomegaly, Granulomatous Lymphadenitis, Histopathological Diagnosis.

1. Introduction

The word lymph means “clean water” in Latin. Nutrients, electrolytes, immunoglobulins and some proteins are transported to the tissues by the lymphatic system. It acts like an immune control system for tissues (1,2). The lymphatic system has a complex structure and is associated with the circulatory system, hematopoietic system, and the immune system. The lymph fluid drained in the tissues enters the lymph nodes through lymph canaliculi and the circulatory system through the ductus thoracicus (3,4). The lymphatic system is primarily responsible for fulfilling cellular needs, ensuring the transfer of fat from the gastrointestinal tract, and forming an immune response. Lymph nodes are small stations mostly located on the intermammary cleft, usually in the lymphatic canaliculi located in the head and neck region in our body (5). Lymphatic fluid has a place in transporting essential nutrients such as proteins and especially lipids taken from the gastrointestinal tract by enterocytes (6). Immunoglobulins and proteins associated with the immune system are also present in the lymphatic fluid (2,4). The structure of the lymphatic system in the abdomen and thorax is dense and complex compared to other regions and lymphatic flow is quite slow. The flow is very slow especially in the lower extremities. There is no muscle tissue in lymphatic vessels. Of the 300-600 lymph nodes in the human body, approximately half of them are located in the head and neck region. In addition to growing in systemic diseases, lymph nodes can grow locally in diseases localized to anatomical regions with lymph flow drained to a particular node. This growth is called “lymphadenomegaly” or “lymphadenopathy” (LAP) (7,8).

LAP may be the first symptom in most diseases. In physical examination, LAPs show certain distinctive features in terms of etiology. Small lymph nodes in the suboccipital region in children and in the inguinal region in adults can be palpated without any pathology. Cervical lymphadenopathies usually develop as a result of infections and careful physical examination can easily identify the underlying cause. However, growth in supraclavicular, scalene, axillary and epitrochlear lymph nodes is generally pathological, and more detailed examination is required to determine the etiology. LAPs that do not regress or continue to grow after treatment or follow-up should be examined histopathologically (9,10). Excisional biopsy of the lymph node is accepted as the “gold standard” in the diagnosis of LAP (11).

2. Material and Methods

The pathological results of lymph node excisions examined in our tertiary center between 2010 and 2017 were retrospectively scanned from archival records. The data were categorized as total number of cases by age groups and histopathological results by mean age.

3. Results

A total of 1658 lymph node resections were sent to our clinic for histopathological examination from different clinics of our university between 2010 and 2017. Histopathological examinations of lymph node resections revealed that 835 cases (52.7%) were reactive lymphadenitis, 462 cases (29.1%) were malignant tumor metastasis positive lymph node, and 165 cases (10.4%) were lymphoid malignancy. 122 (7.7%) of these malignancies were reported as Non-Hodgkin Lymphoma, 41 (2.5%) as Hodgkin Lymphoma, and 2 (0.1%) as plasma cell dyscrasia (Table 1). 96 (6.0%) of the cases were necrotizing granulomatous lymphadenitis and 27 (1.7%) were non-necrotizing granulomatous lymphadenitis. No histomorphology details of lymph node were found in 73 (4.6%) lymph node excisions sent to out clinic, and most of these were reported as ‘fibrous tissue’ and ‘fibrolipomatous tissue’. Most of our cases were excised from the cervical region, followed by the axillary region. The distribution of the patients with lymphadenopathy according to age is shown in Figure 1 and the distribution of their diagnoses according to average age is shown in Figure 2.

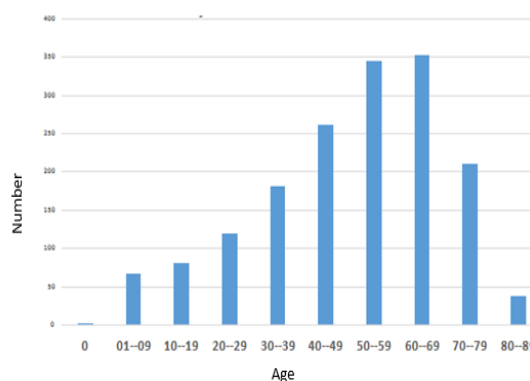


Figure 1: Age distribution of patients with lymphadenopathy.

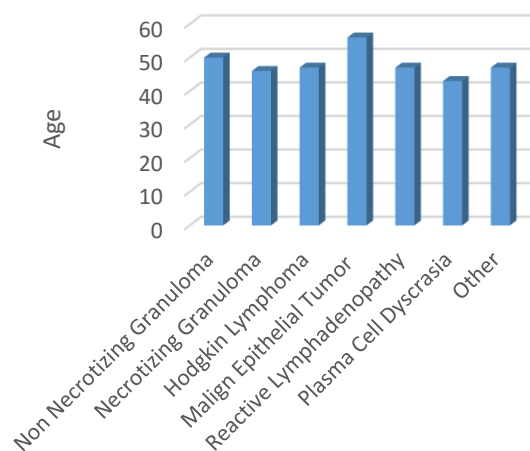


Figure 2: Average age of lymphadenopathy diagnoses.

Table 1: Classification of lymphadenopathies according to histopathological diagnosis.

Diagnosis	Number (n)	Percentage (%)
Reactive Lymphadenopathy	835	52.7
Malignancy	627	39.5
Malignant Tumor Metastasis	462	29.1
Lymphoid Malignancy	165	10.4
Non-Hodgkin Lymphoma	122	7.7
Hodgkin Lymphoma	41	2.5
Plasma Cell Dyscrasia	2	0.1
Granulomatous Lymphadenopathies	123	7.8
Necrotizing	96	6.0
Non-necrotizing	27	1.7
Total	1585	100

4. Discussion

LAP is a common reason for patients to consult a physician and it is coincidentally identified during physical examination conducted for other reasons. LAP may be a symptom accompanying many rare and common diseases. LAP is usually seen in the course of systemic infections. However, it may constitute one of the findings of primary lymphoid malignancies or other malignant conditions or may develop secondary to a significant systemic disease. Various causes such as autoimmune, infectious and malignant diseases are considered in differential diagnosis, histopathological diagnosis with excisional biopsy is therefore highly important (12,13).

In the present study, the age range in which LAP requiring excision was more frequent was also investigated to assist the clinicians. LAP not responding to initial treatments and requiring excisional biopsy was seen in all age groups, but it was most commonly seen in the 50-70 age group. While LAP is also a common clinical symptom in childhood and adolescence, most cases are due to infections and resolve spontaneously or by various treatments. However, excisional biopsy should be performed for diagnosis in the presence of LAP not responding to a treatment, not regressing spontaneously, being protracted, solid and immobile, or when detected in an area such as the supraclavicular region.

In the present study, the mean age of malignant cases was 56 for malignant epithelial tumors, 49 for Non-Hodgkin Lymphoma, 47 for Hodgkin Lymphoma, and 43 for plasma cell dyscrasias. These results were similar to those of Darnal and Desforges (14,15).

Darnal et al. reported that malignant cases with a rate of 47% were most common in adults (14). Reactive lymphadenitis was the most common condition in the present study.

In a study by Gül et al., male: female ratio of Non-Hodgkin Lymphoma and Hodgkin Lymphoma was reported to be 2.67:1 and 2.5:1, respectively (16). These rates are similar to those reported by Darnal and Desforges and the findings of our study (14,15).

In the study of Mohan et al., malignancy rate was 25.8%, after non-specific lymphadenitis and tuberculosis lymphadenitis. It was stated that the number of cases with metastatic lymph node was higher than cases with lymphoma (11). In the present study, calcified granulomatous lymphadenitis was the second most common condition (29.9%).

In the study of Öksüz et al., 192 pediatric cases undergoing lymph node biopsy were included and benign causes were detected in 139 (72%) and malignant causes were detected in 53 (28%) cases (17). Even though the pediatric age group was included in that study, there are similarities in terms of histopathological results. However, it is seen that reactive LAP diagnosis was more frequent compared to our study.

In a Nigerian study conducted by Adesuva et al. on 126 patients who underwent lymph node biopsy, tuberculosis lymphadenitis, reactive changes, and malignancy were reported in 48%, 25%, and 24% of the cases, respectively (18). In the present study, reactive lymphadenitis (52.7%) was the most common condition.

Malignancy followed reactive lymph nodes with a frequency of 39.5%, and malignant tumor metastasis was the most common form of malignancy (29.1%). Öksüz et al. reported that malignancy rate increases with age. In the present study, it was seen that malignant cases peaked between the ages of 40-60 (17).

Limitations

There are certain limitations of this study. Since our unit is a regional, tertiary reference hospital, excisions of long-term lymph nodes that cannot be diagnosed in general polyclinics and family health centers or do not respond to non-specific treatments are sent to our pathology laboratory for histopathological examination. Therefore, our histopathological results may not reflect overall LAP results of the region. Also, due to the retrospective nature of this study, we did not have the opportunity to access more comprehensive data other than the information in the archival records.

5. Conclusions

Since regional epidemiological distribution, incidence and prevalence of diseases vary, interregional differences are highly normal. Although this study does not represent the overall population of our region due to its limitations, the histopathological results of the pathology laboratory of our hospital are important as they reiterate the different causes of LAP. Reactive LAP is the most common cause of LAP in our region, followed by malignant diseases. Contrary to expectation, granulomatous diseases are less common, and tuberculosis takes the first place among them. Considering that lymphadenopathies may be the first finding in the course of various infections and cancers, excision and histopathological diagnosis should be performed as early as possible.

Conflict of interest statement

None

Financial Support

There is no financial support organization.

References

1. Baytan B, Güneş A.M, Günay Ü. Çocukluk Çağında Lenfadenomegaliler. *Güncel Pediatri* **2006**; 2: 49-51.
2. Newman K, Hayes-Jordan AA. Lymph Node Disorders. In: Grosfeld JL, O'Neil JA, Fonkalsrud EW, Coran
3. Grosfeld J, Oneil J, Coran A, Fonkalsrud E, (eds). Pediatric Surgery, Mosby Elsevier, Philadelphia, USA, 6 th ed. **2006**: 844-849.
4. Akyüz C. Lenfadenopatili çocuğa yaklaşım. *İstanbul Üniversitesi Cerrahpaşa Tıp Fakültesi Sürekli Tıp Eğitimi Sempozyumu* **2006**; 49: 17-28.
5. Lanzkowsky P. Lymphadenopathy and Splenomegaly. In: Philip Lanzkowsky (ed). Manual of Pediatric Hematology and Oncology, Elsevier Academic Pres. New York, USA, 5th ed. **2011**;463-468

6. Nolder AR. Paediatric cervical lymphadenopathy: When to biopsy. *Curr Opin Otolaryngol Head Neck Surg* **2013**; 21: 567-70.
7. Şen M. Çocukluk çağı lenfadenopatilerinin değerlendirilmesi. Selçuk Üniversitesi, Uzmanlık Tezi, **2009**.
8. Leung AK, Robson WL. Childhood cervical lymphadenopathy. *J Pediatr Health Care* **2004**; 18: 3-7.
9. Oguz A. Çocukluk çağındaki periferik lenfadenopatiler. *Sürekli Tıp Eğitim Dergisi* **1993**; 2: 335-339
10. Sibanda EN, Stanczuk G. Lymph node pathology in Zimbabwe: A review of 2194 specimens. *Q J Med* **1993**; 86: 811- 817.
11. Adeniji KA, Anjorin AS. Peripheral lymphadenopathy in Nigeria. *Afr J Med Med Sci* **2000**; 29: 233-237.
12. Mohan A, Reddy MK, Phaneendra BV, et al. Aetiology of peripheral lymphadenopathy in adults: Analysis of 1724 cases seen at a tertiary care teaching hospital in southern India. *Natl Med J India* **2007**; 20: 78-80.
13. Cianchetti M, Mancuso AA, Amdur RJ, Werning JW, Kirwan J, Morris CG et al. Diagnostic evaluation of squamous cell carcinoma metastatic to cervical lymph nodes from an unknown head and neck primary site. *Laryngoscope* **2009**; 119(12): 2348-2354.
14. Dilber M, Erişen I, Yerci Ö, Coşkun H, Basut O, Onart S, Hızalan İ. Tiroid dışı baş boyun kitlelerinde ince iğne aspirasyon sitolojisi sonuçlarımız. *Türk Otolarengoloji Arşivi*, **2005**; 43: 86-93.
15. Darnal HK, Karim N, Kamini K, et al. The profile of lymphadenopathy in adults and children. *Med J Malaysia* **2005**; 60:590-598.
16. Desforges JF, Rutherford C], Piro A. Hodgkin's Disease. *N Engl J Med* 1979; 301: 1212-1222.
17. Gül M. Aliosmanoğlu İ, Türkoğlu A, Dal S, Taş İ, Baç B. Erişkin çağı periferik lenfadenopatileri. Eksizyonel Biyopsi Uygulanan 67 Hastanın Sonuçları. *Dicle Med J* **2013**; 40(2); 245-249.
18. Öksüz RYÇ, Dağdemir A, Acar S, Elli M, Öksüz M. Çocukluk çağı periferik lenfadenomegalili olguların retrospektif değerlendirilmesi. *OMÜ Tıp Derg* **2008**; 25: 94-101.
19. Adesuwa Olu-Eddo N, Egbagbe EE. Peripheral lymphadenopathy in Nigerian children. *Niger J Clin Pract* **2006**; 9: 134-138.

Authors' ORCID

Sevilay Özmen

<http://orcid.org/0000-0002-1973-6101>

Sare Şipal

<http://orcid.org/0000-0002-5369-5251>

Elif Demirci

<https://orcid.org/0000-0002-6660-3870>

Esra Çınar Tanrıverdi

<https://orcid.org/0000-0001-8857-3986>

Zülal Bozkurt

<https://orcid.org/0000-0001-5554-8768>

Remzi Arslan

<https://orcid.org/0000-0002-3198-4706>

Onur Ceylan

<https://orcid.org/0000-0003-2768-5524>



<https://dergipark.org.tr/tr/pub/ntms>

All Rights Reserved. © 2020 NTMS.