

Comparison of high aortic arch and other arterial cannulation types in ascending aortic pathologies

Cihan Yücel¹, Nihan Kayalar¹, Serkan Ketenciler¹, Vedat Erentuğ²

¹ Department of Cardiovascular Surgery,
Okmeydanı Research and Training Hospital,
Istanbul, Turkey

² Department of Cardiovascular Surgery, Mehmet
Akif Ersoy Research and Training Hospital,
Istanbul, Turkey

ORCID ID of the author(s)

CY: 0000-0002-1941-0873
NY: 0000-0002-1220-7071
SK: 0000-0003-1528-6788
VE: 0000-0002-9686-8933

Corresponding Author

Cihan Yücel

Okmeydanı Eğitim ve Araştırma Hastanesi, Kalp
ve Damar Cerrahisi Kliniği, Kaptanpaşa
Mahallesi, Darülaceze Caddesi No: 25, 34384,
Okmeydanı, Şişli, İstanbul, Türkiye
E-mail: cihanyucel@hotmail.com

Ethics Committee Approval

Bağcılar Training and Research Hospital ethics
committee approval was obtained with the
number 2012/38.

All procedures in this study involving human
participants were performed in accordance with
the 1964 Helsinki Declaration and its later
amendments.

Conflict of Interest

No conflict of interest was declared by the
authors.

Financial Disclosure

The authors declared that this study has received
no financial support.

Previous Presentation

This article was presented as an oral presentation
at the 13th Turkish Cardiovascular Surgery
Congress (30 October-2 November 2014 /
Antalya / Turkey).

Published

2021 February 19

Copyright © 2021 The Author(s)

Published by JOSAM

This is an open access article distributed under the terms of the Creative
Commons Attribution-NonCommercial-NoDerivatives License 4.0 (CC
BY-NC-ND 4.0) where it is permissible to download, share, remix,
transform, and build upon the work provided it is properly cited. The work
cannot be used commercially without permission from the journal.



Abstract

Background/Aim: Various cannulation techniques are used for different aortic pathologies during aortic surgery. High aortic arch cannulation is an easy technique which does not require a second incision. The aim of this study is to compare high aortic arch cannulation with other arterial cannulation techniques and assess its safety and risks profile.

Methods: This retrospective study included sixty consecutive patients (23 female and 37 male) who underwent elective surgery for ascending aortic aneurysm between July 2011 and June 2014. Patients were divided into Group 1 (aortic arch cannulation) and Group 2 (femoral artery, axillary artery, innominate artery cannulations) according to the location of arterial cannulation. Preoperative, operative, and postoperative data of patients with or without arch cannulation were compared.

Results: Ascending aorta was replaced with a graft in all patients. High aortic arch cannulation was performed in thirty-eight patients (63.3%) while the cannulation site was axillary artery in 9 (15%), femoral artery in 8 (13.3%) and innominate artery in 5 (8.3%) patients. There were no differences between the two groups in terms of preoperative demographic factors, concomitant cardiac pathologies, additional surgical procedures, and intraoperative parameters ($P>0.05$). Moreover, there was no difference between postoperative complications with the one exception of complications related to the cannulation site which was significantly more frequent in cannulation techniques other than arch cannulation ($P=0.04$). We observed no complications related to the cannulation site in patients with arch cannulation.

Conclusion: Our study showed that high aortic arch cannulation in patients with ascending aortic aneurysms is an easy, fast, and safe technique with low complication rates. It can be the technique of first choice for those with ascending aortic aneurysms limited to ascending aorta with no place for cannulation, cross clamp and anastomosis but still can be repaired with single cross-clamping without total circulatory arrest.

Keywords: Cannulation, Aortic arch, Ascending aorta

Introduction

The arterial cannulation site for cardiopulmonary bypass is determined in accordance with the type of operation and the quality of aortic wall. The usual site for arterial cannulation is the ascending aorta in most cardiac operations [1] and intrapericardial aorta is used due to its relative resistance to tear and dissection. Although this technique is easy, safe and does not require an extra incision [2], peripheral arterial cannulation may be necessary in emergency cases, redo surgeries, aortic surgeries, minimal invasive and robotic surgeries and in cases where central cannulation is not possible. In patients with aortic aneurysms, calcification and atherosclerosis found proximal to innominate artery, arch cannulation may be an alternative to peripheral cannulation in selected cases.

In the current study, we evaluated the safety and indications for aortic arch cannulation in patients undergoing surgery for proximal aortic aneurysms.

Materials and methods

A total of sixty consecutive patients, who presented to our hospital between July 2011 and June 2014 and underwent elective operations due to ascending aortic aneurysm were included in the study. After obtaining the approval of the local ethical committee of Bagcilar Training and Research Hospital (02.07.2012/38), the patients were informed thoroughly, after which they were asked to sign the informed consent forms, so their approvals were obtained.

Only patients operated for aortic aneurysms were included in the study. Those who underwent surgery for aortic dissection, patients who required arch cannulation during other cardiac operations due to reasons such as ascending aortic calcification or reoperation were excluded to create a homogenous group.

All patients underwent an evaluation with thorax CT angiography before the operation and patients aged 40 years and above underwent coronary angiography. Demographic characteristics of the cases and routine biochemical examinations before and after the surgery were recorded. In addition, ejection fraction was noted. Data about the surgical procedure, parameters of the early postoperative period, mortalities and morbidities were recorded.

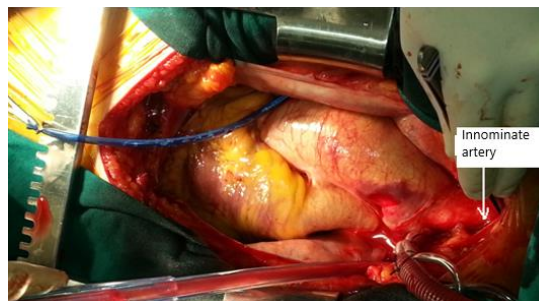Patients were divided into two groups according to the location of arterial cannulation. They were defined as Group 1 (aortic arch cannulation) and Group 2 (femoral artery, axillary artery, innominate artery cannulations). Results were evaluated through statistical analysis and advantages and disadvantages of aortic arch arterial cannulation to other cannulation types of cannulation were assessed.

Surgical technique

After general anesthesia and intubation, standard median sternotomy was performed, and cardiopulmonary bypass (CPB) was instituted by cannulating either the aortic arch or one of the other sites. The site of arterial cannulation (axillary, innominate and femoral arteries, or aortic arch) was determined according to the extension of the aortic pathology. For patients who would undergo hemi-arcus or aortic arch replacement, antegrade cerebral perfusion was planned during total circulatory

arrest, and axillary cannulation was performed in all these patients. In those patients with the extension of ascending aortic aneurysm to the proximal of innominate artery, where there is no space for both aortic clamp and cannulation, we performed arch cannulation and no circulatory arrest (Figure 1). The aortic clamp was placed below innominate artery and angled to cover part of the arch by the extent of the aneurysm.

Figure 1: Arch cannulation



Statistical analysis

Preoperative, perioperative, and postoperative data of the patients were saved on a Microsoft Excel 2003® database. Statistical analyses were performed using SPSS 16.0 for Windows R (SPSS Inc., Chicago, III) software. In addition to descriptive statistical methods (mean (standard deviation) for continuous variables, percentages for categorical variables), data were evaluated using independent t-test for comparing binary groups, and chi-square and Fisher reliability tests for the comparison of qualitative data. The level of significance was $P < 0.05$.

Results

Preoperative data

The mean age of all patients was 62.15 (11.09) years and most were male (61.7%). The most frequent concomitant disease was hypertension (66.7%).

In forty patients (66.6%), there was only ascending aortic aneurysm, six patients (10%) had ascending aortic and hemi-arcus aneurysms, two (3.3%) had ascending aorta and aortic arch aneurysms, and twelve patients (20%) had ascending aorta and aortic root aneurysms. Thirty-eight patients (63.3%) with aortic arch cannulation were included in Group 1 while the remaining twenty-two patients (36.7%) with femoral artery, axillary artery or innominate artery cannulations were included in Group 2. Both groups were compared, and no differences were observed in terms of preoperative comorbid diseases (Table 1).

Table 1: Preoperative data

	Group 1	Group 2	P-value
Age (year)	62.7 (10.8)	61.1(11.7)	0.61
EF (%)	55.2 (8.5)	57.2(5.9)	0.32
Preop creatinine	0.9 (0.2)	0.9(0.2)	0.69
NYHA	2.05 (0.56)	2.09(0.52)	0.79
Sex, n (%)			
Male	23 (60.5%)	14 (63.6%)	0.81
Female	15 (39.5%)	8 (36.4%)	
BMI (kg/m ²)	28.1 (4.6)	27.5(4.2)	0.61
Hypertension, n (%)	24 (63.2%)	16(72.7%)	0.44
CVD, n (%)	2 (5.3%)	1 (4.5%)	1.00
Carotid stenosis, n (%)	0	2 (9.1%)	0.13
COPD, n (%)	7 (18.4%)	5 (22.7%)	0.74
Diabetes Mellitus, n (%)	12 (31.6%)	4 (18.2%)	0.25
CRF, n (%)	5 (13.2%)	3 (13.6%)	1.00
Smoker, n (%)	18 (47.4%)	9 (40.9%)	0.62
Hypercholesterolemia, n(%)	18 (47.4%)	9 (40.9%)	0.62
PAD, n (%)	0	1 (4.5%)	0.36
Myocardial infarction	4 (10.5%)	1 (4.5%)	0.64

EF: Ejection fraction, BMI: body mass index, CVD: cerebro vascular disease, COPD: Chronic obstructive pulmonary disease, CRF: Chronic renal failure, PAD: peripheral arterial disease, NYHA: New York Heart Association.

Operative data

The surgical procedure differed according to the extension of the aneurysm and the presence of additional diseases. Concomitant procedures included coronary artery bypass grafting in thirty patients (50 %), aortic valve replacement in thirty-two patients (53.3 %) and mitral repair in one patient (1.7 %). There was no difference between the two groups in terms of concomitant diseases and procedure. Concomitant diseases and the procedures performed are presented in Table 2.

Table 2: Additional cardiac diseases and operation procedures

	n	%
Coronary artery disease	30	50%
Aortic stenosis	9	15%
Aortic regurgitation	23	38.3%
Mitral regurgitation	3	5%
Reoperation	2	3.3%
AAR	12	20%
AAR+CABG	13	21.6%
AAR+AVR	9	15%
AAR+AVR+CABG	7	11.7%
Bentall	5	8.3%
Bentall+CABG	4	6.7%
AAR+Hemiarch	2	3.3%
AAR+Hemiarch+CABG	2	3.3%
Bentall+MC+CABG	1	1.7%
Bentall+Hemiarch+CABG	1	1.7%
Bentall+Hemiarch	1	1.7%
AAR+Arch+CABG	1	1.7%
Bentall+MVR+ DVTa +Ablation	1	1.7%
Bentall+ mitral ring annuloplasty	1	1.7%
AAR+Arch+AVR+CABG	1	1.7%
AAR+AVR+MVR	1	1.7%

AAR: Ascending Aorta Replacement, AVR: Aortic Valve Replacement, CABG: Coronary Artery Bypass Grafting, MC: Mitral Commissurotomy, MVR: Mitral Valve Replacement, DVTa: DeVega tricuspid annuloplasty

Innominate artery cannulation was performed in 9 (15%) patients and axillary artery cannulation with a side graft was performed in 5 (8.3%). Aortic arch cannulation was the preferred cannulation site in thirty-eight patients (63.3%). We performed femoral artery cannulations in eight patients (13.3%) by placing the cannula directly into the artery. The mean durations of cross-clamp and total perfusion were 106.5(46.7) and 151.83(72.7) minutes, respectively. There was no difference in terms of cross-clamp ($P=0.768$) and perfusion durations ($P=0.311$) between two patient groups.

Postoperative data

No difference was observed between the two groups in terms of durations of stay in the intensive care ($P=0.163$) and in the hospital ($P=0.504$). The amount of postoperative drainage was insignificantly higher in the arch cannulation group ($P=0.433$), and the need for erythrocyte suspension (unit) transfusion similar between the two groups ($P=0.454$) (Table 3).

Renal dysfunction was a frequent complication after the operation which occurred in sixteen patients (26.7%), four of which required temporary hemodialysis (Table 4). A total of six patients required re-exploration for postoperative bleeding and four of these patients had symptoms of cardiac tamponade. All these patients were in the aortic arch cannulation group; however, bleeding was not related to the aortic arch cannulation site in any of these patients.

Table 3: Comparison of postoperative parameters and complications

	Group 1	Group 2	P-value
ICU stay (day)	5.08(3.80)	7.23(7.23)	0.16
Hospital stay (day)	11.82(13.02)	14.14(12.65)	0.50
Total bleeding (cc)	877.63(547.1)	769.55(440.96)	0.43
ICU Erythrocyte suspension (unit)	1.84(1.48)	2.18(1.99)	0.45
ICU Fresh frozen plasma (unit)	1.89(2.44)	2.77(2.56)	0.19
ICU Whole blood (unit)	1.05(1.50)	1.00(0.81)	0.88
Complications	0	3 (13.6%)	0.04
Cardiac tamponade	3(7.9%)	1 (4.5%)	1.00
Respiratory failure	7(18.4%)	5 (22.7%)	0.74
Bleeding revision	6(15.8%)	0	0.07
Renal failure	10(26.3%)	6 (27.3%)	0.93
Dialysis	2 (5.3 %)	2 (9.1%)	0.61
Stroke	1(2.6%)	1 (4.5%)	1.00
Mortality	4 (10.5%)	2 (9.1%)	1.00

ICU: Intensive care unit

Table 4: Postoperative complications

	n (%)
Renal failure	16 (26.7%)
Postop dialysis	4 (6.7%)
Respiratory failure	12(20.0%)
Re-intubation	6 (10.0%)
Bleeding revision	6(10.0%)
Cardiac tamponade	4 (6.7%)
Pleural Effusion	4 (6.7%)
Pneumothorax	3 (5.0%)
Cerebral emboli	2(3.3%)

Complications related to the site of cannulation were brachial plexus injury in one patient (1.7%), axillary artery dissection in one patient (1.7%) and axillary artery laceration in one patient. In the latter two patients, the cannulated artery was repaired with a PTFE graft. There were no infections at the site of the cannulation in any patients. Thrombosis and distal embolism were not observed in the cannulated arteries and no ischemia developed in the extremities. No complications were seen in any of the patients with arch cannulation such as aortic dissection or aortic laceration that required treatment. In terms of postoperative complications, a significant difference was detected only in complications related to the site of the cannulation ($P=0.04$).

Mortality rate was 5.0% with 3 patients ($P=1.00$) (Table 3). One of these as were lost due to sepsis and two died of multiorgan failure within 30 days of operation.

Discussion

Different cannulation techniques can be used in different aortic pathologies and each technique has both advantages and disadvantages. In the presence of an ascending aortic aneurysm, arterial cannulation may be performed through high aortic arch, femoral artery, axillary artery, or innominate artery. The aortic arch cannulation technique that we use in ascending aortic aneurysms has several advantages compared to other techniques such as ease of access in many cases, no requirement for a second incision and more options for the size of the cannula to be used [3, 4].

Femoral cannulation is associated with various complications including tearing, dissection and delayed stenosis of the artery and infection, embolism, and ischemia of the extremities [5, 6]. One of the most severe complications of femoral arterial cannulation is the arterial dissection, which could cause retroperitoneal bleeding or retrograde extension to the proximal aorta. The incidence of this complication is low and was reported as between 0.02% and 1.3% [7, 8]. However, once developed, this may result in severe morbidity and mortality.

Another significant complication associated with femoral artery cannulation is the increased risk of stroke with retrograde flow. In comprehensive studies where femoral

cannulation was used, the stroke rate was between 0-11% [9]. On the other hand, Strauch et al. [10] reported the incidence of stroke as 4.6% in 284 ascending and aortic arch replacement cases where antegrade flow was provided through axillary cannulation. We did not observe any of these complications in patients who underwent femoral artery cannulation in our patient group. This is mainly because femoral artery cannulation was performed only in eight patients (13.3%) and these patients were selected after careful examination of CT angiograms for calcifications of the aorta and peripheral arterial disease.

Axillary artery cannulation has certain advantages to femoral artery such as the low probability of atherosclerosis, good collateral flow, reduced risk of ischemic and embolic cerebral events and less frequent complications related to the cannulation site. Injuries in the nerves of the arm and axillary artery thrombosis have been reported as important complications of this technique [11]. One of our patients experienced injuries in the nerves of the arm and one patient experienced axillary artery thrombosis. It is believed that certain complications related to the axillary artery cannulation could be reduced by using a side graft and the data in the literature supports that. In their study on 399 axillary artery cannulations, Sabik et al. [12] found the cannulation-related morbidity as 7% in the direct group and 2% in the side graft group and suggested that axillary cannulation should be performed with a side graft. Svensson et al. [13] found that the risk of stroke was reduced only in the axillary artery cannulations with a side graft in their study on 1336 cases, in which hypothermic circulatory arrest was used. We performed axillary artery cannulation with a side graft in all patients and observed complications related to the cannulation site in 2 patients. These complications were related to the traction of the artery during mobilization.

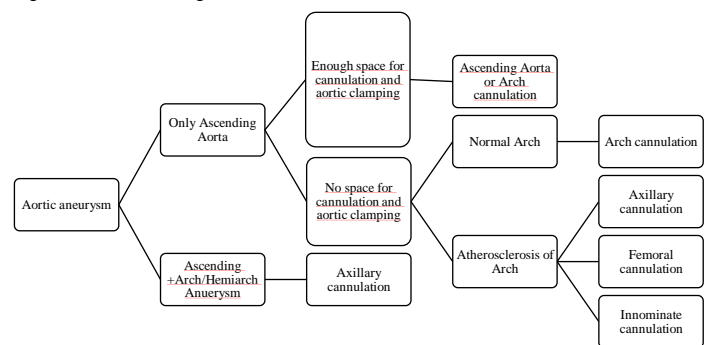
The cannulation of the aortic arch has the advantages of axillary cannulation such as antegrade cerebral flow and minimal risk of cerebral embolism while avoiding its complications. It is noteworthy that no complications were observed regarding the site of the aortic arch cannulation in our study. We can consider aortic arch cannulation a significant alternative due to the ease of application and negligible risk of complications, particularly for patients who do not require total circulatory arrest and do not have sufficient space for both cross clamping and anastomosis in the ascending aorta. By using aortic arch cannulation in these patients, both a second incision and the complications of femoral and axillary artery cannulations can be avoided. Even though the axillary artery is an appropriate choice in these patients, exploration is difficult in patients with obesity and chest deformities, and it requires a second incision.

In addition to these significant advantages, aortic arch cannulation also has certain disadvantages. Aortic dissection or tearing are especially important complications and since cannulation cannot be performed on the intrapericardial aorta, they may be expected to occur at higher rates. However, we have never experienced that with our patients. We believe that a meticulous surgical technique, optimization of the arterial pressure during the placement of the cannula and using pledgetted suture for purse stitches in selected patients could prevent these complications to a great extent. We prefer the use of pledgetted stitches particularly in the elderly patients and

those with thin aortic walls and in redo cases. Other complications are similar to that of the ascending aorta cannulation and include intramural placement, dislocation of atheroembolism, air embolism, continued bleeding around the cannula or after the removal of the cannula, and abnormal cerebral perfusion. Theoretically, the risk of the malperfusion of aortic branches is higher compared to the other types of cannulation. However, careful placement of cannula with attention to the direction of its tip prevents this complication. We observed cerebrovascular complication in one patient with axillary cannulation and one patient with arch cannulation which was not related to displacement of cannula.

Our study showed that the aortic arch cannulation is a safe procedure and is an alternative to axillary artery cannulation in selected patients. We developed an algorithm for the selection of cannulation site in patients with ascending aortic aneurysms as shown in Figure 2. Aortic arch cannulation should be considered primarily in patients with aneurysms without insufficient space for both aortic cannulation and anastomosis and normal arch.

Figure 2: Cannulation algorithm



Limitations

This was a single-institution retrospective study, not a randomized trial. Nevertheless, we consider that the aim of this study was accomplished since we demonstrated the safety of a cannulation technique that is usually avoided due to concerns for complications. We also set a clear algorithm for choice of cannulation site. This study cohort was relatively small and future studies with higher patient numbers may help to provide a better insight for probable complications and comparison with other cannulation techniques.

Conclusions

Aortic arch cannulation is an easy, quick, and reliable technique with low complication rates in patients with ascending aortic aneurysms. It can be considered as the first choice in cases where the aneurysm is limited to the ascending aorta but there is insufficient space for cannulation, cross clamping, and anastomosis. The careful placement of an aortic clamp may prevent the use of circulatory arrest in many cases. This technique also avoids a second incision and complications related to axillary and femoral cannulations.

References

- McAlpine WA, Selman MW, Kawakami T. Routine use of aortic cannulation in open heart operations. *Am J Surg.* 1967;114:831-4.
- Davidson KG. Cannulation for cardiopulmonary bypass. In: Taylor KM ed. *Cardiopulmonary bypass: principles and management*. Baltimore: Williams & Wilkins, 1987. pp.55-89.
- Salerno TA, Lince DP, White DN, Lynn R, Charrette EJP. Arch versus femoral artery perfusion during cardiopulmonary bypass. *J Thorac Cardiovasc Surg.* 1978;78:681-4.
- Merin O, Silberman S, Brauner R, Munk Y, Shapira N, Falkowski G, et al. Femoro-femoral bypass for repeat open-heart surgery. *Perfusion* 1998;13:455-9.
- Hendrickson SC, Glower DD. A method for perfusion of the leg during cardiopulmonary bypass via femoral cannulation. *Ann Thorac Surg.* 1998;65:1807-8.

6. Greason KL, Hemp JR, Maxwell JM, Fetter JE, Moreno-Cabral RJ. Prevention of distal leg ischemia during cardiopulmonary support via femoral cannulation. *Ann Thorac Surg.* 1995;60:209–10.
7. Bigutay AM, Garamella JJ, Danyluk M, Remucal HC. Retrograde aortic dissection occurring during cardiopulmonary bypass. *JAMA.* 1976;236:465–8.
8. Jones TW, Vetto RR, Winterscheid LC, Dillard DH, Merendino KA. Arterial complications incident to cannulation in open-heart surgery. *Ann Surg.* 1960;152:969–74.
9. Svensson LG, Crawford ES, Hess KR, Coselli JS, Raskin S, Shenaq SA, et al. Deep hypothermia with circulatory arrest. Determinants of stroke and early mortality in 656 patients. *J Thorac Cardiovasc Surg.* 1993;106:19–28.
10. Strauch JT, Spielvogel D, Lauten A, Lansman SL, McMurtry K, Bodian CA, et al. Axillary artery cannulation: routine use in ascending aorta and aortic arch replacement. *Ann Thorac Surg.* 2004;78:103–8.
11. Bichell DP, Balaguer JM, Aranki SF, Couper GS, Adams DH, Rizzo RJ, et al. Axilloaxillary cardiopulmonary bypass: A practical alternative to femorofemoral bypass. *Ann Thorac Surg.* 1997;64:702–5.
12. Sabik JF, Neme H, Lytle BW, Blackstone EH, Gillinov AM, Rajeswaran J, et al. Cannulation of the axillary artery with a side graft reduces morbidity. *Ann Thorac Surg.* 2004;77:1315–20.
13. Kucuker SA, Ozatik MA, Saritas A, Tasdemir O. Arch repair with unilateral antegrade cerebral perfusion. *Eur J Cardiothorac Surg.* 2005;27:638–43.

This paper has been checked for language accuracy by JOSAM editors.

The National Library of Medicine (NLM) citation style guide has been used in this paper.