

Hemoptizinin Nadir Bir Sebebi Ortopik Ya Da Ektopik Bronşial Arter? Literatürün Kısa Değerlendirmesi.

A Rare Cause of Hemoptysis. Orthotopic or Ectopic Bronchial Artery? A Brief Review of The Literature.

Mustafa Fatih Erkoç¹, Aylin Okur¹, Gülay Karahan²

¹Bozok Üniversitesi Tıp Fakültesi Radyoloji AD / Yozgat

²Samsun Devlet Hastanesi Radyoloji Kliniği / Samsun

Özet

Başvuru Tarihi: 26.08.2014 **Kabul Tarihi:** 25.09.2014

Normal bronşial arterler direkt olarak inen torasik aortadan köken alan ve havayolları, özefagus ve lenf nodalarının beslenmesini sağlayan küçük çaplı damarlardır. Bronşial arterler orjinlerine, dallanma paternlerine ve seyirlerine göre farklı anatomik varyasyonlar gösterebilirler. Anormal yerleşimli bir bronşial arterin en önemli komplikasyonu rüptür ve hemoptizidir. Bu tip hastaların tedavisi için akciğerin anormal vasküler yapılarının anlaşılması önem arz etmektedir.

Anahtar Kelimeler: Bronşial arter, BT, hemoptizi

Abstract

Application: 26.08.2014 **Accepted:** 25.09.2014

Normal bronchial arteries are small vessels that arise directly from the descending thoracic aorta and supply blood to the airways of the lung, esophagus, and lymph nodes. Bronchial arteries show substantial anatomic variations with respect to their origins, branching patterns, and courses. The most important complication of an abnormal bronchial artery is rupture and hemoptysis. Understanding the variations of abnormal vascular system of lung is important for treatment of such patients

Keywords: bronchial artery, CT, hemoptysis

Giriş

Hemoptysis is the expectoration of blood that originates from the lower respiratory tract. Massive hemoptysis is defined as expectoration of large amounts of blood (100 – 600 cc) via the respiratory tract and is one of the most common life-threatening respiratory emergencies. Massive hemoptysis has a variety of underlying etiologies such as bronchiectatic, tuberculosis, AVM and malignancy and source of bleeding in 90% of patients is the bronchial circulation. Any bleeding in the airways that is accompanied by breathing insufficiency or hemodynamic imbalance should be solemnly evaluated and treated. Surgery was the only available treatment in the past. Unfortunately, surgical procedures are accompanied by a high mortality and morbidity rates, especially in emergency situations. Likewise, conservative treatments usually do not have much impact on controlling the bleeding. Since the systemic circulation via the bronchial arteries is responsible for the majority of hemoptysis cases, bronchial artery embolization (BAE) which is a minimally invasive method, can control the bleeding by decreasing the pressure of the abnormal lung parenchyma. Since the most important complication of an abnormal bronchial artery is rupture and hemoptysis, it is important to understand the normal and abnormal vascular pattern of the lung for treatment of such patients^[1,2].

Case report

24 years old female patient admitted with complaints of recurrent hemoptysis that has aggravated past 6 months period. There was no significant finding in her physical examination. Contrast-enhanced MDCT was performed to evaluate thorax. There were mild fibrotic and minimally bronchiectatic changes located bilateral basal segments. Surprisingly there was an abnormal systemic artery supplying the posterobasal segment of the right lower lobe and originating from the anterior wall of the descending aorta; indicating an orthotopic bronchial artery (figure 1).

Discussion

Systemic arterial supply of the lung can be classified as bronchial and non bronchial with excluding pulmonary arter. The normal bronchial arterial system origins from major two branches: The right intercostobronchial trunk, which usually arises from the right posterolateral aspect of the thoracic aorta^[1-3]

and the left bronchial arteries that usually originate from the anterior surface of the thoracic aorta or from the concavity of the aortic arch. The left bronchial arteries pass forward beside the lateral wall of the esophagus, and cross the peribronchial space from the level of the left main bronchus toward the hilum^[1-5]. Four kinds of classic bronchial artery branching patterns have been described.

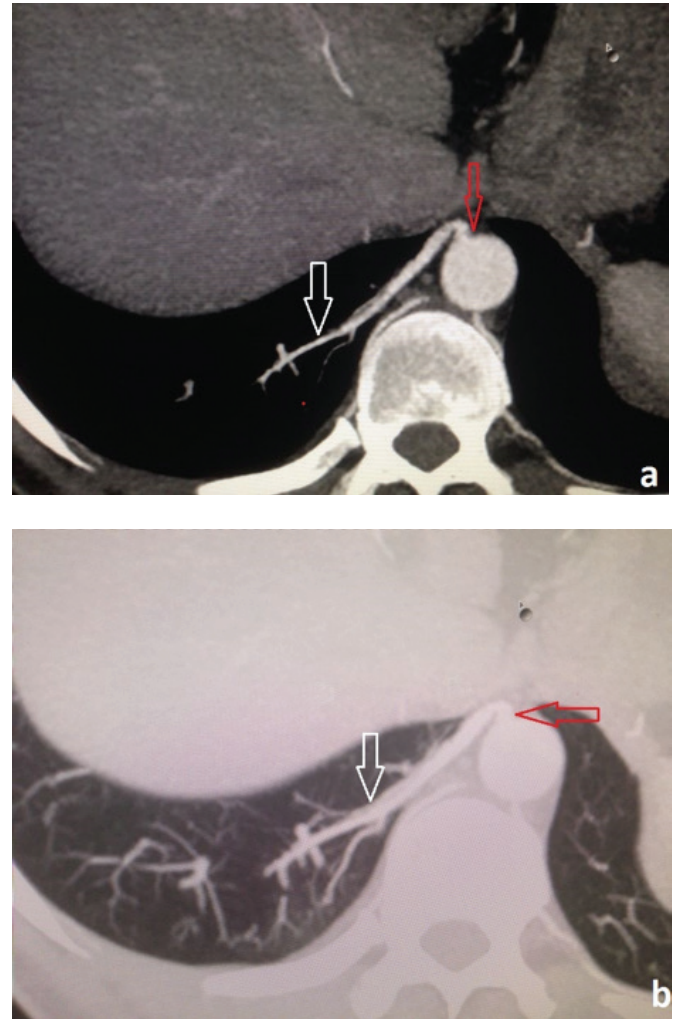


Figure 1: Inferior-superior MIP on mediastinal (a) and lung window (b) obtained from multidetector CT of the right lower lung zone, showing the abnormal systemic artery (white arrow) originating from the

If the bronchial artery originates from the descending aorta with a level of the fifth or sixth thoracic vertebra, it is called as orthotopic; when its origin is at the descending aorta other than at the expected site, at the aortic arch, or at any aortic collateral vessel, with an intrapulmonary course along the ma-

lor bronchi, it is called as ectopic ^[6]. The most frequent origins of ectopic bronchial arteries were the concavity of the aortic arch (92/124; 74%) ^[7].

On the other hand non bronchial systemic arteries were defined as arteries that enter the parenchyma through the inferior pulmonary ligament or through the adherent pleura; their course is not parallel to that of the bronchi ^[6].

There are similar cases regarding different types of ectopic bronchial artery in literature. Some authors studied to show these different patterns on cadaveric findings ^[8], others pointed these differences on radiological images.

Both of the bronchial and non bronchial abnormal systemic arteries most common complication is rupture and hemoptysis, in patients with chronic lung diseases and other diseases that affect the pulmonary vascular system. Such patients with suspicion of origin of an abnormal artery can be diagnosed with multi detector computed tomography (MDCT). MDCT angiography has enabled radiologists to provide thin-slice axial images, multi-planar reconstructions, interactive maximum intensity projections, and volume-rendered images to evaluate the origin and course of the abnormal bronchial arteries that may be the cause of hemoptysis. Embolization of the bronchial arteries is the primary treatment option in patients with massive hemoptysis ^[5].

In conclusion; since the variations of abnormal vascular system of lung can cause hemoptysis it is important to understand normal-abnormal vascular system. MDCT is a non-invasive diagnostic tool in such patients.

References

1. Yoon W, Kim JK, Kim YH, Chung TW, Kang HK. Bronchial and nonbronchial systemic artery embolization for life-threatening hemoptysis: a comprehensive review. *RadioGraphics* 2002; 22:1395–1409.
2. Murayama S, Hashiguchi N, Murakami J, et al. Helical CT imaging of bronchial arteries with curved reformation technique in comparison with selective bronchial arteriography: preliminary report. *J Comput Assist Tomogr* 1996; 20:749–755.
3. Song JW, Im JG, Shim YS, Park JH, Yeon KM, Han MC. Hypertrophied bronchial artery at thinsection CT in patients with bronchiectasis: correlation with CT angiographic findings. *Radiology* 1998; 208:187–191.
4. Uflacker R, Kaemmerer A, Picon PD, et al. Bronchial artery embolization in the management of hemoptysis: technical aspects and long-term results. *Radiology* 1985; 157:637–644.
5. Furuse M, Saito K, Kunieda E, et al. Bronchial arteries: CT demonstration with arteriographic correlation. *Radiology* 1987; 162:393–398.
6. Remy-Jardin M, Bouaziz N, Dumont P, Brillet P-Y, Remy J. Bronchial and nonbronchial systemic arteries at multi-detector row CT angiography: comparison with conventional angiography. *Radiology* 2004; 233:741–749.
7. Hartmann, I. J., Remy-Jardin, M., Menchini, L., Teisseire, A., Khalil, C., & Remy, J. (2007). Ectopic origin of bronchial arteries: assessment with multidetector helical CT angiography. *European radiology*, 17(8), 1943-1953.
8. Natsis K, Asouhidou I, Vizas V, Didagelos M. A rare cadaveric finding of ectopic origin of a bronchial artery: surgical and imaging consequences. *Folia Morphol (Warsz)*. 2013 Feb;72(1):78-81.

