

Closed Extension Block Technique for Treatment of Osseous Mallet Injury

Çekiç Parmak Kemiği Yaralanmasının Tedavisinde Ekstensiyon Blok Yöntemi

Hakan Başar¹, Mustafa Erkan İnanmaz¹, Onur Başçı²,
Motasım Bawaneh², Betül Başar³, Kamil Çağrı Köse¹

¹Department of Orthopedics Surgery, Sakarya University Training and Research Hospital

²Department of Orthopedics Surgery, Marmara University School of Medicine

³Akyazı State Hospital, Department of Physical Medicine and Rehabilitation

Yazışma Adresi / Corresponding to:

Uzm. Dr. Hakan Başar. Eski Kazımpaşa caddesi yolu Arabacalanı mah. Akkent sitesi No: 156/25 Serdivan 54100 Sakarya - Türkiye
GSM: 05054418608 e-mail hbasar80@hotmail.com

Özet

Başvuru Tarihi: 25.01.2013 Kabul Tarihi: 20.05.2013

Abstract

Application: 25.01.2013 Accepted: 20.05.2013

Objectives: We analyzed the clinical and radiological outcomes of percutaneous extension block technique for treatment of osseous mallet injury.

Methods: We included 36 patients who had osseous mallet finger $\geq 20\%$ articular surface involvement. We controlled 29 men, 7 women followed mean 18,5 (Range 8 – 24) months.

Radiologic evaluation was made according to the Doyle classification and 25 injuries were classified type IVb, 11 injuries were classified type IVc. Final evaluation were made according to Crawford evaluation criteria and distal interphalangeal joint motion.

Results: The preoperative average articular surface involvement was 39,7% (Range 20 – 60). The DIP joint subluxation was seen in 6 patients who had $\geq 50\%$ articular surface involvement. Clinical results, according to the Crawford criteria, were excellent in 30 (83,3%) patients, good in 4 patients (11,1%), moderate in 2 patients (5,5%). The average extension lag was 3,1° (0°to 17°), and the average final active flexion of DIP joint was 75,1° (50° to 80°). Bone union was showed in all cases radiographically at the final control.

Conclusion: The extension block technique is a minimal invasive treatment technique. This technique has decreased the complications of the open surgical treatments. This technique when properly applied has been given functionally satisfactory results. The experience of the surgeon is very effective over the result of the patients.

Keywords: Mallet Finger Surgery, Extension Block.

Introduction:

Mallet injuries are detachment of the terminal extensor tendon, from the base of the distal phalanx either directly or in association with a fracture.¹

Due to the difficulties in following up the closed reduction stably in the osseous mallet finger, surgical treatment is generally recommended for fractures with bone fragments that occupy one third or more of the joint surface and fractures associated with subluxation toward the palmar side.^{2,3}

During open reduction and fixation with pull-out wires or Kirschner wires has disadvantages. The bone fragments are often small, they break, the maintenance of the reduction is difficult. The reduction lost may be caused the non-union or mal-union and poor range of motion. Also open surgery may be caused extension lags, permanent nail deformities, skin necrosis, pin track infection and osteomyelitis.⁴

Percutaneous procedures have advocated by some authors because of these complications. We evaluated long term outcomes of the extension block fixation technique which was described by Ishiguro for the first time.⁵

Material and Method:

36 patients diagnosed with mallet fracture between January 2006 and January 2012 were involved in the study. The patients with open fractures, comminuted fractures and less than 20% articular surface fractures were not involved in the study. The pre-operative ages, genders, Doyle classification of mallet finger injuries were evaluated. Pre-operative lateral radiographs of the finger were used to determine the presence of palmar subluxation of the distal phalanx, fragment displacement and fragment size. Anterior-posterior radiographs were used to exclude comminution. The informed consent was obtained from all patients.

Surgical Technique

After the digital block application, the DIP joint was maximally flexed. First a K wire was passed the extensor tendon at a 45 degree angle into the middle phalanx, just dorsal and proximal to the fracture fragment. This first wire took role as a extension block during DIP joint extension. The second wire

was placed longitudinally from distal phalanx to middle phalanx across the DIP joint to maintain extension and reduction. The K-wires were cut and bent. Postoperative volar extension splint was applied for DIP joint immobilization. MP and PIP joint motion were allowed for the patients. The K wires were pulled at 4 week and pasive and active DIP joint motions were started .The volar extension splint' usage was continued for 2 weeks more.

All of the surgical procedures were performed by the same hand surgeon.

The physical and radiographic controls of the patients were carried out as the 1st month, 6th month annual controls. Radiographies were reviewed for displacement, fracture size, malunion and nonunion. Additionally, evaluation of the clinical results was carried out using range of motion, extensor lag, tender dorsal prominences, and complications (nail deformity and skin necrosis) and Crawford evaluation criteria. Active and passive ranges of motion were measured by using a goniometer.

Results:

Mean age of the pre-operative patients were 29,8 (range 18 to 42) and 29 of 36 patients (80,5 %) were male and 7 (19,5 %) were female. The 4th and 5th fingers were the most frequently involved finger¹², followed by the 1st fingers⁵, the 2nd fingers⁴ and the 3th fingers³. 27 patients had mallet injury in dominant hand, 9 patients had in non-dominant hand. Based on the Doyle classification, 25 injuries were classified type IVb, 11 injuries were classified type IVc (Figure 1).

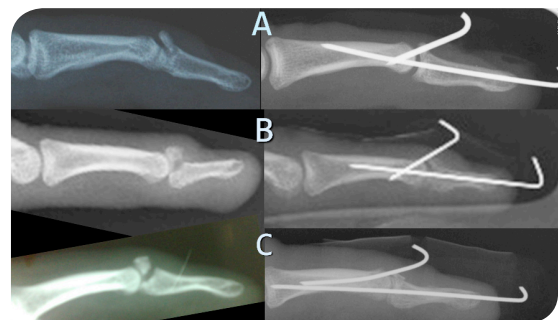

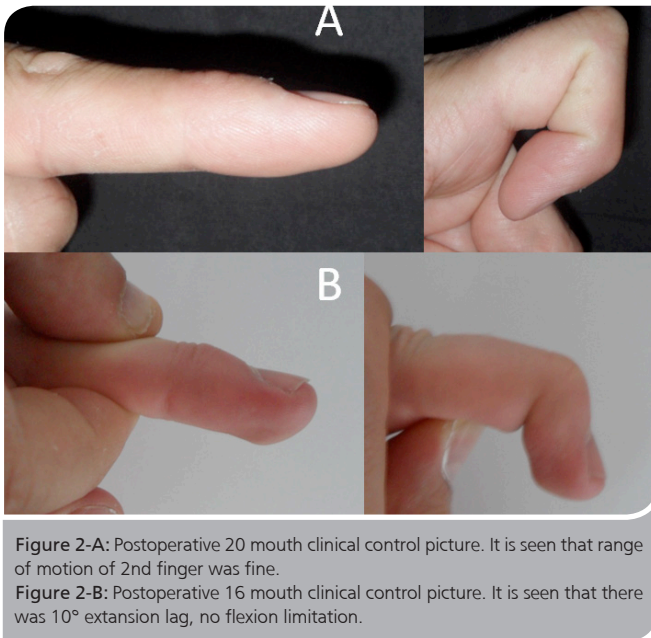
Figure 1-A: The average articular surface involvement was 30%.

Figure 1-B: The average articular surface involvement was 50% and DIP joint subluxation was seen.

Figure 1-C: The average articular surface involvement was 60%.

The average articular surface involvement was 39,7% (Range 20 – 60). The DIP joint subluxation was seen in 6 patients who had $\geq 50\%$ articular surface involvement (Figure 1-B). First closed reduction was tried on all injuries than extension block treatments were applied.

At mean 18,5 (Range 8 – 24) months controls of 36 patients involved in the study, according to the Crawford criteria, the results were excellent in 30 (83,3%) patients, good in 4 patients (11,1%), moderate in 2 patient (5,5%). The average extension lag was 3,1° (0°to 17°), and the average final active flexion of DIP joint was 75,1° (50° to 80°) (Figure 2).



Bone union was showed in all cases radiographically at the final control. An intra-articular step off of less than 1mm was present in 6 joints. Bone union was showed at these patients and dorsal prominence was showed at 2 of these patients. 4 of these patients had full DIP joint motion but 2 of these patients had 14,5° extension lag (Figure 3).

No case has wire bottom infection, skin necrosis, reflex sympathetic dystrophy, swan-neck deformity, fragmentation of the fracture, nail bed injury, pin migration. All of the patients were able to return to their previous task.

Discussion:

An untreated mallet injury is painful. The swan-neck deformity develops due to compensatory hyperextension at the PIP joint of the finger (6, 7). The osseous mallet finger constitutes about 5 - 10 % of mallet finger injuries (8).

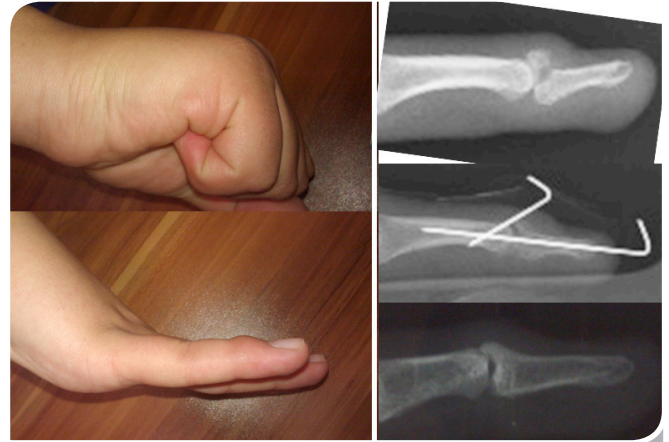


Figure 3: Postoperative 24 month clinical control picture, preoperative, early postoperative and postoperative 24 month radiographies. The average articular surface involvement was 60%. There was no limitation of DIP joint motion.

The management of acute mallet fingers with a small fracture fragment involving less than one-third of the articular surface of the distal phalanx is usually done by continuous distal interphalangeal joint volar splinting in extension for 6 to 8 weeks. Frequent follow-up evaluations are essential for conservative treatment¹. The complications (skin maceration, tender dorsal prominence, joint stiffness, swan neck deformity, extension deficiency) have been reported for conservative treatment^{9,10}. Approximately 10° extension deficiency has been reported after conservative treatment in 40% to 70% of patients^{11,12}.

The treatment of mallet fractures involving more than one-third of the articular surface is controversial. The incidence of complication (permanent nail deformity, marginal skin necrosis, avascular necrosis of fragment, osteomyelitis) was 33% to 53% for open surgical treatment^{1,13}.

The extension block technique is a minimal invasive treatment technique. This technique has decreased the complications of the open surgical treatments. Pin-tract infection is most potential complication of this technique. Regular follow-up

is important to prevent this complication. In our study, we didn't see pin-tract infection. 78% to 92% excellent and good functional results have been reported^{9,14}. We obtained 34/36% excellent and good results in our study. A perceived disadvantage of extension block technique might be the need for fluoroscopy as the other closed surgical procedures. The other disadvantage is articular cartilage damage as a result of K wire insertion which might lead to osteoarthritis. Repe-

tative attempt at pin insertion is increased articular cartilage damage. The experience of the hand surgery is very important for this reason. In our study we didn't see osteoarthritis at the patients.

This technique when properly applied has been given functionally satisfactory results. The experience of the surgeon is very effective over the result of the patients.

References

1. Wehbé MA, Schneider LH. Mallet fractures. *J Bone Joint Surg* 1984;66(A):658-69.
2. Lubahn JD. Mallet finger fractures: a comparison of open and closed technique. *J Hand Surg* 1989;14(A):394-6.
3. Stark HH, Gainor BJ, Ashworth CR, et al. Operative treatment of intra-articular fractures of the dorsal aspect of the distal phalanx of digits. *J Bone Joint Surg* 1987;69(A):892-6.
4. Kang HJ, Shin SJ, Kang ES. Complications of operative treatment for mallet fractures of the distal phalanx. *J Hand Surg* 2001, 26(B): 28-31.
5. Ishiguro T, Inoue K, Matsubayashi T, Ito T, Hashizume N. A new method of closed reduction for mallet fractures. *J Jap Soc Surg Hand* 1988;5:444-7.
6. Grundberg AB, Reagan DS. Central slip tenotomy for chronic mallet finger deformity. *J Hand Surg* 1987;12(A):545-7.
7. Evans D, Weightman B. The Pipflex splint for treatment of malletfinger. *J Hand Surg* 1988;13(B):156-8.
8. Darder-Prats A, Fernandez-Garcia E, Fernandez-Gabarda R: Treatment of mallet finger fractures by the extension-block K-wire technique. *J Hand Surg* 1998; 23(B): 802-5
9. Hofmeister EP, Mazurek MT, Shin AY, Bishop AT. Extension block Pinning for Large Mallet Fractures. *J Hand Surg* 2003;28(A):453-9
10. Rayan GM, Mullins PT. Skin necrosis complicating mallet finger splinting and vascularity of the distal interphalangeal joint overlying skin. *J Hand Surg* 1987;12(A): 548-52.
11. Abouna JM, Brown H. The treatment of mallet finger: the results in a series of 148 consecutive cases and a review of the literature. *Br J Surg* 1968;55:653-67.
12. Mikic Z, Helal B. The treatment of the Mallet finger by the Oakley splint. *The Hand* 1974;6:76-81.
13. Stern PJ, Kastrup JJ. Complications and prognosis of treatment of mallet finger. *J Hand Surg* 1988;13(A):329-34.
14. Pegoli L, Toh S, Arai K, Fukuda A, Nishikawa S, Vallejo G. The Ishiguro extension block technique for the treatment of mallet finger fracture: indications and clinical results. *J Hand Surg* 2003;28(B):1:15-7