

# Clinicopathological assessment in orchiectomy materials

## Orşiektomi materyallerinde klinikopatolojik değerlendirme

Leymune Parlak <sup>1</sup>, Emine Zeynep Tarini <sup>1</sup>

<sup>1</sup> Department of Pathology, University of Health Science Turkey, Mehmet Akif İnan Training and Research Hospital, Şanlıurfa, Turkey

ORCID ID of the author(s)

LP: 0000-0002-5503-3067  
EZT: 0000-0001-9874-5104

Corresponding author/Sorumlu yazar:

Leymune Parlak

Address/Adres: Department of Pathology, University of Health Science Turkey, Mehmet Akif İnan Training and Research Hospital, Şanlıurfa, Turkey

E-mail: leymune\_38@hotmail.com

Ethics Committee Approval: The research was approved by Harran University Ethical Committee (27.01.2020/02/ no:18). All procedures in this study involving human participants were performed in accordance with the 1964 Helsinki Declaration and its later amendments.

Etik Kurul Onayı: Çalışma Harran Üniversitesi Klinik Araştırmalar Etik Kurulu 27.01.2020 tarih, 02 nolu oturum ve 18 sayılı kararı ile onaylanmıştır. İnsan katılımcıların katıldığı çalışmalarındaki tüm prosedürler, 1964 Helsinki Deklarasyonu ve daha sonra yapılan değişiklikler uyarınca gerçekleştirilmiştir.

Conflict of Interest: No conflict of interest was declared by the authors.

Çıkar Çatışması: Yazarlar çıkar çatışması bildirmemişlerdir.

Financial Disclosure: The authors declared that this study has received no financial support.

Finansal Destek: Yazarlar bu çalışma için finansal destek almadıklarını beyan etmişlerdir.

Published: 12/30/2020  
Yayın Tarihi: 30.12.2020

Copyright © 2020 The Author(s)  
Published by JOSAM

This is an open access article distributed under the terms of the Creative Commons Attribution-NonCommercial-NoDerivatives License 4.0 (CC BY-NC-ND 4.0) where it is permissible to download, share, remix, transform, and build upon the work provided it is properly cited. The work cannot be used commercially without permission from the journal.



### Abstract

Aim: Orchiectomy indicates excising the testicles unilaterally or bilaterally. The causes of excision include primary etiologies such as torsion/infarction, infection, malignancy, cryptorchidism, and therapeutic castration secondary to prostate cancer. The aim of this study is to determine the clinicopathological characteristics of patients undergoing orchiectomy and obtain regional data.

Methods: In this study, 316 orchiectomy specimen reports, stored in the archive of University of Health Science Turkey, Mehmet Akif İnan Training and Research Hospital, Pathology Laboratory between January 2015 and December 2019 were retrospectively evaluated. Histopathological diagnoses, right-left testicular localization, age range of patients and orchiectomy indication data were analyzed.

Results: While the ages of 316 patients included in the study ranged from 1 to 88 years, the mean age was 26 years. Among the orchiectomy materials, undescended testis was the most common cause with 129 (40.8%) cases. Three hundred (94.9%) cases underwent unilateral and 16 (5.1%) cases underwent bilateral orchiectomy. Orchiectomy was performed in 58 cases aged between 14-68 years (mean age: 33 years), with a pre-diagnosis of a mass. Tumor sizes ranged from 0.4 cm to 16 cm. The average tumor size was 5.1 cm. Histopathologically, 51 (87.9%) cases were diagnosed with germ cell tumor. The most common diagnosis among germ cell tumors was classical seminomas (n=23 (45.1%)).

Conclusion: Testicular orchiectomy surgery can be performed at any age depending on many different indications. Diagnoses vary from benign to malignant. Multiple sampling should be done to show the presence of GCNIS, which was highlighted in the last WHO 2016 classification, in testicular tumors, especially when diagnosing malignancy. Factors determining the prognosis such as lymphovascular invasion, rete testis invasion, and tumor size must be specified in the report.

**Keywords:** Testis, Orchiectomy, Cryptorchidism, Tumor

### Öz

Amaç: Orşiektomi testisleri unilateral veya bilateral eksize etmek için uygulanan cerrahi işlemin adıdır. Eksizyon nedenleri arasında torsiyon/enfarktüs, enfeksiyon, malignite, kriptorşidizm gibi primer etyolojiler ile birlikte prostat kanserine sekonder yapılan terapötik kastrasyon sayılabilir. Bu çalışmanın amacı orşiektomi uygulanan hastaların klinikopatolojik özelliklerini belirlemek ve bölgesel verileri elde etmektir.

Yöntem: Bu çalışmada Ocak 2015 – Aralık 2019 tarihleri arasında SBÜ Mehmet Akif İnan Eğitim ve Araştırma Hastanesi Patoloji Laboratuvarı arşivinde kayıtlı 316 orşiektomi materyali retrospektif olarak tarandı. Histopatolojik tanıları, testis sağ-sol lokalizasyonu, hastaların yaş aralığı ve orşiektomi endikasyon verileri incelendi.

Bulgular: Çalışmaya alınan 316 adet olgunun yaşları 1 ile 88 arasında değişirken yaş ortalaması 26 idi. Orşiektomi materyalleri içinde inmemiş testis 129 (%40,8) olgu ile en sık neden olarak bulundu. 300 (%94,9) olguya unilateral, 16 (%5,1) adet olguya bilateral orşiektomi uygulandığı görüldü. Kitle ön tanısı ile 58 olguya orşiektomi uygulanmıştır. Yaş dağılımı 14-68 arasındaydı (ortalama yaş 33). Tümör boyutları 0,4 cm ile 16 cm arasında değişmekteydi. Ortalama tümör boyutu 5,1 cimdi. Histopatolojik olarak 51 (%87,9) olgu germ hücreli tümör tanısı aldı. Germ hücreli tümörler içinde de en sık tanı 23 (%45,1) olgu ile klasik seminomdu.

Sonuç: Testis orşiektomi cerrahisi her yaş da bir çok farklı endikasyona bağlı olarak yapılabilmektedir. Benignden maligniteye kadar değişen tanıları verilebilmektedir. Özellikle malignite tanısı konulurken son DSÖ 2016 testis tümörlerinde vurgulanan GCNIS varlığını gösterebilmek için çoklu örnekleme yapılmalıdır. Prognozu belirleyen lenfovasküler invazyon, rete testis invazyonu, tümör boyutu gibi faktörler raporda mutlaka belirtilmelidir.

**Anahtar kelimeler:** Testis, Orşiektomi, Kriptorşidizm, Tümör

## Introduction

Testis, a paired organ that lies within the scrotum, is suspended by the spermatic cord in which sperms are produced and the male hormone called testosterone is secreted. Each testis weighs between 15–19 grams in adults [1]. Some of the lesions of the testicles include cryptorchidism, epididymo-orchitis, testicular torsion and malignancies [2], depending on which, various symptoms such as abdominal mass, scrotal swelling, and pain may be observed [3].

Orchiectomy indicates surgical excision of the testicles unilaterally or bilaterally. The causes of excision include primary etiologies such as torsion/infarction, infection, malignancy, cryptorchidism, and therapeutic castration secondary to prostate cancer [2]. Testicular cancers constitute about 1-2% of all male malignancies. Although malignancies peak between the ages of 15-40 years, they can be observed in all age groups [4-5]. Physical examination and anamnesis, serum tumor marker levels, and scrotal ultrasonography are used in diagnosis. Orchiectomy is important for both treatment and histopathological diagnosis, with which tumor subtypes can be identified. Lymphovascular invasion (LVI), tunica vaginalis invasion, spermatic cord invasion, and scrotal invasion can be detected by histopathological examination of orchiectomy materials to show the T stage of the tumor [6]. It is necessary to be aware of the variety of etiology and histopathological diagnoses of orchiectomy. The aim of this study is determining the clinicopathological features and patients undergoing orchiectomy and obtaining regional data.

## Materials and methods

Approval for this study was granted by Harran University Ethical Committee (27.01.2020/02/ no:18). Histopathological diagnoses, right-left localization, age range of patients and causes of orchiectomy in 316 orchiectomy materials obtained in the University of Health Science Turkey, Mehmet Akif İnan Training and Research Hospital, between January 2015 and December 2019 were investigated through the pathology archive. Routine hematoxylin-eosin (H&E) stained slides and immunohistochemical studies of cases previously diagnosed with malignancy were re-evaluated. Classification and pathological staging were performed according to the 2016 World Health Organization classification of urinary system and male genital organ tumors. Findings with definitive diagnoses were presented to contribute to the literature.

## Results

The mean age of 316 patients included in the study was 26 years (range: 1-88 years). Undescended testis was the most common cause of orchiectomy, with 129 (40.8%) cases (Figure 1). The other reasons included torsion in 71 cases (22.5%), mass in 58 cases (18.4%), and abscess/Fournier gangrene/orchitis in 42 cases (13.3%) (Table 1) (Figure 2).

Fifty-eight (18.4%) and two hundred and fifty-eight (81.6%) cases were operated for neoplastic and non-neoplastic indications, respectively. One hundred and thirty-nine cases (43.9%) underwent left, 96 (30.3%) cases underwent right, and 16 (5.1%) cases underwent bilateral orchiectomy. There were 67

cases (21.2%) without right-left localizations stated. Unilateral surgery was performed to all patients who were operated for neoplastic reasons, and 93.7% of patients were operated for non-neoplastic reasons. Indications for patients who underwent bilateral orchiectomy included prevention of increased libido in the mentally retarded patients, therapeutic castration for prostate cancer in older patients, infections, and gender determination for conditions such as testicular feminization and congenital adrenal hyperplasia.

Table 1: Distribution of orchiectomy indications

Causes of orchiectomy	n=316
Undescended testicle	129 (40.8%)
Torsion	71 (22.5%)
Mass	58 (18.4%)
Abscess / Fournier gangrene / orchitis	42 (13.3%)
Therapeutic castration due to prostate cancer	9 (2.8%)
Trauma	3 (1%)
Sex determination	2 (0.6%)
Preventing increase in libido	1 (0.3%)
Hernia	1 (0.3%)

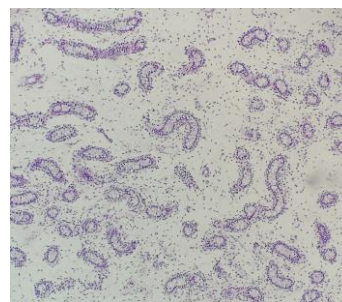


Figure 1: Undescended testicle: Atrophic testicle glands in edema stroma (HE, 100x)

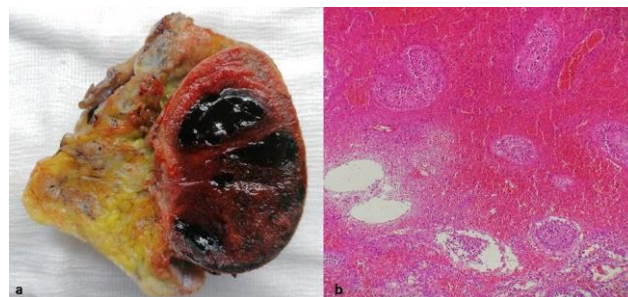


Figure 2: Torsion: Testicular bleeding and infarction in the glands (a: macroscopy, b: HE, 400x)

Orchiectomy was performed in 58 cases, whose age ranged between 14-68 years (Mean age: 33 years), with a pre-diagnosis of a mass. Tumor sizes ranged from 0.4 cm to 16 cm, with a mean tumor size of 5.1 cm. Based on 2016 World Health Organization Urinary system and male genital organ tumor classification, 51 (87.9%) cases were histopathologically diagnosed with germ cell tumor. The most common diagnosis among germ cell tumors was classical seminomas with 23 (45.1%) cases (Figure 3). Of the non-germ cell tumors, sex-cord stromal tumor was seen in 3 cases, mesenchymal tumors in 2 cases, hematologic malignancy in 1 case and simple cyst, in 1 case (Table 2).

Factors that have prognostic importance and affect staging in germ cell tumors were evaluated. Lymphovascular invasion was observed in 25 cases, perineural invasion in 3 cases, epididymis involvement in 6 cases, rete testicular involvement in 7 cases, tunica albuginea involvement in 5 cases, tunica vaginalis involvement in 6 cases, surrounding adipose tissue invasion in 2 cases, and spermatic cord involvement, in 5 cases. In tumors originating from in situ germ cell neoplasia, intratubular germ cell neoplasia was observed in 11 cases (Figure 4). According to the pathological tumor staging (pTNM) in the

eighth edition of the American Common Cancer Committee (AJCC), 19 cases were classified as pT1, 26 cases as pT2, 4 cases as pT3 and 2 cases as pT4. One case was at N1 stage with lymph node metastasis at the time of diagnosis. Also, during the follow-up, lung metastasis developed in one case in the third year after operation.

Table 2: Distribution of histopathological diagnoses of orchiectomies performed for neoplastic reasons

Tumors		n=58
Germ cell tumors		n=51 (87.9%)
Tumors derived from germ cell neoplasia in situ	Seminoma	23
	Embryonal Carcinoma	2
	Teratoma, Postpubertal Type	2
	Mixed Germ Cell Tumor	16
	Spermatocytic Tumor	2
Tumors unrelated to germ cell neoplasia in situ	Yolk Sac Tumor, Prepubertal Type	1
	Mixed Teratoma and Yolk Sac Tumor, Prepubertal Type	5
	Non-Germ cell tumors	n=7 (12.1%)
Sex cord-stromal tumors	Sertoli cell tumor	1
	Leydig cell tumor	2
Mesenchymal tumors	Liposarcoma	1
	Inflammatory myofibroblastic tumor	1
Hematolymphoid tumors	Diffuse large B-cell lymphoma	1
	Others	Simple cyst

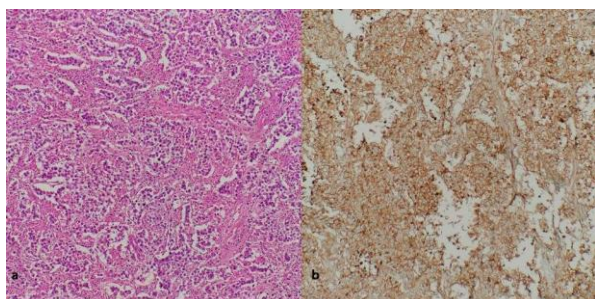


Figure 3: Seminoma: Tumor cells with fibrous septa and inflammatory cells (a: HE, 100x), PLAP positive stain (b: immunohistochemistry, 100x)

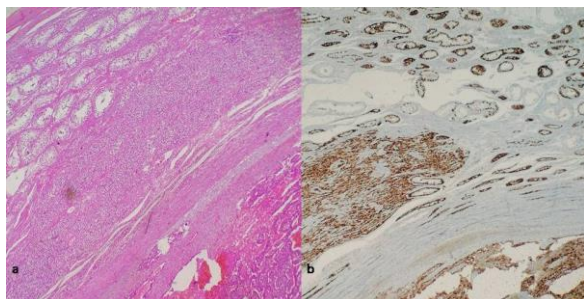


Figure 4: Intratubular germ cell neoplasia in embryonal carcinoma (a: HE, 100x) and PLAP positive stain (b: immunohistochemistry, 100x)

## Discussion

Orchiectomy can be performed in any age group with various indications. In our study, we found that the most common orchiectomy reason was undescended testicle. Unlike ours, in the study of Nwafor et al. [7] evaluating testis biopsies performed after orchiectomy and for infertility, they found that 60.9% of 64 cases in their series underwent therapeutic castration due to prostate cancer. The ages of 64 cases ranged between 4-86 years, with a mean age of 54 years. Similarly, Latheef et al. [2] reported that the most common indication for orchiectomy in their 23-case orchiectomy series was therapeutic castration for prostate cancer. They reported that the ages of most cases ranged between 50-70 years, with the youngest being a newborn and the oldest being 89 years of age. In our study, age distribution was between 1 and 88 years old, and unlike these two publications, since our most frequent orchiectomy indication was undescended

testicle, we found that our cases were younger, with a mean age of 33 years.

In their study investigating orchiectomy cases, Patel et al. [8] reported that 97.6% of orchiectomies performed for non-neoplastic reasons were unilateral, while orchiectomies for neoplastic reasons were completely unilateral. The most common indication for non-neoplastic orchiectomies was torsion. Sharma et al. [3] emphasized that all patients in their study underwent unilateral orchiectomy, and that right orchiectomy was performed in 58% of non-neoplastic lesions and 50% of neoplastic lesions. In their studies, the most common non-neoplastic orchiectomy indication was undescended testis with a rate of 39.6%. In our study, 139 (43.9%) cases underwent left, 96 (30.3%) cases underwent right, and 16 (5.1%) cases underwent bilateral orchiectomy. Unilateral surgery was performed in all patients operated for neoplastic reasons and 93.7% of patients operated for non-neoplastic reasons. Indications for patients who underwent bilateral orchiectomy were prevention of increased libido in mentally retarded patients, therapeutic castration for prostate cancer in older patients, infections, and gender determination for conditions such as testicular feminization and congenital adrenal hyperplasia. In the literature and the data in our study, the most common indications of laterality and orchiectomies vary.

Testicular cancers account for about 1-2% of all male malignancies. Although malignancy is mostly diagnosed between the ages of 15-40 years, it can be observed in all age groups [4,5]. Physical examination and anamnesis, serum tumor marker levels, scrotal ultrasonography are used in diagnosis, but orchiectomy is important for both treatment and histopathological diagnosis [6]. Yalçinkaya et al. [9] detected tumors in 139 (25.6%) cases in a series of 574 patients, and Bozkurt et al. [10] detected tumors in 45 (54.2%) of 83 orchiectomies. The mean ages of the cases reported by Yalçinkaya et al. [9] and Bozkurt et al. [10] were  $32.94 \pm 15.7$  years and 38.8 years, respectively. In our study, orchiectomy was performed in 58 (18.4%) cases with a pre-diagnosis of neoplasia. Akin to the literature, our patients' mean age was 33 years.

Germ cell tumors constitute 90-95% of testicular tumors, among which seminoma is the most common, with a rate of 50%. In the study of Yalçinkaya et al. [9], 92% of testicular tumors were germ cell tumors, and the most common was seminoma with 47 (36.7%) cases. Bozkurt et al. reported that 86.7% of tumors were germ cell tumors and classical seminoma was the most common, with 41%. In our study, we found that 87.9% (n=51) of 58 cases operated for neoplasia were germ cell tumors, like the literature, and seminoma was the most common, with 23 cases (45.1%).

The etiology of testicular neoplasia includes undescended testicles, in situ germ cell neoplasia, germ cell tumor history in contralateral testicle, testicular dysgenesis, consuming a high calorie diet and sedentary lifestyle [9,11]. We did not detect neoplasia among 129 undescended testicles and 2 testicular dysgenesis cases. With the understanding of the importance of germ cell neoplasia in situ (GCNIS) as a precursor lesion in testicular tumors, several changes were made in the classification of germ cell tumors in the WHO Urinary and Male Genital System Tumors 2016 edition, according to the derivation

of tumor from GCNIS [12]. To determine the presence of GCNIS, non-tumor testicular tissue and tumor passage sampling should be increased [13]. In our study, 43 of 51 germ cell tumors (84.3%) derived from GCINS. In 11 (25.5%) of these tumors, intratubular germ cell neoplasia was observed.

There are several factors to determine the prognosis in testicular tumors, including tumor size, LVI, rete testis invasion, tumor histology and serum tumor markers [11,14]. Scandura et al. [15] showed that tumor size and epididymis invasion are strong predictors in metastatic seminomas. For tumor size, the cut-off was 4.25 cm. Based on their literature search, they stated that some publications determined the cut-off tumor size as 3-4 cm and emphasized the importance of rete testis invasion. Warde et al. [16] emphasized that tumor size above 4 cm and rete testis invasion are crucial factors in predicting relapse. In our study, tumor sizes ranged from 0.4 cm to 16 cm, with a mean of 5.1 cm. Lymphovascular invasion was observed in 25 cases, epididymis was involved in 6 cases, rete testicular was involved in 7 cases, tunica vaginalis in 6 cases, surrounding adipose tissue, in 2 cases, and spermatic cord, in 5 cases. There was lymphovascular, rete testis and spermatic cord invasion in our classical seminoma case with lymph node metastasis at the time of diagnosis. The tumor size was 8 cm.

Prognostic factors are also important in pathological T staging. According to the current TNM staging system, which was revised for the 8<sup>th</sup> time in 2016 by the American Joint Cancer Committee, pathological T stage increases from pT1 to pT2 if the tumor is limited to the testicle, invades the rete testis and LVI and LVI without tunica albuginea involvement or epididymis invasion or spermatic cord invasion are present. Spermatic cord involvement corresponds to pT3, and tumors that invade the tunica vaginalis layer of the testicle and spread to the scrotum correspond to pT4. Spermatic cord invasion with the presence of LVI in the spermatic cord can be considered distant organ metastasis and can increase the stage to pM1 [13,17]. In our study, germ cell tumors were classified as pT1 in 19 cases, pT2 in 26 cases, pT3 in 4 cases and pT4 in 2 cases. One case was at N1 stage with lymph node metastasis at the time of diagnosis.

Approximately 8% of non-seminomatous germ cell tumors in stage 1 can cause lung metastasis and 29.3% can metastasize to retroperitoneal lymph nodes. These tumors include embryonal carcinoma, teratocarcinoma, yolk sac tumor and choriocarcinoma [18]. Lung metastasis developed in the third year after orchietomy in our case with mixed germ cell tumor (Seminoma + Embryonal carcinoma + Teratoma). This patient had a tumor size of 3.5 cm and lymphovascular invasion.

### Limitation

Since we work as a central pathology laboratory in the province, despite enough cases, our study was limited because we could not access information such as serum tumor markers and survey of patients from the hospital registry.

### Conclusion

Orchietomy surgery can be performed at any age with varying indications, with histopathological examination results varying from benign to malignant. Multiple sampling should be done to show the presence of GCNIS, which was highlighted in the last WHO 2016 testicular tumors guideline, especially when diagnosing malignancy. Factors determining the prognosis such

as lymphovascular invasion, rete testis invasion, and tumor size must be specified in the report.

## References

- In Juan Rosai: Rosai and Ackerman's Surgical Pathology 10th edition, Elsevier, Male reproductive system: Testis, 2011, pp.1334-74
- Latheef DA, Nayak R, Nuzhath DT, Shetty DP, Nair DV. Histopathological Assessment of Orchidectomy Specimens in a Tertiary Care Center. *International Journal of Innovative Research in Medical Science*. 2019;4(03):183-7. doi: 10.23958/ijirms/vol04-i03/591
- Sharma M, Mahajan V, Suri J, Kaul KK. Histopathological spectrum of testicular lesions- A retrospective study. *Indian Journal of Pathology and Oncology*. July-September 2017;4(3):437-41. 10.18231/2394-6792.2017.0094
- Shanmugalingam T, Soutati A, Chowdhury S, Rudman S, Van Hemelrijck M. Global incidence and outcome of testicular cancer. *Clin Epidemiol*. 2013 Oct 17;5:417-27. doi: 10.2147/CLEP.S34430.
- Park JS, Kim J, Elghiaty A, Ham WS. Recent global trends in testicular cancer incidence and mortality. *Medicine (Baltimore)*. 2018 Sep;97(37):e12390. doi: 10.1097/MD.00000000000012390.
- Stevenson SM, Lowrance WT. Epidemiology and Diagnosis of Testis Cancer. *Urol Clin North Am*. 2015 Aug;42(3):269-75. doi: 10.1016/j.ucl.2015.04.001.
- Nwafor CC, Nwafor NN. Morphologic patterns of testicular lesions in Uyo: A university hospital experience. *Sahel Med J*. 2019;22:18-22.
- Patel MB, Goswamy HM, Parikh UR, Mehta N. Histopathological study of testicular lesions. *Gujarat Medical Journal*. 2015;70(1):41-6.
- Yalçınkaya U, Çalısır B, Uğraş N, Filiz G, Erol O, Testis tümörleri: 30 yıllık arşiv tarama sonuçları, *Türk Patoloji Dergisi*. 2008;24(2):100-6.
- Bozkurt KK, Başpınar Ş, Akdeniz R, Bircan S, Koşar A. Testis tümörleri: 5 yıllık olgu serisi, *Med J SDU / S.D.Ü. Tıp Fak. Derg*. 2014;21(3):88-92.
- Leman ES, Gonzalgo ML. Prognostic features and markers for testicular cancer management. *Indian J Urol*. 2010 Jan-Mar;26(1):76-81. doi: 10.4103/0970-1591.60450.
- Williamson SR, Delahunt B, Magi-Galluzzi C, Algaba F, Egevad L, Ulbright TM, et al. The World Health Organization 2016 classification of testicular germ cell tumors: a review and update from the International Society of Urological Pathology Testis Consultation Panel. *Histopathology*. 2017 Feb;70(3):335-46. doi: 10.1111/his.13102.
- Karabulut YY. Erkek Genital ve Üriner Sistem Kanselerinde TNM Evrelemesinde Yapılan Değişiklikler. *Güncel Patoloji Dergisi*. 2018;2(2):57-63.
- Facchini G, Rossetti S, Berretta M, Cavaliere C, D'Aniello C, Iovane G, et al. Prognostic and predictive factors in testicular cancer. *Eur Rev Med Pharmacol Sci*. 2019 May;23(9):3885-91. doi: 10.26355/eurrev\_201905\_17816.
- Scandura G, Wagner T, Beltran L, Alifrangis C, Shamash J, Berney DM. Pathological risk factors for metastatic disease at presentation in testicular seminomas with focus on the recent pT changes in AJCC TNM eighth edition. *Hum Pathol*. 2019 Dec;94:16-22. doi: 10.1016/j.humpath.2019.10.004.
- Warde P, Specht L, Horwich A, Oliver T, Panzarella T, Gospodarowicz M, et al. Prognostic factors for relapse in stage I seminoma managed by surveillance: a pooled analysis. *J Clin Oncol*. 2002;20:4448-52.
- Evans AJ. An overview of recent WHO classification and AJCC pTNM staging changes for testicular neoplasms and their impact on the handling and reporting of orchidectomy specimens. *Diagnostic Histopathology*. 2018;24(6):pp.205-14. doi: 10.1016/j.mpdhp.2018.05.002
- Pfannschmidt J, Hoffmann H, Dienemann H. Thoracic metastasectomy for nonseminomatous germ cell tumors. *J Thorac Oncol*. 2010 Jun;5(6 Suppl 2):S182-6. doi: 10.1097/JTO.0b013e3181dcf908.

This paper has been checked for language accuracy by JOSAM editors.

The National Library of Medicine (NLM) citation style guide has been used in this paper.