

## Superior Mesenteric Artery Aneurysm due to Chronic Aortic Dissection

### Kronik Aort Diseksiyonuna Bağlı Superior Mezenterik Arter Anevrizması

İrfan Taşoğlu, Gökhan Lafci, Mahmut Ulaş, Doğan Sert, Şeref Alp Küçüker

Türkiye Yüksek İhtisas Hastanesi, Kalp-Damar Cerrahisi Anabilim Dalı, Ankara

#### Abstract

Superior mesenteric artery aneurysm has been anecdotally reported as a rare cause of epigastric pain. A 59-year-old woman was presented to our department because of epigastric pain for 2 weeks. DeBakey type I aortic dissection had been treated with Benthall procedure 3 years before the last admission. We successfully treated our patient with percutaneous endovascular stent placement instead of surgical operation. The use of endovascular techniques to manage superior mesenteric artery aneurysm should be considered in high risks patients

**Keywords:** Aneurysm, Mesenteric artery, Aortic dissection

**Application:** 31.05.2011 **Accepted:** 09.05.2011

#### Özet

Epigastrik ağrının sebepleri arasında superior mezenterik arter anevrizması nadir olarak bildirilmiştir. Elli dokuz yaşında kadın hasta 2 haftadır olan epigastrik ağrısı nedeniyle kliniğimize başvurdu. Hastanın hikâyesinde 3 yıl önce DeBakey tip I aortic diseksiyonu nedeniyle benthall prosedürü uygulandığı öğrenildi. Bizde hastamıza cerrahi operasyona gerek kalmadan başarıyla endovasküler stent uyguladık. Özellikle yüksek riskli hastalarda superior mezenterik arter anevrizmasının tedavisinde endovasküler tedavi seçeneği öncelikli olarak düşünülmelidir.

**Anahtar Kelimeler:** Anevrizma, Mezenterik arter, Aortic disseksiyon

**Başvuru Tarihi:** 31.05.2011 **Kabul Tarihi:** 09.05.2011

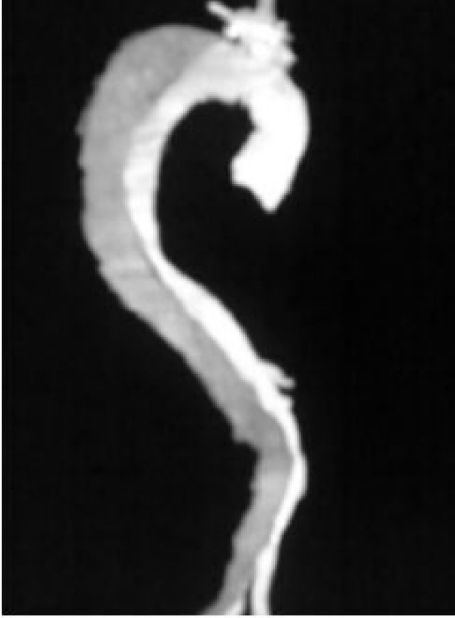#### Introduction

Although they are rare, aneurysms of the superior mesenteric artery (SMA) represent clinically important disease entity. About one third of SMA aneurysms result from infectious emboli due to infectious endocarditis. Nearly 22% of them require emergency treatment.<sup>1</sup> In the present case, a SMA aneurysm with concomitant DeBakey type I aortic dissection was found and successfully treated with a covered stent graft.

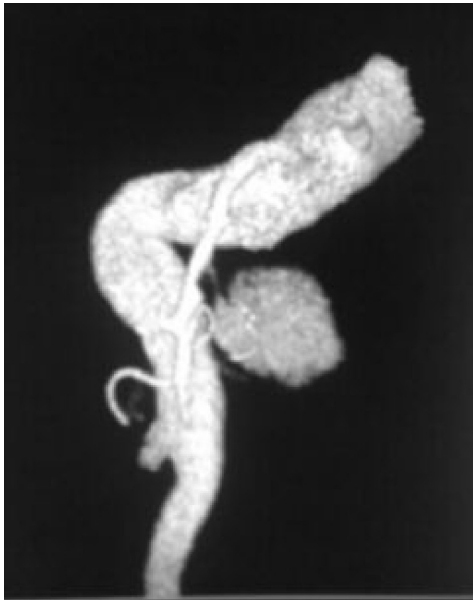
#### Case Report

A 59-year old woman was admitted to our hospital with the complaint of intermittent mid-epigastric pain that had been started 2 weeks earlier. Clinical history included mild hypertension but no previous systemic inflammatory diseases or systemic infections. DeBakey type I aortic dissection (*Figure 1*) had been treated with Benthall procedure 3 years before the last admission, and the patient had been treated medically, with metoprolol,

**Figure 1:** Computed tomography angiography showing an aortic dissection



**Figure 2:** Computed tomography angiography demonstrating an aneurysmal mass, 45 x 61mm in diameter, originating from the superior mesenteric artery

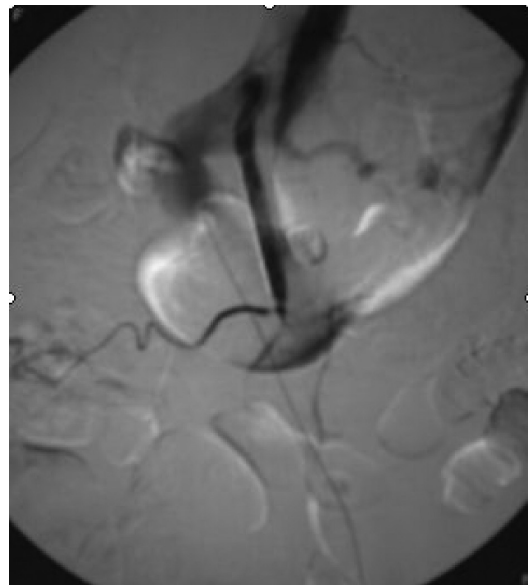


warfarin, and aspirin. On examination, she had epigastric tenderness, no abdominal mass, or organo-megaly, and

her peripheral pulses were palpable. Routine laboratory tests were normal. A saccular aneurysm which located 6x4 cm from the origin of the SMA and connected to it via a neck 9-mm in length was detected with mesenteric color duplex scan. An aneurysm that 45 x 61mm in diameter and chronic dissection of aorta were revealed in abdominal CT angiography (*Figure 2*).

We decided to proceed with percutaneous endovascular stent placement instead of surgical operation. Fluency covered stent (Bard, Tempe, AZ, USA) in 10 mm diameter and 40 mm length was then introduced. Final angiograms confirmed that the aneurysm was totally occluded and there were no distant emboli. The patient was placed on intravenous 1000 IU/h heparin infusion therapy during the night to protect the parent artery from early thromboembolic events and was discharged the third day; 75 mg clopidogrel PO/d for 2 months was added to his standard medications. Selective angiography 1 month later showed (*Figure 3*) that there was no flow in the aneurysm sac. The patient has remained completely asymptomatic for six months under medical therapy (metoprolol, acetylsalicylic acid and warfarin) up to now.

**Figure 3:** Selective angiography of SMA demonstrating no flow in the aneurysm



## Discussion

Visceral artery aneurysms are rare entities and found in only about 0.01% to 0.2% of the population. SMA aneurysms are the third most common visceral aneurysms after splenic and hepatic artery aneurysms and have an incidence of 5%. Patients with SMA aneurysms may be asymptomatic or may have symptoms.<sup>2,3</sup> To our knowledge, this is the first report describing SMA aneurysm caused by DeBakey type I aortic dissection, which was treated by endovascular covered stent graft.

The etiology of the SMA aneurysm is not clear. Most SMA aneurysms are mycotic in origin (58% to 63% of cases), occurring as a result of septic emboli in patients with left-sided endocarditis.<sup>4,5</sup> The infection is most commonly caused by nonhemolytic streptococcus. Atherosclerosis accounts for 20% of SMA aneurysms. Trauma is a rare cause (1% to 2%).<sup>4,5</sup> But type I aortic dissection has not been reported. We hypothesized that the hypertension and aortic dissection might cause the etiology of the SMA aneurysm in our patient. He had no history of inflammatory or infectious vascular diseases.

Patients with SMA aneurysms may be asymptomatic or may have symptoms of abdominal pain or mesenteric ischemia. Approximately one third of patients with visceral aneurysms present with rupture. The risk of rupture increases significantly when the aneurysm size reaches twice the normal vessel size. The rupture rate was found to be 38% for SMA aneurysms in a retrospective study of 21 patients.<sup>2</sup> Our patient had epigastric pain, no me-

senteric ischemia and rupture.

The treatment options for SMA aneurysms have been less uniform and range from conservative therapy to endovascular or open surgical treatment.<sup>5</sup> Various surgical techniques have been described for treatment of SMA aneurysms, including aorto-mesenteric bypass, thrombo-intimectomy with optional patch angioplasty, endo-aneurysmorrhaphy, and right gastro-epiploic artery-to-SMA bypass.<sup>2,5</sup> Operative mortality ranges from 19% to 56% in emergency situations and 3% to 10% in elective cases. Therapeutic options have evolved during the past decade from conventional surgical management toward a less invasive approach in visceral aneurysms. Currently there are additional options of laparoscopic surgical, endovascular, or percutaneous treatment. There are many different techniques of embolization using different materials, including coils, stent grafts, and liquid agents and concluded that these modalities are safe and feasible therapeutic options, but their long-term results have not yet to be determined.<sup>2,3</sup> Our patient had high operative mortality and morbidity (DeBakey type I aortic dissection had been treated with Bentall procedure 3 years before). Therefore we decided to proceed percutaneous endovascular stent placement.

In conclusion, we report the successful endovascular treatment of an SMA aneurysm secondary to DeBakey type I aortic dissection. It can be performed with lower complication rate by avoiding the risks of open surgery in high risk patients.

## References

1. Massive upper gastrointestinal bleeding due to a ruptured superior mesenteric artery aneurysm duodenum fistula. *J Vasc Surg.* 2008;48:735-7.
2. Güven K, Rozanes I, Kayabali M, Minareci O. Endovascular treatment of a superior mesenteric artery aneurysm secondary to Behcet's disease with Onyx (ethylene vinyl alcohol copolymer). *Cardiovasc Intervent Radiol.* 2009;32:159-62.
3. Sessa C, Tinelli G, Porcu P, Aubert A, Thony F, Magne JL. Treatment of visceral artery aneurysms: description of a retrospective series of 42 aneurysms in 34 patients. *Ann Vasc Surg.* 2004;18:695-703.
4. Gabelmann A, Go J, and Merkle EM. Endovascular Treatment of Visceral Artery Aneurysms. *J Endovasc Ther.* 2002;9:38-47.
5. Yun WS, Kim YW, Park KB, Cho SK, Do YS, Lee KB et al. Clinical and angiographic follow-up of spontaneous isolated superior mesenteric artery dissection. *Eur J Vasc Endovasc Surg.* 2009;37:572-7.