

POSTERİOR SERVİKAL LAMİNOFORAMİNOTOMİ YAPILAN HASTALARIN CERRAHİ SONUÇLARI : RETROSPEKTİF ÇALIŞMA

SURGICAL RESULT OF PATIENTS UNDERGOING POSTERIOR CERVICAL LAMİNOFORAMİNOTOMY : RETROSPECTIVE STUDY

Serhat YILDIZHAN, Mehmet Gazi BOYACI, Adem ASLAN

Afyonkarahisar Sağlık Bilimleri Üniversitesi Tıp Fakültesi, Beyin Cerrahi Anabilim Dalı

ÖZ

AMAÇ: Servikal disk hernilerine anterior veya posterior-dan yaklaşımı belirleyen birçok faktör vardır. Günümüzde posterior yaklaşım anterior girişime oranla daha az tercih edilmektedir. Bu çalışmamızda servikal disk hernisi ve servikal foraminal stenozu bulunan ve posterior girişime uygun olup bu yöntemle opere edilen hastaların post-operatif sonuçlarını değerlendirdik.

GEREÇ VE YÖNTEM: Haziran 2014 ve Haziran 2018 seneleri arasında posterior servikal yaklaşımla ameliyat edilmiş 28 hastanın, klinik ve post-operatif sonuçları tartışıldı.

BULGULAR: Posterior yaklaşımla ameliyat edilmiş 28 hastanın 16 tanesi erkek, 12 tanesi kadındı ve ortalama yaş 47.8 (yaş aralığı 40-66 yıl) idi. Hastaların hepsinde tek taraflı radikülopati şikayeti mevcuttu. 18 tanesi sol, 10 tanesi sağ taraf kaynaklıydı. Hastaların 16 tanesi yumuşak rüptüre servikal disk, 12 tanesi foraminal stenoz tanılı idi.

SONUÇ: Posterior servikal laminoforamınotomi seçilmiş hastalarda servikal disk hernisinde ve servikal foraminal stenozda en uygun seçeneklerden birisidir. Bu yöntem yumuşak rüptüre disk hastalarında daha iyi klinik sonuç vermektedir.

ANAHTAR KELİMELEER: Servikal disk hernisi, Foraminal stenoz, Posterior laminoforamınotomi

ABSTRACT

OBJECTIVE: Many factors determine the approach towards cervical disc hernias from the anterior or posterior. Nowadays, the posterior approach is less preferable compared to the anterior intervention. In this study, we evaluated the post-operative results of patients with cervical disc hernias and cervical foraminal stenosis who were suitable for posterior intervention and were operated on by this method.

MATERIAL AND METHODS: The clinical and post-operative results of 28 patients, who underwent surgery with the posterior cervical approach between June 2014 and June 2018, were discussed.

RESULTS: The 28 patients who underwent surgery with the posterior approach, 16 were male, 12 were female, and the mean age was 47.8 years (age range 40-66 years). All patients had a complaint of unilateral radiculopathy, with 18 of them on the left side and 10 of them on the right side. Sixteen of the patients had a soft ruptured cervical disc, and 12 were diagnosed with foraminal stenosis.

CONCLUSIONS: Posterior level laminoforamınotomi is one of the most suitable options in cervical disc hernias and cervical foraminal stenosis in the selected patients. This method provides better clinical results in soft ruptured disc patients.

KEYWORDS: Cervical disc hernia, Foraminal stenosis, Posterior laminoforamınotomi

Geliş Tarihi / Received: 04.11.2019

Kabul Tarihi / Accepted: 24.12.2019

Yazışma Adresi / Correspondence: Dr.Öğr.Üyesi Serhat YILDIZHAN

Afyonkarahisar Sağlık Bilimleri Üniversitesi Tıp Fakültesi, Beyin Cerrahi Anabilim Dalı

E-mail:serhatyildizhan07@gmail.com

Orcid No (Sirasıyla) : 0000-0001-9394-5828, 0000-0001-7329-2102, 0000-0001-9432-5399

INTRODUCTION

In terms of frequency, cervical disc hernias (CDH) are the 2nd most occurring disc hernias. In general, it is a condition characterized by pain, which occurs after waking up in the morning. It is seen in males between 30-45 years of age and most often in the C5-6 segment. The majority of patients with acute radiculopathy related to CDH are cured by medical treatment. Surgical treatment is recommended in patients where non-surgical methods have been unsuccessful or in cases with progressive neurological loss during treatment. Although anterior cervical discectomy and fusion (ACDF) are considered as the gold standard, posterior cervical foraminotomy has been proposed as an effective surgical treatment option in selected patients (1, 2, 3). Another group of patients who posterior cervical foraminotomy can be applied to, are patients with foraminal stenosis. The main advantages of the posterior approach are that the major vessels in the anterior approach, such as the oesophageal, trachea and similar other structures, are not in the surgical area, allowing for postoperative instability not developing and no fusion is required (4,5). Therefore, the movement of the cervical region is preserved, the operative time is reduced, and postoperative recovery is provided earlier. It also gives better results by removing the pressure on the posterior decompression nerve on the lateral hard discs (6,7). In this study, despite medical treatment for a long time, complaints were not eliminated or neurological losses were undetected. We compared the clinical outcomes of patients with the posterior approach, the surgical application of the disc hernia and patients with foraminal stenosis.

MATERIALS AND METHODS

This study retrospectively analyzed 28 patients with cervical disc hernias or with cervical foraminal stenosis of patient admissions in the posterior cervical region between June 2014 and June 2018 in the Neurosurgery Clinic of the Faculty of Health Sciences, University of Afyonkarahisar. The mean follow-up period was 12.3 ± 8.2 months. Sixteen of the cases were male and twelve were female patients. The mean age was 47.8 years (age range 40-66). Complaints were unilateral in all patients. All twenty-eight

patients had painful radiculopathy. Eighteen patients were affected in the left arm and ten in the right arm. In twelve patients, varying degrees of motor muscle strength was lost, eighteen patients had hypoesthesia and six patients had intrinsic muscle weakness. The most common was the C5-6, then the C6-7 level (**Table 1**).

Table 1 : Level Numbers of Patients Operated.

Distance	Soft Disc Rupture	Foraminal Stenosis
C3-4	1	-
C4-5	3	3
C5-6	8	6
C6-7	4	3

Patients were divided into two separate groups as the soft ruptured disc group A (n:16) and the foraminal stenosis group B (n:12) according to magnetic resonance imaging (MRI) and computed tomography (CT) images. Later, postoperative instability and clinical outcomes were compared with neck pain between the two groups. The criteria for the study were soft ruptured disc with posterolateral placement, foraminal stenosis, and facet arthropathy with foraminal compression. Patients with central spinal stenosis and myelopathy were excluded from the study. Preoperative evaluation was performed with two-way and dynamic cervical spine graphs, cervical CT and cervical MRI.

In all patients, at least 6 months into the postoperative period, dynamic cervical radiographs were evaluated for instability and the percentage of facetectomy was calculated with postoperative CT (percentage of facetectomy (%) = $(A-B) \times 100/A$ -**Figure 1**).

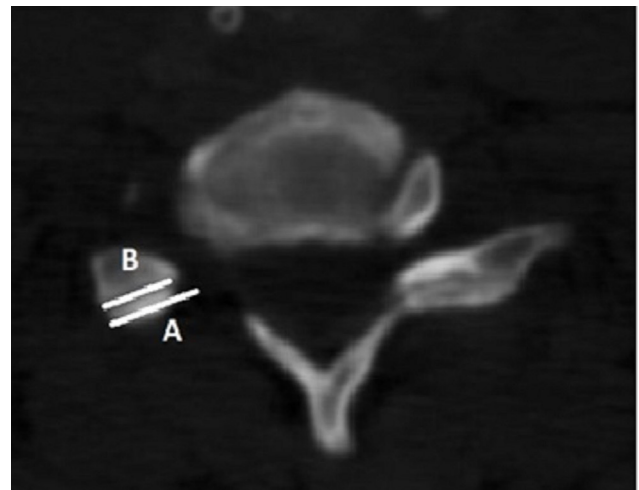


Figure 1 : Postoperatively computed tomography measured the length of the contra-lateral facet (A) and the remaining facet length (B) by measuring the facetectomy percentage. Facetectomy (%) = $(A-B) \times 100/A$

Neck and arm pain was evaluated with the pre-operative and postoperative visual analog scale (VAS) and Odam criteria (**Table 2**).

Table 2 : Odam Criteria

Excellent	All pre-operative symptoms have improved, abnormal findings have healed
Good	Preoperative symptoms persist in small quantities, abnormal findings unchanged or improved
Middle	No definitive improvement in pre-operative symptoms, other symptoms have not changed or have slightly improved
Bad	Symptoms and findings are unchanged or have increased

Informed consent was obtained from patients prior to their operation. The SPSS 12.0 statistical software package (SPSS, INC, Chicago, IL, USA) was used to analyze the statistics. The data was analysed appropriately using χ^2 and Student *t*-Tests. A value of $p < 0.05$ was considered statistically significant.

ETHICS COMMITTEE

Afyonkarahisar Health Sciences University, 01.03.2019 Date, 2019/106 number has been approved by the Ethics Committee.

SURGICAL TECHNIQUE

All patients were operated on in the prone position. By using horseshoe head support, the patients were given a slight flexion posture and the neck was positioned parallel to the ground to minimize the risk of epidural venous bleeding and air embolism. In order to verify the level, after obtaining lateral radiography, the skull and shoulder area were fixed with tapes to the bed and the folds in the skin were straightened. After applying a skin incision of around 2-2.5 cm, the muscles were removed and the surgical field was revealed. After the placement of the catheter, the superior and inferior vertebrae laminators were applied with hemilaminectomy and a partial facetectomy punch and high-speed drill after distance control.

Later, the ligamentum flavum was carefully dissected and resected through the lateral boundary of the stop and the nerve root with the help of a dissector. Following haemostasis, the soft disk was removed from the bottom of the nerve root with the appropriate hand tools. In patients with foraminal stenosis, the proximal stem was decompressed with the help of a drill. After haemostasis, anatomic floors were pro-

perly closed. All twenty-eight patients in our study were operated on with the same method.

RESULTS

There was no significant difference between the two groups in terms of the duration of preoperative symptoms and the VAS score. According to the postoperative modified Odom criteria, 93.75% (81.25% excellent, 18.75% good results) and 75% (50% excellent, 25% good) surgical success rates in patients with foraminal stenosis were found in the group of patients with ruptured discs, which was considered statistically significant ($p < 0.05$). A medial facetectomy degree (7.30 ± 1.45 mm, 42.6%) was found in the group of patients with foraminal stenosis (4.45 ± 1.25 mm, 32.6%) within the group with ruptured disc hernias. Postoperative wound infection developed in one of the patients and improved with medical treatment. Although a dura defect was not monitored during the operation in one patient, the CSF collection was seen in the postoperative images. The patients who did not have a scar discharge were medically followed and no problems were observed in their follow-up.

One of the patients with a ruptured disc hernia, and three of the patients with foraminal stenosis underwent ADCF with anterior intervention in a postoperative year (**Figure 2**).

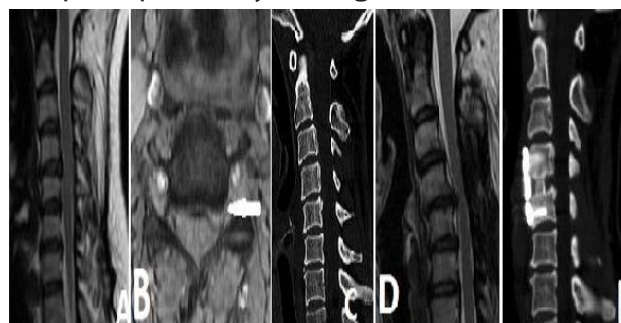

Figure 2: 43 years old female patient. Neck and left arm pain

A.B. Pre-operative cervical MRI of the C4-5 left disc hernia.
C. Cervical CT prior to operation.
D. 12th month post operation control Cervical MRI imaging of relapse of disc hernia.
E. ADCF with anterior intervention after the second operation.

DISCUSSION

The approach to cervical disc hernias with posterior laminoforaminotomy is rare nowadays and is a surgical technique applied to selected

patients and in certain centres. It was first reported in 1944 by Spurling and Scoville (6,8).

While anterior cervical surgery is usually indicated in the surgery of the midline and paramedian discs (9,10), the treatment of lateral or foraminal pathologies with an anterior or posterior approach is still controversial (11). The Posterior approach is accessible to all cervical segments.

It is also easier to remove lower or upper cervical nerve root busses in patients with a short and thick neck where anterior approaches are more difficult.

In the posterior approach, the primary indication is the non-unstable cervical soft lateral disc hernia. By conducting a laminoforaminotomy with the posterior approach, it is possible to relieve the root without disrupting the nucleus and anterior colon and protecting the movement segment, by emptying the disc that leads to the pressure.

The complications are less with the posterior intervention compared to the anterior application. Especially in the injuries of the oesophageal and trachea, there is virtually no risk of injury to the large artery and nerve. However, wound site infection, leakage of the cerebrospinal fluid together with dural tear, subcutaneous hematoma, blood loss with especially overweight patients due to the prone position and temporary or permanent nerve root manifestations after the posterior approach, can be observed. In our cases, wound infection in one patient and CSF (cerebrospinal fluid) collection with another patient was observed. Also, muscle and shoulder pain can be seen as a result of dissection of the rear elements and increase in angulations and kyphosis (1, 6, 12). This is because a large skin incision or excess muscle grazing occurred and the laminectomy had been made too wide.

Therefore, incision and muscle dissection are minimized to reduce pain.

In recent studies, in order to avoid cervical segmental hypermobility it is recommended, no more than 50% of facet joints should be removed to preserve joint stiffness. Unilateral and single-level partial facetectomies ensure a stable spine and contribute to less post-opera-

tive mechanical neck pain. In cases where more than 50% of the facets are taken, stabilization may be necessary to maintain the movement segment (1, 6, 7, 12, 13). In our study, the percentage of medial facetectomy was 32.6% in the group with a ruptured disc and 42.6% in the group with foraminal stenosis. Three patients who underwent medial facetectomy due to foraminal stenosis underwent anterior surgery in the postoperative 12 months due to instability.

It should be noted that the angle of lordosis before surgery should be removed from the posterior approach if the lordosis is below 10°.

Thus, it is also further away from the kyphosis which may develop in the postoperative period (6). This angle was taken into consideration when the posterior approach was selected in the patient group we operated on.

The posterior foraminotomy has a low complication rate in patients with a good indication of foraminal disc herniated and spondylotic foraminal stenosis, better decompression of the nerve root, is more advantageous compared to the anterior approach due to the lack of fusion and stabilisation. In addition, the operative time is shorter and blood loss is less (14,15).

Since the cervical distance is not entered, there is also less disc volume and this region is less exposed to compression forces, as opposed to the lumbar region in the sequestered cervical disc hernia, which is less common. Furthermore, there are publications expressing that they have never seen this in a series group of 800 patients (7). In some studies, this ratio was reported as 2-4% in anterior and 0.5-1% in posterior approaches (16).

In a study by Henderson and his colleagues, it was observed that 91.5% of patients obtained good and excellent results, and patients with disc hernias or cervical spondylosis, a statistically significant difference was not observed (2). Krupp et al. found that the values were better in those operated on due to ruptured soft disc (17), and Woertgen et al. reported that the results were worse in cases with stenosis (18). Yoo et al. found, in general 91.5% of cases to have good and excellent results, but 100% in patients with the soft disc, and 80% in patients

with foraminal stenosis (19). In our study also, we found that 93.75% of patients with soft disc were found to have excellent and good results, and in patients with foraminal stenosis, this rate remained at 75%.

The percentage of facet resection was suggested to be at least 25%, rarely 50% according to the degree of foraminal Pathology (4, 5, 20, 21).

In Zdeblick's et al. cadaveric study, it was found that the unilateral laminectomy did not liberalize the nerve root, with 25% of facetectomies it was 2.7 mm, with 50% facetectomies it was 5.9 mm, and 100% of facetectomies had 14 mm nerve root liberalization (5). Raynor et al. also found that 70% of facetectomies resulted in around 10 mm nerve liberalisation (4). However, it was found that with 50% and more of facetectomies highly likely caused instability (4,5). In the study of Yoo et al, 31.2% of facetectomies was sufficient for the removal of the soft disc, whereas in patients with foraminal stenosis, 48.8% of facetectomies were found to have lower clinical results (19). In our study, the facetectomy rate was 32% in patients with soft disc hernias and 42% in patients with foraminal stenosis. Nevertheless, three patients who underwent a facetectomy after foraminal stenosis had instability and underwent anterior surgery. It should be taken into consideration that additional factors affecting the facetectomy rate affect instability.

The posterior level "key-hole" approach for appropriate patients in the surgical treatment of cervical disc hernias is an alternative to the anterior approach. Successful results were obtained with a wide laminoforaminotomy in cases of soft lateral disc hernias and spinal stenosis connected to the osteophyte complex. This clinical study should be supplemented with a higher number of patients and be compared with the anterior approach with a more extensive series.

REFERENCES

1. Caglar YS, Bozkurt M, Kahilogullari G, Tuna H, Bakir A, Torun F, et al. Keyhole approach for posterior cervical discectomy: experience on 84 patients. *Minim Invasive Neurosurg.* 2007;50:7–11.
2. Henderson CM, Hennessy RG, Shuey HM, Jr, Shackelford EG. Posterior-lateral foraminotomy as an exclusive operative technique for cervical radiculopathy: a review of 846 consecutively operated cases. *Neurosurgery.* 1983;13:504–512.
3. Zeidman SM, Ducker TB. Posterior cervical laminoforaminotomy for radiculopathy: review of 172 cases. *Neurosurgery.* 1993;33:356–362.
4. Raynor RB, Pugh J, Shapiro I. Cervical facetectomy and its effect on spine strength. *J Neurosurg.* 1985;63:278–282.
5. Zdeblick TA, Zou D, Warden KE, McCabe R, Kunz D, Vanderby R. Cervical stability after foraminotomy. A biomechanical in vitro analysis. *J Bone Joint Surg Am.* 1992;74:22–27.
6. Chang JC, Park HK, Choi SK. Posterior cervical inclinatory foraminotomy for spondylotic radiculopathy preliminary. *J Korean Neurosurg Soc* 2011; 49: 308-13.
7. Clarke MJ, Ecker RD, Krauss WE, McClelland RL, Dekutoski MB. Same segment and adjacent segment disease following posterior cervical foraminotomy. *J Neurosurg Spine* 2007; 6: 5-9.
8. Kim CH, Chung CK, Kim HJ, Jahng TA, Kim DG. Early outcome of posterior cervical endoscopic discectomy: an alternative treatment choice for physically/socially active patients. *J Korean Med Sci* 2009; 24: 302-6.
9. Hunt WE, Miller CA. Management of cervical radiculopathy. *Clin Neurosurg.* 1986;33:485–502.
10. Samii M, Völkening D, Sepehrnia A, Penkert G, Baumann H. Surgical treatment of myeloradiculopathy in cervical spondylosis. A report on 438 operations. *Neurosurg Rev.* 1989;12:285–290.
11. Herkowitz HN, Kurz LT, Overholt DP. Surgical management of cervical soft disc herniation. A comparison between the anterior and posterior approach. *Spine (Phila Pa 1976)* 1990;15:1026–1030.
12. Harrop J, Silva MT, Sharan AD, Dante SJ, Simeone FA. Cervicothoracic radiculopathy treated using posterior cervical foraminotomy/discectomy. *J Neurosurg (Spine)* 2003; 98: 131-6.
13. Epstein NE. A review of laminoforaminotomy for the management of lateral and foraminal cervical disc herniations or spurs. *Surg Neurol* 2002; 57: 226-34.
14. Fressler RG, Khoo LT. Minimally invasive cervical microendoscopic foraminotomy: An initial clinical experience. *Neurosurgery* 2002; 51: 537-45.
15. Kunert P, Prokopienko M, Marchel A. Posterior micro-laminoforaminotomy for cervical disc herniation. *Neurol Neurochir Pol* 2010; 44: 375-84.

- 16.** Witzmann A, Hejazi N, Krasznai L. Posterior cervical foraminotomy. A follow-up study of 67 surgically treated patients with compressive radiculopathy. *Neurosurg Rev* 2000; 23: 213-17.
- 17.** Krupp W, Schattke H, Müke R. Clinical results of the foraminotomy as described by Frykholm for the treatment of lateral cervical disc herniation. *Acta Neurochir (Wien)* 1990;107:22-29.
- 18.** Woertgen C, Holzschuh M, Rothoerl RD, Haeusler E, Brawanski A. Prognostic factors of posterior cervical disc surgery: a prospective, consecutive study of 54 patients. *Neurosurgery*. 1997;40:724-728.
- 19.** Yoo HJ, Park JH, Seong HY, Roh SW. Comparison of Surgical Results between Soft Ruptured Disc and Foraminal Stenosis Patients in Posterior Cervical Laminoforaminotomy. *Korean Journal of Neurotrauma*. 2017; 13(2): 124-129.
- 20.** Baba H, Chen Q, Uchida K, Imura S, Morikawa S, Tomita K. Laminoplasty with foraminotomy for coexisting cervical myelopathy and unilateral radiculopathy: a preliminary report. *Spine*. 1996;21:196-202.
- 21.** Chen BH, Natarajan RN, An HS, Andersson GB. Comparison of biomechanical response to surgical procedures used for cervical radiculopathy: posterior keyhole foraminotomy versus anterior foraminotomy and discectomy versus anterior discectomy with fusion. *J Spinal Disord*. 2001;14:17-20.