

ÇOCUKLARDA NADİR BİR OLGU: LUDWIG ANJINA

A RARE CASE IN CHILDREN: LUDWIG ANGINA

¹Ayşegül BÜKÜLMEZ, ²Abdülkadir BUCAK, ¹Pelin BALIKOĞLU,
²Abdullah KINAR, ³Çiğdem ÖZER GÖKASLAN

¹Afyonkarahisar Sağlık Bilimleri Üniversitesi Tıp Fakültesi Çocuk Sağlığı ve Hastalıkları Anabilim Dalı

²Afyonkarahisar Sağlık Bilimleri Üniversitesi Tıp Fakültesi, Kulak Burun Boğaz Anabilim Dalı

³Afyonkarahisar Sağlık Bilimleri Üniversitesi Tıp Fakültesi, Radyoloji Anabilim Dalı

ÖZ

Günümüzde Ludwig Angina (LA), modern diş bakımı ve uygun antibiyotik kullanımına rağmen doktorlar için korkutucu bir hastalıktır. LA boyun ve ağız tabanındaki sublingual, submental ve submandibular bölgeyi içeren, yumuşak dokuların ilerleyici gangrenöz sellülitidir. En sık enfeksiyon kaynağı dental enfeksiyonlardır. Kötü ağız hijyeni önemli bir predispozandır. Hava yolu tıkanıklığı, LA'nın yaşamı tehdit edici bir komplikasyonudur. Hastaneye yatış ve agresif antimikrobiyal tedavi ile birlikte acil cerrahi tedavi gerektirebilir. Odontojenik ve üst solunum yolu enfeksiyonlarına bağlı gelişen LA çocuklukta nadir görülen bir hastalıktır. Bu olgu sunumunda diş çürümesine sekonder Ludwig Anjina tanısı alan 12 yaşında bir kız çocuğu sunuldu. Hasta acil servise ateş, disfaji, halsizlik ve ağızını açamama şikayetleri ile başvurdu. Hastanın trismus olması nedeniyle orofarenks muayenesi yapılamadı. Submental bölgede hassasiyet, şişlik ve hiperemi saptandı. Olgu parenteral antibiyotik tedavisi ve cerrahi drenaj sonrası taburcu edildi. Bu olgunun sunulmasındaki amaç LA yönetiminde erken tanı ve hızlı tedavinin önemini vurgulamak, hava yolunun sağlanmasının bu hastalarda öncelikli hedef olması gerektiğini hatırlatmaktır.

ANAHTAR KELİMELER: Ludwig anjina, Çocuk, Diş bakımı

ABSTRACT

Nowadays, Ludwig Angina (LA) is a terrifying disease for physicians despite the development of modern dental care and appropriate antibiotic use. LA is a progressive gangrenous cellulitis of the soft tissues, including the sublingual, submental and submandibular region of the neck and mouth. Dental infections are the most common source of the infection. Poor oral hygiene is an important predisposing factor. Airway obstruction is a life-threatening complication of LA. Hospitalization and aggressive antimicrobial therapy may require an immediate surgical treatment. LA is a rare disease caused by odontogenic and upper respiratory tract infections in childhood. In this case report, a 12-year-old girl who was diagnosed with Ludwig's Angina secondary to tooth decay has been presented. The patient presented to the emergency department with complaints of fever, dysphagia, malaise and inability to open his mouth. Oropharyngeal examination could not be performed because the patient had trismus. Tenderness, swelling and hyperemia in the submental region were diagnosed. The patient was discharged after the parenteral antibiotic treatment and surgical drainage. The aim of this case report is to emphasize the importance of early diagnosis and rapid treatment in LA management and to remind that the airway should be the primary target in these patients.

KEYWORDS: Ludwig angina, Children, Dental care

Geliş Tarihi / Received: 04.02.2019

Kabul Tarihi / Accepted: 01.10.2019

Yazışma Adresi / Correspondence: Doç.Dr.Ayşegül BÜKÜLMEZ

Afyonkarahisar Sağlık Bilimleri Üniversitesi , Çocuk Sağlığı ve Hastalıkları Anabilim Dalı

E-mail: aysegulbukulmez@yahoo.com

Orcid No (Sırasıyla) :0000-0002-6013-5172, 0000-0003-3031-3465, 0000-0002-0568-9965,0000-0002-2968-4165, 0000-0001-5345-1735

INTRODUCTION

Ludwig Anjina (LA) was described in 1836 by a physician named Karl Friedrich Wilhelm von Ludwig. It is an infection characterized by progressive gangrenous cellulitis and edema in soft tissues of mouth and deep neck (1,2). In the era of preantibiotic, the rapid progression of this infection to the oral cavity and oropharynx could not be prevented. Airway obstruction is the most common complication of this disease and mortality rate is between 54% and 60% (3).

The use of intravenous antibiotic therapy and airway patency have acted in the significant reduction of disease-specific mortality (4). Early diagnosis and rapidly treatment are important to prevent life-threatening acute airway obstruction (5). Ludwig Anjina has been mainly seen in middle-aged adults and rarely has been reported in children (6). However, the larynx is higher in children than in adults. Therefore, children are at higher risk in terms of airway obstruction. We report a case of a 12-year-old girl who was admitted to the pediatric emergency department with difficulty in swallowing and inability to open her mouth and was diagnosed with Ludwig's angina secondary to tooth decay. In this case report, it is aimed to increase the awareness of LA which is rarely seen in children and has lethal complications.

CASE

A 12-year-old girl was admitted to the pediatric emergency department with complaints of fever, dysphagia, weakness, and inability to open her mouth. It was found that she had that had continued for 3 weeks despite the combined antibiotic therapy. It was learned that complaints of swelling under the chin and dysphagia had increased for the last 3 days. In physical examination, Body temperature: 37.3 °C, Respiratory rate: 22/min, Peripheral pulse: 103 / min, Body weight: 46 kg (50-75 p) Length: 148 cm (25-50 p) were found. The oropharynx examination could not be performed because she could not open her mouth. She had tenderness, swelling and hyperemia in the submental region (**Figure 1**). Other system examinations were normal.

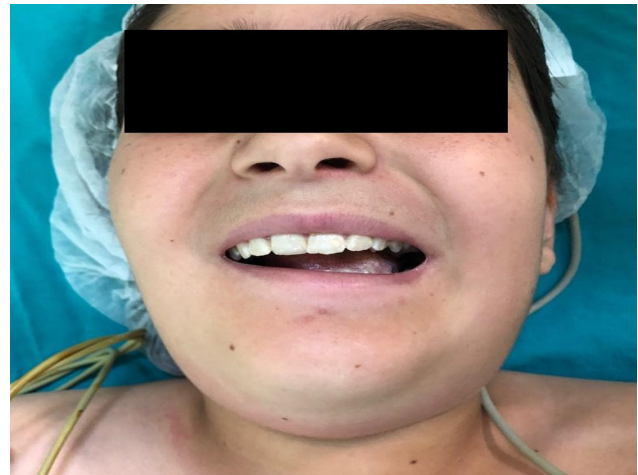

Figure 1: Swelling and hyperemia in the submental region

In laboratory tests, leukocytes: 13.200 / mm³; 82.3% neutrophils; 12.1% lymphocytes; 5.5% monocyte hemoglobin: 13.8 g / dl; hematocrit: 41,6; platelet: 229,000 / mm³ of C-reactive protein (CRP): 15.2; Sedimentation; 89 m/ h were found. The other laboratory values were normal. In the tomography, the abscess which was measured as 14x17x11 mm and reached from the right retromolar cavity to the submandibular area were found. There were enlarged lymph nodes in the size of 17x7 mm on both sides of the neck (**Figure 2a-2b**). No organisms were isolated in the blood culture.

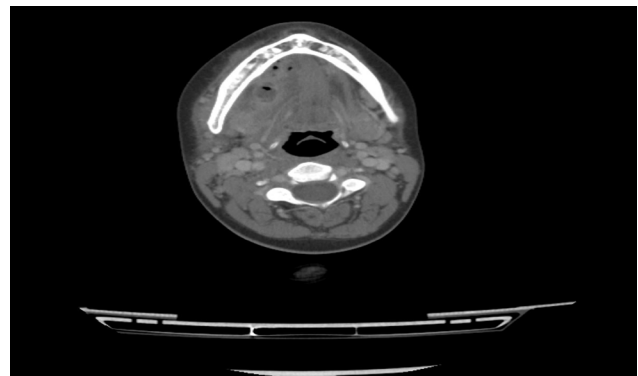


Figure 2a: Axial contrast-enhanced CT image. An abscess (ar-row) extending from right retromolar cavity to the base of the mouth and to the submandibular area with peripheral enhancement.

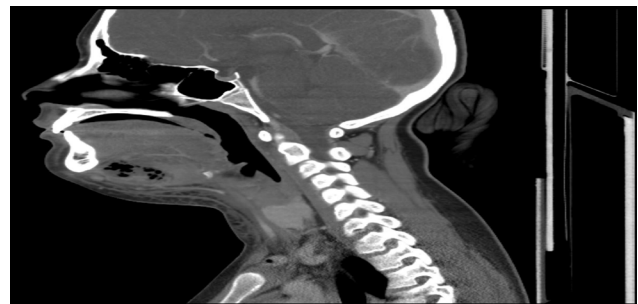

Figure 2b: Sagittal contrast-enhanced CT image. Air densities within the abscess (arrow) in the mouth floor, increased inflammatory density in the soft tissue, and enlarged lymph nodes in the submandibular region.

The patient was diagnosed as Ludwig's angina. Intravenous cefotaxime, clindamycin and vancomycin treatment were started in the emergency department. The abscess and hematoma were drained by otorhinolaryngology. Skin flora was produced in the abscess culture. The patient whose laboratory values returned to normal and whose clinical status regressed was discharged on the 10th day of the antibiotic treatment. Written and oral consent was obtained from the case.

DISCUSSION

Ludwig's angina (LA) is a serious infection of the soft tissues in the neck and the base of the mouth defined as rapidly progressing gangrenous cellulitis and edema (7, 8). The infection occurs most frequently after dental abscesses (9). Therefore, it is very important to interrogate about dental problems. Especially second and third molar teeth decays and gingiva infections are in charge of LA (7, 8, 10-12). Third molar tooth infection was present in this case.

Group A beta-hemolytic streptococci and *Staphylococcus aureus* are frequently detected in pediatric LA cases (4). The abscesses are most commonly caused by polymicroorganisms.

The abscesses contain gram-positive, gram-negative, anaerobic organisms and regresses with a broad-spectrum antibiotic therapy (13). It is usually not possible to take significant bacteriological data because the patients are given antibiotic treatment before hospitalization.

There was no significant reproduction in the abscess culture of the case.

Bilateral rigid, painful swelling and cellulitis, sublingual edema, elevation in the tongue and protrusion, dyspnea, fever, dysphagia and trismus are the most common symptoms in the submandibular and submental region. The neck is hardly edematous. Dyspnea may occur as a result of displacement of the cellulite (2, 8, 10,12).

Airway protection is very important in the treatment. Edema occurring in the oral cavity, tongue and supraglottic area is important as it may cause respiratory obstruction and may necessitate intubation. Intubation may cause damage

to the pharynx and larynx or laryngospasm or abscess contents to the bronchial tree (14, 15).

All patients should be given intravenous broad-spectrum antibiotic and fluid therapy immediately. Abscess drainage from submental and submandibular areas is performed to patients in whom medical treatment fails. The sample of abscess drainage should be used for culture. If necessary, antibiotherapy can be changed according to the culture result (1, 2, 8, 10).

The recommended initial treatment is high dose penicillin G in combination with an anti-staphylococcal drug or metronidazole. Intravenous dexamethasone administered for 48 hours is useful in reducing edema, which helps maintain airway integrity and increases antibiotic penetration (16).

The most common complications of Ludwig's angina are mediastinitis, asphyxia, septicemia and empyema. Carotid artery rupture, internal jugular vein thrombophlebitis, mandibular osteomyelitis, subfrenic abscess, aspiration pneumonia and pleural effusion are more rare complications. If the patient has diseases such as diabetes, neutropenia, lupus erythematosus, glomerulonephritis and aplastic anemia, these complications can be observed more common (15).

RESULT

In recent years, the incidence of Ludwig angina has declined by developing of dentistry and the increased importance of dental care. Infection of submandibular or sublingual origin, despite antibiotic use, may progress to LA within a few hours. Each facial soft tissue infection should be considered as a potential LA. Abscesses should be drained, decay teeth should be extracted or canal therapy should be implemented and a broad-spectrum antibiotic treatment should be started (14). Early diagnosis and treatment of Ludwig's angina are very important for preventing life-threatening complications such as airway obstruction.

Children should be taught about the importance of regular dental care and dental care training should be given in cooperation with pediatricians and dentists.

REFERENCE

- 1.** Barakate MS, Jensen MJ, Hemli JM, Graham AR. 2001 Ludwig's angina: report of a case and review of management issues. *Ann Otol Rhinol Laryngol.* 2001;110:453-6.
- 2.** Jimenez Y, Bagan JV, Murillo J, Poveda R. Odontogenic infections, complications, systemic manifestations. *Med Oral Patol Oral Cir Bucal.* 2004;9:139-47.
- 3.** An J, Singhal M. Ludwig Angina. 2018 Dec 6. StatPearls Internet]. Treasure Island (FL):StatPearls Publishing;2018 Jan-. Available from <http://www.ncbi.nlm.nih.gov/books/NBK482354>
- 4.** Srirompotong S, Art-Smart T. Ludwig's angina: a clinical review. *Eur Arch Otorhinolaryngol.* 2003; 260:401-3.
- 5.** Kremer MJ, Blair T. Ludwig anjin AANA J.2006;74: 445-51.
- 6.** Pandey M, Kaur M, Sanwal M, Jain A, Sinha SK. Ludwig's angina in children anesthesiologist's nightmare: Case series and review of literature. *J Anaesthesiol Clin Pharmacol.* 2017;33(3):406-9.
- 7.** Quinn FB Jr. Ludwig angina. *Arch Otolaryngol Head Neck Surg.* 1999;125:599.
- 8.** Polat G, Sade R. Radiologic Imaging of Ludwig Angina in a Pediatric Patient. *J Craniofac Surg.* 2018 ;29(6):603-4.
- 9.** Alpay HC, Karlıdağ T, Kaygusuz İ ve ark. Ludwig Anjini:26 Olgunun Retrospektif Analizi. *KBB BBC der.* 2008;16:119-24.
- 10.** Marple BF. 1999 Ludwig angina: a review of current airway management. *Arch Otolaryngol Head Neck Surg.*1999; 125:596-600.
- 11.** Saifeldeen K, Evans R. Ludwig's angina. *Emerg Med J.*2004; 21:242-3.
- 12.** Shockley WW. Ludwig angina: a review of current airway management. *Arch Otolaryngol Head Neck Surg.*1999; 125:600.
- 13.** Kavarodi AM. Ludwig'in anjina ile birlikte nekrotizan-fasiit - Bir olgu sunumu. *Saudi Dent J.* 2011; 23: 157-60.
- 14.** Iwu CO. Ludwig's angina: report of a seven cases and review of current concepts in management. *British Journal of Oral and Maxillofacial Surgery* 1990;28:189-93.
- 15.** Pak S, Cha D, Meyer C, Dee C, Fershko A. Ludwig's Angina. *Cureus.* 2017 21;9(8):1588.
- 16.** Busch RF, Shah D. Ludwig's angina: improved treatment. *Otolaryngol Head Neck Surg.*1997; 117:172-75.