

Hypersensitivity pneumonitis following intravesical BCG immunotherapy

Adem Sancı *¹, Eralp Kubilay¹, Efe Semetey Oğuz¹, Başak Gülpinar²

¹ Ankara University Faculty of Medicine, Urology Department, Ankara, Turkey. ² Ankara University Faculty of Medicine, Radiology Department, Ankara, Turkey.

Dear editor;

Herein, we report a case of hypersensitivity pneumonitis following intravesical Bacillus Calmette-Guérin (BCG) immunotherapy. We aim to increase awareness of a side effect of BCG instillation. A 74-year-old man was admitted with cough and fever (39.1 °C) following intravesical BCG immunotherapy for bladder cancer. He did not report any allergies or exposure to occupational or environmental organic substances. The abnormal laboratory test results were leukocyte count of 17100/mm³ (87% neutrophils), procalcitonin level of 4 ng/mL, erythrocyte sedimentation rate of 66 mm/h, and C-reactive protein of 112 mg/dL. Urine culture was negative. His chest radiograph revealed nonspecific minimal infiltrates. Piperacillin-tazobactam was initiated at 4.5 g/day, but the patient maintained a persistent fever, and respiratory failure occurred.

Therefore, he was transferred to the intensive care unit. For a more accurate diagnosis of respiratory failure, tumor markers, angiotensin-converting enzyme, immunoglobulin (Ig) G and M, serum IgG (precipitins) for birds and feathers, autoimmune screening, and serum protein electrophoresis were utilized. All of the parameters were in the normal ranges. Culture and polymerase chain reaction (PCR) for Mycobacterium spp. were negative, as were pneumococcal and Legionella antigen tests in the urine. Echocardiography, spirometry, and bronchoscopy results were normal. The cells in the bronchoalveolar lavage (BAL) were alveolar macrophages (41%) and lymphocytes (59%). Computed tomography (CT) of the chest revealed diffuse pulmonary infiltrates and ground-glass opacity similar to miliary tuberculosis (Figure 1).

***Corresponding Author:** Adem Sancı. Ankara University Faculty of Medicine, Urology Department, Ankara, Turkey.
Phone: + 90 534 928 11 30 **E-mail:** dr.adem88@hotmail.com
Received: Apr, 2020. **Accepted:** Sep, 2020.

This is an Open Access article distributed under the terms of the Creative Commons Attribution Non-Commercial License (<http://creativecommons.org/licenses/bync/4.0/>) which permits unrestricted non-commercial use, distribution, and reproduction in any medium, provided the original work is properly cited.



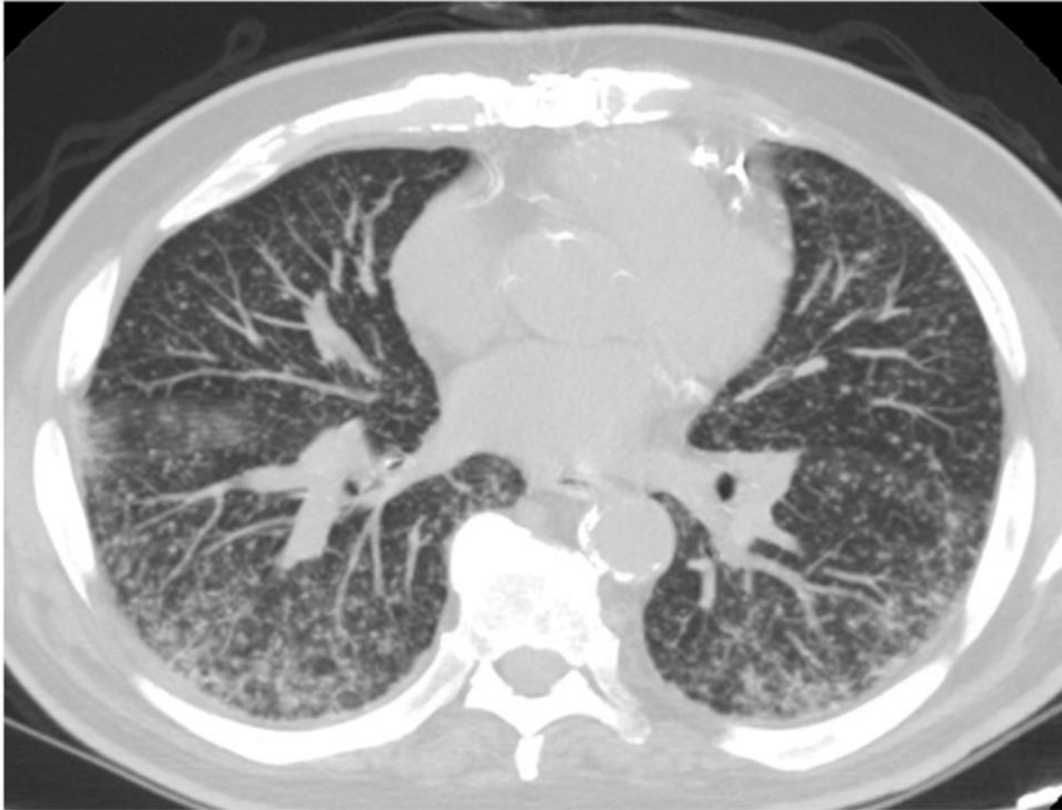


Figure 1. Diffuse pulmonary infiltrates and ground-glass opacity in both lungs.

The patient was treated with antituberculosis agents following the diagnosis by CT. However, the patient's fever persisted, and the oxygen requirement increased further. The findings from CT and the patient's persistent symptoms suggested that the correct diagnosis could be hypersensitivity pneumonia (HP) in response to BCG, so steroid treatment was prescribed (60 mg/days). At 24 hours after steroid treatment, the patient's symptoms and laboratory test results had improved dramatically. He was discharged on the 10th day following intravenous antibiotic and steroid treatment.

Bladder cancer (BC) is common in the male population (1). In patients with intermediate-risk and high-risk bladder tumors, BCG, which was first used for intravesical instillation by Morales et al. in 1976, can prevent the recurrence of BC (2). However, some systemic side effects may occur following BCG immunotherapy, including BCG sepsis, hepatitis, and HP (3). HP is an interstitial pulmonary disease caused by sensitization to some inhaled agents. It may also occur rarely after non-inhaled medications, such as intravesical BCG installation. To the best of our knowledge, this is quite seldom reported (4). The clinical presentation of HP varies from cough and fever to respiratory failure. HP is diagnosed by clinical, radiological, and immunological evaluations, including specific antibodies against BCG. The management of HP is based on steroid therapy and the withdrawal of the causative agent (5).

Our experience with this patient adds to what is known about the diagnosis and treatment outcomes of HP due to BCG instillation. After intravesical BCG immunotherapy, HP should be kept in mind in patients with resistant fever and progressive respiratory failure despite antibiotic and antituberculosis therapy, and it should not be forgotten that a dramatic

response can be achieved with steroid therapy. However, clinical trials are needed to achieve a better understanding of the clinical manifestations, diagnosis, and treatment options of patients with HP following intravesical BCG immunotherapy.

Ethics Committee Approval: NA

Informed Consent: NA

Peer-review: Externally peer-reviewed.

Conflict of Interest: No conflict of interest was declared by the author.

Financial Disclosure: The author declared that this study has received no financial support.

References

1. Ferlay J, Colombet M, Soerjomataram I, Mathers C, Parkin DM, Piñeros M, et al. Estimating the global cancer incidence and mortality in 2018: GLOBOCAN sources and methods. *Int J Cancer*. 2019 Apr 15;144(8):1941-1953.
2. Morales A, Eiding D, Bruce AW. Intracavitary Bacillus Calmette-Guerin in the treatment of superficial bladder tumors. *J Urol*. 1976;116(2):180-183.
3. Um SJ, Lee SK, Yang DK. Hypersensitivity pneumonitis following intravesical bacille Calmette-Guérin immunotherapy for superficial bladder cancer. *J Investig Allergol Clin Immunol*. 2009;19(3):230-232.
4. Carrasco Hernández L, Castaño Núñez AL, Rodríguez Portal JA. Hypersensitivity pneumonitis as a complication of intravesical BCG therapy for bladder cancer. *Arch Bronconeumol*. 2016 Aug;52(8):445-446.
5. Navarro C, Mejía M, Gaxiola M, Mendoza F, Carrillo G, Selman M. Hypersensitivity pneumonitis: a broader perspective. *Treat Respir Med*. 2006;5(3):167-179.



Medicine & Publishing

Published by The QMEL®.org
Medicine & Education & Library