

## Ekleme İçi Kalkaneus Kırıklarında Cerrahi Tekniklerin Karşılaştırılması

### Comparison of Surgical Techniques for the Treatment of Intraarticular Calcaneal Fractures

Mehmet Orçun Akkurt<sup>1</sup>, Vedat Biçici<sup>1</sup>, Özkan Öztürk<sup>2</sup>, İsmail Demirkale<sup>3</sup>

<sup>1</sup>Yıldırım Beyazıt Üniversitesi Yenimahalle Eğitim ve Araştırma Hastanesi, Ortopedi ve Travmatoloji Kliniği, Ankara

<sup>2</sup>Bismil Devlet Hastanesi, Ortopedi ve Travmatoloji Kliniği, Diyarbakır

<sup>3</sup>Sağlık Bilimleri Üniversitesi Keçiören Sağlık Uygulama ve Araştırma Merkezi, Ortopedi ve Travmatoloji Kliniği, Ankara



#### Özet

**GİRİŞ ve AMAÇ:** Ayrılmış eklem içi kalkaneus kırıklarının en uygun tedavisi tartışmalıdır. Bu çalışmada kalkaneus kırıklarında minimal girişimsel ve açık cerrahilerin klinik ve radyolojik sonuçlarının karşılaştırılması amaçlanmıştır.

**YÖNTEM ve GEREÇLER:** Yazarların kurumlarında 2010-2015 yılları arasında kalkaneus kırığı nedeniyle ameliyat edilen hastalar geriye dönük incelenmiştir. Hastalar, açık yerine koyma ve perkütan tespit olarak ikiye ayrılmış, daha sonra bu gruplar da Sanders sınıflamasına göre kendi içlerinde alt gruplara ayrılmıştır. İnversiyon-eversiyon hareket açıklıkları son kontrolde gonyometre ile ölçülmüştür. Fonksiyonel değerlendirme Amerikan Ayak ve Ayak Bileği Cemiyeti (AOFAS) ayak bileği-ardayak skalası ve Maryland Ayak Skorlaması (MFS) ile yapılmıştır. Ağrı 10 cm görsel analog skala (VAS) ile değerlendirilmiştir. Kalkaneus yüksekliği ve genişliği hem ameliyat öncesinde hem de son kontrol muayenesinde ölçülmüştür. Komplikasyonlar ayrıca değerlendirilmiştir.

**BULGULAR:** 42 hastanın 52 kalkaneusu açık yerine koyma yöntemiyle, 32 hastanın 40 kalkaneusu minimal girişimsel teknikle ameliyat edilmiştir. Her iki grup için de ortalama yaş 35 olup ortalama takip süresi 25,5 aydır. Yaş yönünden iki grup arasında anlamlı bir fark yoktur. Başvurudan ameliyata kadar geçen süre, açık cerrahi için 8,2 (2-14) gün, ve perkütan cerrahi için 2,5 (1-5) gündür. ROM, VAS, AOFAS ve Maryland skorları açısından iki grup arasında anlamlı bir fark yoktur. Cerrahi teknikten bağımsız olarak, Sanders 2 grubunda Sanders 3 grubundan daha iyi fonksiyonel skorlar elde edilmiştir. Kalkaneus yüksekliği, cerrahi teknikten bağımsız olarak düzelmiştir. Kalkaneus genişliği açık cerrahi ile daha başarılı düzelmiştir (p=0.001). Açık redüksiyon grubunda 3 derin enfeksiyon ve 5 diğer yara komplikasyonu görülmüşken minimal girişimsel cerrahiyle bu komplikasyonlar görülmemiştir.

**TARTIŞMA ve SONUÇ:** Kalkaneus kırıkları için her iki tedavi yöntemi de benzer klinik sonuçları sağlamıştır ama perkütan cerrahi ile daha erken ve daha az komplikasyonlu ameliyat avantajları mevcuttur. Sanders sınıflaması prognostik değer taşımaktadır.

**Anahtar Kelimeler:** Kalkaneus kırığı, minimal invazif, açık redüksiyon, Sanders sınıflaması

#### Abstract

**INTRODUCTION:** Optimal treatment for displaced intraarticular calcaneal fractures is controversial. We aimed to compare the clinical and radiological results of minimal invasive and open surgeries for calcaneal fractures.

**METHODS:** Patients with calcaneal fractures treated with surgery in the authors' institutions in 2010-2015 were retrospectively reviewed. Patients were divided into two groups, open reduction and percutaneous fixation and subdivided into groups according to Sanders classification. Inversion-eversion range-of-motions were measured with a goniometer on the last follow-up. Functional assessment was done with American Foot and Ankle Society (AOFAS) ankle-hindfoot scale and Maryland foot scores (MFS). Pain is assessed with a 10-cm VAS scale. Calcaneal height and width were measured both preoperatively and on the last follow-up. Complications were also assessed.

**RESULTS:** 52 calcanei of 42 patients were treated with open reduction and 40 calcanei of 32 patients were treated with minimal-invasive surgery. Mean age for both groups were 35 and mean follow-up was 25.5 months. There are no statistically significant differences between two groups, in terms of age. Mean time to surgery from admission was 8.2 (2-14) days in open reduction group and 2.5 (1-5) days in percutaneous reduction group. There are no statistically significant differences between two groups, in terms of ROM, VAS, AOFAS and Maryland scores. Functional scores were better in Sanders 2 group than Sanders 3 group, free from surgical technique. Calcaneal height restoration is independent from the surgical technique. Calcaneal width is more restored by open reduction (p=0.001). There are 3 deep infections and 5 other wound complications in the open-reduction group while there were wound complications with minimal-invasive surgery.

**DISCUSSION AND CONCLUSION:** Both treatment methods for calcaneal fractures end with similar clinical results but percutaneous fixation has advantages of early surgery and less complications. Sanders classification is prognostic.

**Keywords:** Calcaneal fracture, minimal-invasive, open reduction, Sanders classification

#### BACKGROUND

Calcaneal fractures are the most commonly seen tarsal bone fracture, as approximately 60% of the tarsal fractures are calcaneal fractures.

Calcaneal fractures are most commonly seen in males and especially in the 3rd decade (1). 75% of the calcaneal fractures include posterior articular facet of the calcaneus and subtalar

joint (2, 3). There is no consensus about the optimal treatment of calcaneal fractures. In their review, Bruce and Sutherland could not find a difference of functional status and quality of life between conservative management and surgical treatment of calcaneal fractures after three years (4). Buckley and Tough also reported similar results (5) but there are also some studies reporting better results of surgical management of calcaneal fractures in the middle and long term (6, 7). The main purpose of surgery of calcaneal fractures is maintaining the height and width of the calcaneus and restoring the subtalar joint, especially the posterior articular facet. Joint line can be better visualized and reduced with open reduction, but wound complications were reported up to 25% prevalence (8). Also, time of surgery is delayed because of the swelling of soft tissues around the calcaneus. Less invasive surgical techniques were described to treat faster and lessen the wound complications (9-12).

Because of the different opinions and approaches for the treatment of calcaneal fractures, we aimed to compare the functional results and complication rates of the open reduction and minimally invasive surgical approaches in our clinic.

## METHODS

After the ethical committee approval, results of the "open reduction, grafting and anatomical plate-screw fixation" and "percutaneous reduction, grafting and cannulated screw fixation" techniques for the treatment of the calcaneal fractures between years 2010-2015 were evaluated retrospectively.

The indications for surgical treatment were fractures with more than two millimetres displacement of the articular surfaces of the posterior facet, with a decrease in the Bohler's angle, varus malalignment of the tuberosity, and were same for both techniques. Additional trauma other than bilateral calcaneal fracture,

foot deformity, surgical history of foot, inflammatory arthritis, history of neurological problems and pregnancy were exclusion criteria. 92 calcaneal fractures of the 74 patients in accordance with these inclusion and exclusion criteria and having sufficient data for analysis were included in the study. Patients were divided into two groups according to the surgical technique performed as open reduction (OR, 52 calcanei of the 42 patients), and percutaneous reduction (PR, 40 calcanei of the 32 patients). Choice of surgical technique was done according to surgeon's choice and the available implants and Sanders classification was not regarded. As shown with chi-square test for independence, the surgical method chosen was not related with fracture classification ( $p=0.539683$ ).

All evaluation was made by an independent orthopaedist (HŞ), who did not know the purpose of the study. For determining intrarater reliability, randomly selected ten patients in each group were re-evaluated 20 days later (Cronbach's alpha coefficient=0.83). Demographical data, mechanisms of trauma, Gustillo-Anderson type of the open fracture, interval between admission and surgery and complications were harvested from the medical records of the patients. Fractures were classified according to Sanders' classification from coronal sections of the preoperative computerized tomograms (CT). Bohler's and Gissane's angles were measured from preoperative standard lateral radiograms of feet.

Elastic bandage, elevation and cold were applied to all the patients preoperatively. Operation was delayed in the OR group till the skin wrinkling test was positive. Mean time to surgery from admission was 8.2 (2-14) days in OR group and 2.5 (1-5) days in PR group. Surgery was performed after the decrement of skin oedema. Surgery was performed in semi-lateral position with regional or general anaesthesia. Tourniquet was used in only OR group. Lateral, axial and

Broden projection views were obtained by fluoroscopy when needed.

Extended lateral approach was utilised in OR group (13). Incision was started from the 2-3 cm proximal of the tip of lateral malleolus, just lateral of the Achilles tendon. Incision was extended distally till the fat tissue of the heel and then slid anteriorly to the basis of the 5th metatarsal gently. Skin, subdermal tissue and periosteum were elevated as a single layer. Peroneal tendon was retracted and calcaneofibular ligament was detached. Subtalar joint was found after the capsulotomy (Figure 1).

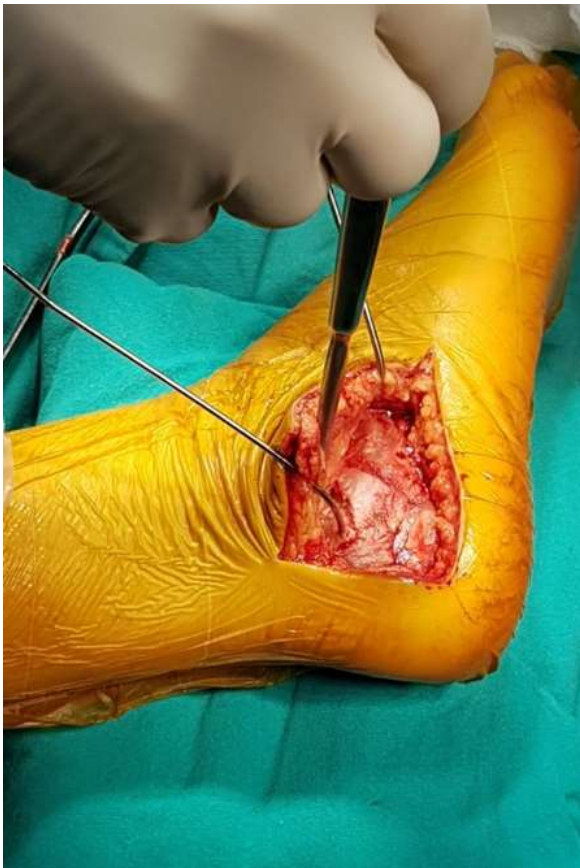


Figure 1. Subtalar joint

A Schanz screw was inserted to the posteroinferior corner of the calcaneal tuberosity to be used as a joystick. Lateral cortex was elevated gently and put in saline solution. Constant sustentacular fragment and tuberosity were reduced first and provisionally fixed with two Kirschner wires. Alignment of

heel was achieved in this stage, with great care to avoid varus alignment. Then, posterior facet was elevated with the help of a periosteum elevator and reduced. A Kirschner wire was inserted from the lateral aspect of the posterior facet to the subchondral bone of the medial constant fragment. A lag screw was implanted in this stage in some cases. Bony defects were filled with spongius allografts and especially posterior facet was built-up inferiorly. Lateral cortex was reinserted, anatomical calcaneal plate was implanted and fixed with screws in appropriate sizes (Figure 2).

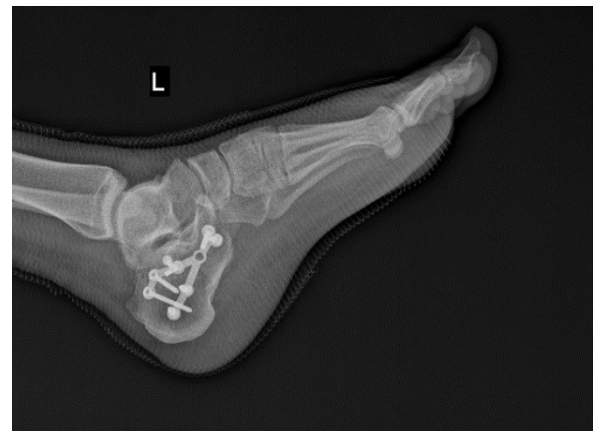

Figure 2. Lateral cortex

Hemovac drain was put and two-staged wound closure was done. Oedema treatment was continued one week more. Surgical drains were removed on the second day after the surgery. Ankle and subtalar joint range of motion exercises were started on the second day after surgery. Patients with unilateral fractures were mobilised without weightbearing after the second day. On follow-up, patients were allowed to walk with weightbearing on the affected foot, according to union of the fracture. Patients were called for follow-up in the outpatient clinic on postoperative 15th day, first month and monthly till the fracture union was achieved.

In the PR group, a Schanz screw was inserted to tuberosity fragment as a joystick. Tuberosity was reduced under fluoroscopic control with the help of the joystick Schanz. A 1-2 cm long

incision was made 1-2 cm distal to the tip of the lateral malleolus. After blunt dissection, posterior facet was elevated with a periosteum elevator. A Kirschner wire was inserted from the lateral aspect of the posterior facet to the subchondral bone of the medial constant fragment. Then, bony defects were filled, and posterior facet was built-up with spongyous allograft. Two 6.5-mm-calibred cannulated screws were implanted to calcaneal tuberosity, one projecting to calcaneocuboidal joint and one projecting medially. A cannulated screw was implanted on the Kirschner wire sent inferior to the posterior facet, if needed. Wound closure was done in standard manner. These patients were rehabilitated with the same programme with the OR group.

### Clinical Assessment

Inversion-eversion range-of-motions were measured with a goniometer on the last follow-up. Patients' pain was evaluated with Visual Analogue Scale (VAS) for pain consisting of 10-cm lines, the left end labelled 'No pain' (0 cm) and the right end 'Very severe pain' (10 cm). Functional assessment was done with American Foot and Ankle Society (AOFAS) ankle-hindfoot scale and Maryland foot scores (MFS) (14, 15).

### Radiological Assessment

Standard weightbearing lateral, and dorsoplantar anteroposterior (AP), 20° Broden (16) and axial radiograms were obtained on the last follow-up. Bohler's angle, calcaneal height and width and integrity of subtalar joint were evaluated on these radiograms. Calcaneal height was measured on lateral radiogram and width was measured on axial radiogram. Same radiograms of the contralateral foot were also obtained, and same measurements were evaluated. Then, changes were calculated as percentages of the normal. Bilateral cases were excluded from this measurement. Arthritic changes in the subtalar joint were assessed with Broden view and were graded using the Morrey

and Wiedeman scale (17) as used by Makki et al (18). Grade 0 means normal and Grade 3 means severe osteoarthritis OA.

### Statistical Analysis

Statistical analysis was performed using SPSS version 15.0 (SPSS, Inc., Chicago, IL). Consistency of the data with normal distribution was assessed using the Kolmogorov-Smirnov test. Parametric measurements were elaborated using the intergroup independent sample t-test and the non-parametric measurements were made using the Wilcoxon and the Mann-Whitney U-test.

## RESULTS

### Clinical Outcomes

Two patients in OR group and one patient in PR group were suffering from Gustillo-Anderson Grade 1 open fracture. There is no statistically significant difference between two groups in terms of functional scores. Mean ages, mean follow-up, mean inversion-eversion ROMs, mean AOFAS hindfoot and MFS scores of each group were summarized in Table I.

**Table 1.** Demographic data and functional scores of the patients. OR, open reduction; PR, percutaneous reduction; SD, standard deviation; ROM, range of motion; AOFAS, American Orthopaedic Foot And Ankle Society; MFS, Maryland Foot Score; VAS, Visual Analogue Scale

	OR	PR	P
Age (years) (min-max)	35 (21-60)	35 (22-64)	0.9573
Follow-up (months) (±SD)	25.5±6.9	25.6±7.9	0.8761
Inversion-eversion ROM (degrees) (±SD)	38.09±5.40	41.47±6.27	0.05118
AOFAS Hindfoot Score (±SD)	88.21±8.11	88.37±8.25	0.9681
MFS (±SD)	87.65±9.12	88.16±9.14	0.97606
VAS (/10) (±SD)	2.52±1.62	2.47±0.96	0.65994
Sanders 2* (n)	20	16	
Sanders 3* (n)	26	22	
Sanders 4* (n)	6	2	

\*p= .539683, chi-square test for independence

Mean inversion-eversion ROMs, mean VAS, AOFAS hindfoot and MFS scores at the latest follow-up were correlated with the fracture type (Table II).

**Table 2.** Relationship between functional results, surgical technique and Sanders classification. OR, open reduction; PR, percutaneous reduction; ROM, range of motion; AOFAS, American Orthopaedic Foot And Ankle Society; MFS, Maryland Foot Score; VAS, Visual Anal

		n	AOFAS	MFS	ROM	VAS
Sanders 2	OR	20	92.70±5.74	93.20±5.12	40.10±4.46	1.30±0.48
	PR	16	93.75±6.63	94.25±6.78	45.38±4.63	1.75±0.89
	Total	36	93.16±5.98	93.67±5.75	42.44±5.16	1.50±0.71
	p		0.602738	0.588051	0.0232	0.16758
Sanders 3	OR	26	84.77±8.14	83.38±9.35894	36.54±5.71	3.46±1.56
	PR	12	84.45±7.20	83.73±8.18646	38.64±5.89	3.00±0.63
	Total	48	84.62±7.56	83.54±8.65262	37.50±5.76	3.25±1.22
	p		0.886307	0.891837	0.207421	0.50286
p			<0.05	<0.05	<0.05	<0.05

The comminution of the articular facet of calcaneus, in terms of Sanders group, is associated with poor functional results. Effect of surgical method on clinical results in three Sanders group were also analysed separately, and surgical method was found to be nonrelated with functional result (Table II).

**Table 3.** Change in Bohler's Angle, calcaneal height and width. OR, open reduction; PR, percutaneous reduction; SD, standard deviation

	OR	PR	p
Preoperative Bohler's Angle (degrees) (±SD)	7.4±5.0	6.9±6.5	0.763
Follow-up Bohler's Angle (Degrees) (±SD)	26.2±6.1	24.8±6.2	0.642
Follow-up Calcaneal Height (mm) (±SD)	47.7±4.5	46.1±5.7	0.271
Calcaneal Width (mm) (±SD)	50.2±3.7	55.1±3.4	0.001
Calcaneal Height (% of uninjured calcaneus)*	97.0±5.8	94.9±4.1	0.302
Calcaneal Width (% of uninjured calcaneus)*	100.1±5.3	114.3±10.2	0.001

### Radiological Assessment

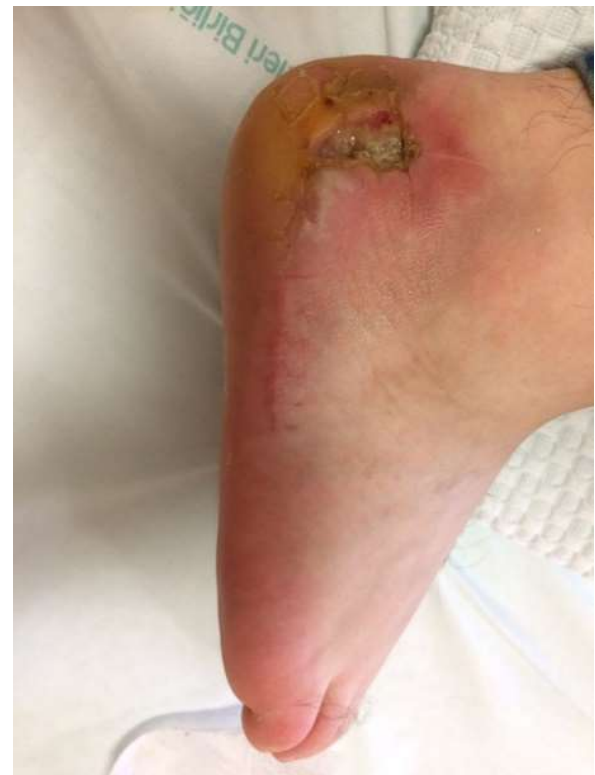Bohler's angle was significantly increased in both groups, but there is no statistically significant difference between the groups. Changes of Bohler's angle, measurements of calcaneal height and width in the last follow-up and comparison of calcaneal height and width in OR and PR groups were shown in Table III. As seen

in Table III, calcaneal width is above the uninjured side in PR group, but equal in OR group. There is no correlation between the type of surgery and calcaneal height, and calcaneal height was restored with surgery (Table III).

In OR group, grade 1 subtalar OA developed in two patients, grade 2 in one patient and grade 3 in one patient. In PR group, grade 1 subtalar OA developed in three patients and grade 2 in one patient. Both of the grade 3 OA patients were Sanders Type 4 fractures.

### Complications

Deep infection happened in three patients in OR group. All of them healed with parenteral antibiotics. No deep infection occurred in PR group. Wound complications, except infection, occurred in five patients in OR group (Figure 3).



**Figure 3.** A wound complication

Four of them were treated with serial débridement and secondary wound healing. One of them needed skin graft for wound closure after the debridement. Five of the patients in the OR group complained about pain related to implants and these implants were removed. On follow-up no peroneal tendon subluxation was diagnosed in the patients. No deaths related to

surgery happened. Overall prevalence of complications in the OR group was %25.

## DISCUSSION

Optimal surgical treatment of displaced intraarticular fractures of calcaneus is controversial. According to the literature, lateral approach is generally associated with more wound complications (19-21), and our prevalence of wound complications with lateral approach is near the literature and no wound complications were observed in the PR group.

When the issue of functional results is addressed, there are conflicting results. There are some studies reporting worse results with minimal-invasive techniques (22-25), and some reporting better results with minimal invasive techniques in Sanders Type 2 fractures of the calcaneus (26). According to our findings, there are no significant differences in terms of AOFAS and MFS scores, ROM and VAS between OR and PR. Mean AOFAS score was  $88.21 \pm 8.10$  in OR group and  $88.37 \pm 8.25$  in PR group. 76.9% of the patients in OR group and 80% of the PR group had excellent or good results. This result is concordant with the results reported in some other studies (20, 21, 27).

There are lots of classification systems for calcaneal fractures and Sanders classification is one of the most widespread. Prognostic value of it is arguable. Some authors reported that Sanders classification has prognostic value (25, 28, 29), but some others did not support this (30-32). Our data shows that Sanders classification has prognostic value. In our study, we showed that Sanders 2 fractures ends up with better clinical results than Sanders 3, and Sanders 3 ends up with better results than Sanders 4. Due to small group size, we could not conclude about the efficacy of any treatment method for Sanders 4 fractures, but PR is shown to be effective in treatment of Sanders 2 and 3 fractures.

Lots of minimally invasive techniques for treatment of calcaneal fractures exist. Minimally invasive plating (33, 34), intramedullary nailing (35, 36), external fixation (37), percutaneous balloon-plasty (38) and percutaneous screwing

(19-21, 24, 26, 27) are some of these methods shown to be successful in terms of radiological and clinical outcomes and have less complications. Our method, described in the "Material-Method" section of this article, is as successful as the other methods mentioned above, and it only costs two cannulated screws. Chen et al (39) recommended calcium sulphate cement grafting with percutaneous screwing and reported good clinical and radiological outcome with this method, but according to our study, this seems needless.

As far as we know, this is the first study demonstrating that only two cannulated screws will be enough for satisfying clinical and radiological results. Our percutaneous fixation method has advantages of early surgery, low complication rates and satisfactory clinical results for Sanders 2 and 3 calcaneal fractures. We did not make a cost analysis, but two screws are much cheaper than the other methods.

This study has some limitations. Firstly, because of its retrospective nature, some bias may be of concern, but as we showed statistically, there was no relation between the comminution of the fracture and surgical method chosen. Secondly, we did not evaluate the medical conditions such as diabetes mellitus and smoking, which were shown to be related with poorer outcomes (40), because of the possible imperfection of medical records. Thirdly, a relatively short follow-up period may mask some late stage complications such as arthritis of subtalar joint.

As conclusion, when closed reduction and percutaneous fixation is performed for the treatment of Sanders 2 and 3 calcaneal fractures, it is possible to have similar functional and radiological results with open reduction and internal fixation. Open reduction is characterized with delayed surgery and higher complication rates. It seems that the delay in surgery is not characterized with poorer clinical results, but economical return should also be a point of concern. Sanders classification has prognostic value. Randomised prospective studies with more patients are needed for further implications, but we suggest that closed reduction and percutaneous fixation should be

chosen in the treatment of calcaneal fractures, when available.

**Author Contributions:** All authors contributed equally in each part of the research and manuscript preparation.

Authors declare no conflict of interest

Authors declare no funding for this study.

## REFERENCES

1. Mitchell MJ, McKinley JC, Robinson CM. The epidemiology of calcaneal fractures. *Foot (Edinb)*. 2009;19(4):197-200
2. Nork SE, Barei DP. Ankle and hindfoot trauma. In: Fischgrund JS, editor. *Orthopaedic Knowledge Update, Rosemont*; American Academy of the Orthopaedic Surgeons; 2008. p. 493-509.
3. Clare MP SR. Calcaneal fractures. *Fuss Sprung* 2007; 5:58-73.
4. Bruce J, Sutherland A. Surgical versus conservative interventions for displaced intra-articular calcaneal fractures. *Cochrane Database Syst Rev*. 2013;1:CD008628
5. Buckley RE, Tough S. Displaced intra-articular calcaneal fractures. *J Am Acad Orthop Surg*. 2004;12(3):172-178
6. Kline AJ, Anderson RB, Davis WH, Jones CP, Cohen BE. Minimally invasive technique versus an extensile lateral approach for intra-articular calcaneal fractures. *Foot Ankle Int*. 2013;34(6):773-780.,
7. Rammelt S, Zwipp H, Schneiders W, Dürr C. Severity of injury predicts subsequent function in surgically treated displaced intraarticular calcaneal fractures. *Clin Orthop Relat Res*. 2013;471(9):2885-2898.
8. Folk JW, Starr AJ, Early JS. Early wound complications of operative treatment of calcaneus fractures: analysis of 190 fractures. *J Orthop Trauma*. 1999;13(5):369-372.
9. Forgon M, Zadavec G. Zu den Repositionen—und Retentionsproblemen der Kalkaneusfraktur. *Aktuelle Traumatol*. 1983;13(6):239-246.
10. Fernandez DL, Koella C. Combined percutaneous and “minimal” internal fixation for displaced articular fractures of the calcaneus. *Clin Orthop Relat Res*. 1993; 290:108-116.
11. Tornetta P 3rd. Percutaneous treatment of calcaneal fractures. *Clin Orthop Relat Res*. 2000; 375:91-96.
12. Gavlik JM, Rammelt S, Zwipp H. Percutaneous, arthroscopically-assisted osteosynthesis of calcaneus fractures. *Arch Orthop Trauma Surg*. 2002;122(8):424-428.
13. Gould N. Lateral approach to the os calcis. *Foot Ankle*. 1984 Jan-Feb;4(4):218-20.
14. Heffernan G, Khan F, Awan N, Riordain CO, Cor-rigan J. A comparison of outcome scores in os calcis fractures. *Ir J Med Sci*. 2000; 169:127-128.
15. Kitaoka H, Alexander I, Adelaar R, Nunley J, Myerson M, Sanders M. Clinical rating systems for the ankle, hindfoot, midfoot, hallux and lesser toes. *Foot Ankle Int*. 1994; 15:349–353.
16. Broden B. Roentgen examination of the subtaloid joint in fractures of the calcaneus. *Acta Radiol*. 1949; 31:85–88.
17. Morrey BF, Wiedeman GP. Complications and long-term results of ankle arthrodesis following trauma. *J Bone Joint Surg [Am]* 1980;62-A:777–784.
18. Makki D, Alnajjar HM, Walkay S, Ramkumar U, Watson AJ, Allen PW. Osteosynthesis of displaced intra-articular fractures of the calcaneum: a long-term review of 47 cases. *J Bone Joint Surg Br*. 2010;92(5):693-700.
19. Ene R, Popescu D, Panaitescu C, Circota G, Cirstoiu M. Low complications after minimally invasive fixation of calcaneus fracture. *Journal of medicine and life* 2013, 6.1: 80.
20. Pelliccioni AAA, Bittar CK, Zabeu JLA. Surgical treatment of intraarticular calcaneus fractures of sanders' types ii and iii. Systematic review. *Acta Ortop Bras*. 2012;20(1):39-42
21. Fan B, Zhou X, Wei Z, Ren Y, Lin W, Hao Y, Shi G, Feng S. Cannulated screw fixation and plate fixation for displaced intra-articular calcaneus fracture: A meta-analysis of randomized controlled trials. *Int J Surg*. 2016 Oct;34:64-72
22. Khurana Ankit, Dhillon Mandeep S, Prabhakar Sharad, John Rakesh. Outcome evaluation of Minimally invasive surgery versus Extensile lateral approach in management of displaced intra-articular calcaneal fractures: A Randomised control trial. *The Foot* 2017; 31: 23-30
23. Wu J, Zhou F, Yang L, Tan J. Percutaneous Reduction and Fixation with Kirschner Wires versus Open Reduction Internal Fixation for the Management of Calcaneal Fractures: A Meta-Analysis. *Sci Rep*. 2016;6:30480
24. Biz C, Barison E, Ruggieri P, Iacobellis C. Radiographic and functional outcomes after displaced intra-articular calcaneal fractures: a comparative cohort study among the traditional open technique (ORIF) and percutaneous surgical procedures (PS). *J Orthop Surg Res*. 2016;11(1):92
25. V. Popelka, P. Simko, Surgical treatment of intra-articular calcaneal fractures, *Acta Chir. Orthop. Traumatol. Cech*. 2011;78: 106e113
26. Zeng Z, Yuan L, Zheng S, Sun Y, Huang F, Minimally invasive versus extensile lateral approach for Sanders type II and III calcaneal fractures: A meta-analysis of randomized controlled trials, *Inter J Surg*, 2018;50:146-53
27. Jin C, Weng D, Yang W, He W, Liang W, Qian Y. Minimally invasive percutaneous osteosynthesis versus ORIF for Sanders type II and III calcaneal fractures: a prospective, randomized intervention trial. *J Orthop Surg Res*. 2017;12(1):10
28. Rubino R, Valderrabano V, Sutter PM, Regazzoni P. Prognostic Value of Four Classifications of Calcaneal Fractures. *Foot Ankle Inter* 2009;30:3
29. Sanders R, Vaupel Z, Erdogan M, Downes K. Operative Treatment of Displaced Intraarticular Calcaneal Fractures: Long-term (10–20 Years) Results in 108 Fractures Using a Prognostic CT Classification. *J Orthop Trauma*. 2014 Oct;28(10):551-63
30. Alexandridis, G., Gunning, A.C., van Olden, G.D.J. et al.

- International Orthopaedics (SICOT) (2018) 42: 2231
31. Swords MP, Alton TB, Holt S, Sangeorzan BJ, Shank JR, Benirschke SK. Prognostic Value of Computed Tomography Classification Systems for Intra-articular Calcaneus Fractures. *Foot Ankle Interl* 2014; 35(10): 975–80
  32. de Vroome, Stefan W., and Frits M. van der. “Cohort Study on the Percutaneous Treatment of Displaced Intra-Articular Fractures of the Calcaneus.” *Foot Ankle Inter*, 2014; 35: 156–62
  33. Kline AJ, Anderson RB, Davis WH, Jones CP, Cohen BE. Minimally invasive technique versus an extensile lateral approach for intraarticular calcaneal fractures. *Foot Ankle Int*. 2013; 34(6):773-780
  34. Weber M, Lehmann O, Sägeser D, Krause F. Limited open reduction and internal fixation of displaced intra-articular fractures of the calcaneum. *J Bone Joint Surg Br*. 2008; 90(12):1608-1616
  35. Zwipp H, Paša L, Žilka L, Amlang M, Rammelt S, Pompach M. Introduction of a new locking nail for treatment of intraarticular calcaneal fractures. *J Orthop Trauma*. 2016; 30(3):e88-e92.
  36. Reinhardt S, Martin H, Ulmar B, et al. Interlocking nailing versus interlocking plating in intra-articular calcaneal fractures: a biomechanical study. *Foot Ankle Int*. 2016; 37(8):891-897.
  37. Elgamal TA, Tanagho AE, Ferdinand RD. Temporary external fixation facilitates open reduction and internal fixation of intra-articular calcaneal fractures. *Acta Orthop Belg*. 2013; 79(6):738-741.
  38. Jacquot F, Letellier T, Atchabahian A, Doursounian L, Feron JM. Balloon reduction and cement fixation in calcaneal articular fractures: a five-year experience. *Int Orthop*. 2013; 37(5):905-910.
  39. Chen L, Zhang G, Hong J, Lu X, Yuan W. Comparison of percutaneous screw fixation and calcium sulfate cement grafting versus open treatment of displaced intra-articular calcaneal fractures. *Foot Ankle Int*. 2011;32(10):979-85.
  40. Wei N, Zhou Y, Chang W, Zhang Y, Chen W. Displaced Intra-articular Calcaneal Fractures: Classification and Treatment. *Orthopedics*. 2017;40(6):e921-e929