

## Ağır Demir Eksikliği Anemisi ile Prezente Olan Hiatal Herni: Olgu Sunumu

### Hiatal Hernia Presenting With Severe Iron Deficiency Anemia: A Case Report

Neslihan Karakurt<sup>1</sup>, Ali Fettah<sup>2</sup>, İbrahim Karaman<sup>3</sup>

<sup>1</sup>Hitit Üniversitesi Çorum Eğitim ve Araştırma Hastanesi Çocuk Kliniği

<sup>2</sup>Dr. Sami Ulus Çocuk Sağlığı Ve Hastalıkları Eğitim ve Araştırma Hastanesi, Çocuk Hematoloji Onkoloji Kliniği

<sup>3</sup>Dr. Sami Ulus Çocuk Sağlığı Ve Hastalıkları Eğitim ve Araştırma Hastanesi, Çocuk Cerrahi Kliniği



#### Özet

Demir eksikliği anemisi (DEA) pediatrik popülasyonda sık görülür. Yetersiz demir alınımına bağlı nütrisyonel anemi en sık sebebidir. Ancak hayati tehdit eden ağır DEA ile başvuran hastalarda altta yatan sebep detaylı araştırılmalıdır. Dokuz aylık kız hasta halsizlik nedeniyle başvurduğunda hemoglobin 3,5 g/dl saptandı ve laboratuvar bulguları DEA ile uyumluydu. Hastada DEA etyolojisi araştırıldığında hiatal herni saptandı. Pediatriklerin ciddi veya medikal tedaviye dirençli DEA'nin hiatal herni ile ilişkili olabileceğinin farkında olması gerekir.

**Anahtar Kelimeler:** Demir Eksikliği Anemisi, Hiatal Herni, Pediatrik

#### Abstract

Iron deficiency anemia (IDA) is common in pediatric population. Nutritional anemia resulting from insufficient iron intake is the most common etiology. However, underlying reason leading to life threatening IDA is to be examined in details. A nine month old girl with a complaint of fatigue had a hemoglobin level was 3.5 g/dl and laboratory findings were compatible with iron deficiency anemia (IDA). She was evaluated for the etiology of IDA and she was diagnosed hiatal hernia (HH). Pediatricians should be aware of severe or medically refractory IDA, which may be related to HH.

**Keywords:** Iron Deficiency Anemia, Hiatal Hernia, Pediatrics

#### INTRODUCTION

Iron deficiency anemia (IDA) is common in pediatric population. Nutritional anemia resulting from insufficient iron intake is the most common etiology. Gastrointestinal blood loss and impaired malabsorption may cause IDA as well. Hiatal hernia (HH), a frequent finding in elderly individuals, is relatively rare in children. It is a well-known cause of gastrointestinal blood loss in adults, however it is an overlooked etiology of IDA in children (1). Here in we report a case with severe IDA who was diagnosed HH. IDA resolved after surgical intervention.

#### CASE REPORT

A nine month old girl with a complaint of fatigue was visited. She was born from a twin pregnancy of a 21 year old mother with a weight of 2800 gr. Her past medical history was

uneventful, she did not neither receive any blood component nor use iron medication. She was breastfed for 5 months and then she started to consume cow milk (0.5 lt/day) and soups. Her mother had chronic ITP, her father was healthy and there was no consanguinity. The twin sister of the patient was operated with a diagnosis of HH at four months old.

In the physical examination she was weak, pale and tachycardic; she did not have any dysmorphic sign. Her weight was nine kg (50-75th percentile). She had wheezing and 2o/6o cardiac murmur. Her liver was palpable two cm at the midclavicular line, spleen was nonpalpable.

In laboratory examination, her hemoglobin level was 3.5 g/dl, MCV 52.1 fl, RBC 2.42x10<sup>12</sup>/l, RDW %22, MCHC 27.8 g/dl, WBC 11360/mm<sup>3</sup>, platelet count 6900000/mm<sup>3</sup>. Blood film demonstrated

prominent hypochromic microcytic erythrocytes and pencil cells which were compatible with IDA. Differential blood count was: 42% lymphocytes, 44% leucocytes, 10% monocytes and 4% basophils. Reticulocyte count was 1%. Serum ferritin level was 2.5 ng/ml, vitamin B12 677 pg/ml, folic acid 9 ng/ml; direct coombs test was negative. Liver and renal function tests, LDH, CRP, aPTT and PT were within normal limits. Hemoglobin electrophoresis was normal (Hb A 98.2%, Hb A2 1.8%). Stool tests were negative for blood and parasites. Urine test was normal. Celiac screening was negative. Abdominal ultrasound was within normal limits. Her mother's hemoglobin was 13.5 g/dl, MCV 85.0 fl, WBC 8490/mm<sup>3</sup> and platelet count was 52000/mm<sup>3</sup>, her father's hemoglobin was 16.8 g/dl, MCV 91.0 fl, WBC 10840/mm<sup>3</sup> and platelet count was 344000/mm<sup>3</sup>.

As the patient had cardiac failure due to severe anemia, she received 15 cc/kg erythrocyte suspension and her hemoglobin level increased up to 8.1 g/dl. After ameliorating life threatening anemia, oral iron medication was started. The chest film which was performed in order to evaluate severe IDA, demonstrated supra-diaphragmatic air density disrupting the integrity of the diaphragm (Figure 1A). Thorax CT revealed supra-diaphragmatic herniation of gastro-oesophageal junction and a part of the stomach (Figure 1B, 1C). Upper gastrointestinal tract radiography with barium confirmed the diagnosis. HH repair and Nissen fundoplication was performed without any complication. In the follow up recurrent IDA was not observed.

## DISCUSSION

Iron deficiency anemia (IDA) is the most common type of anemia in the developing countries. The data obtained from the project 'Turkey, like iron' which was held by the Ministry of Health of Turkey in 2008 showed that the prevalence of IDA among children of age 12-23 months is 7.8%.

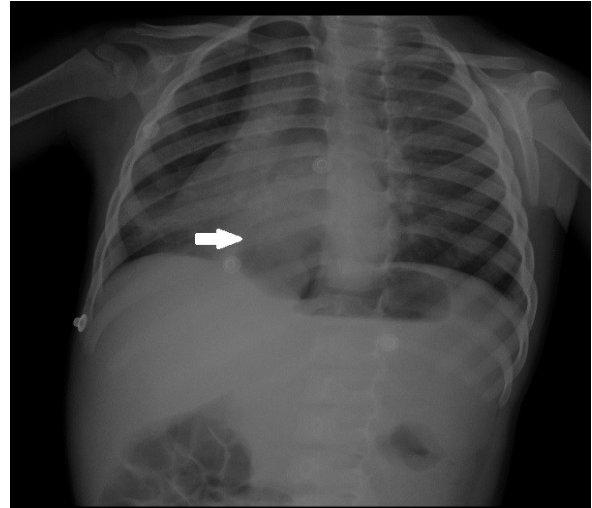


Figure 1A. Posterior- anterior lung film demonstrating air density above the diaphragm on the right, which disrupts the integrity of the diaphragm.

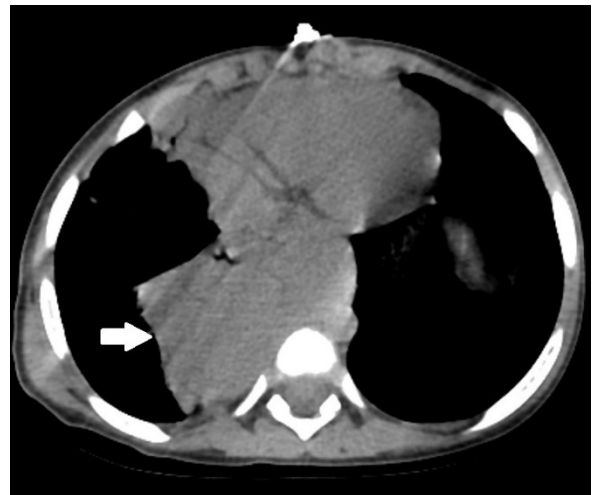


Figure 1B. Axial thoracic sections in the mediastinal window demonstrating herniation of gastro-oesophageal junction and a part of stomach in the borderline of right lung

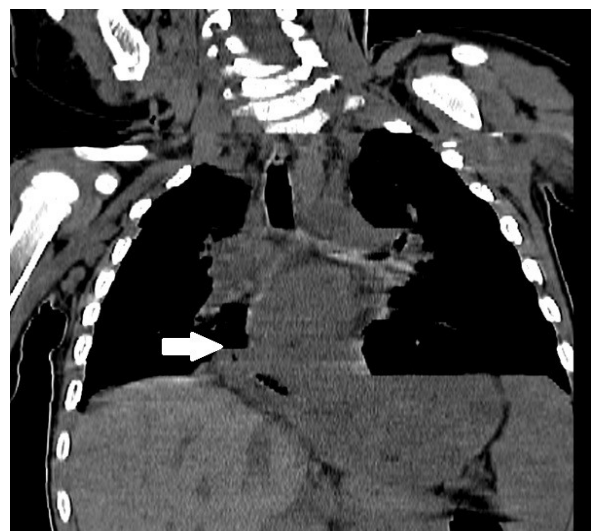

Figure 1C. Coronal section reformatted thorax CT demonstrates the partial herniation of stomach into thorax

The most common cause of IDA is inadequate intake during the rapidly growing years of infancy and childhood. Exclusively breastfeeding after 6 months and/ or excessive consuming of cow's milk are risk factors for inadequate iron intake (2).

In all cases of IDA, blood loss should be considered. Iron deficiency by itself may result in occult blood loss from the gut. Cow's milk can also result in an exudative enteropathy as well. Chronic blood loss from menstruation or hookworm infection has the greatest impact worldwide. Impaired iron absorption states like severe prolonged diarrhea, celiac disease, post gastrectomy, inflammatory bowel disease may also cause IDA. Celiac disease is a common cause of anemia owing to low iron absorption from the gut (3).

Anatomic gut lesions like HH may also cause IDA (3). The mechanism of HH and IDA in children is unknown; however, possible mechanisms in adults have been suggested. First, HH causes gastroesophageal reflux and esophagitis (4). Second, Cameron ulcers, which are linear gastric ulcers in HH, have been associated with an overt or occult gastrointestinal hemorrhage (5). Third, iron malabsorption induced by HH is also described (1). Although upper gastrointestinal tract endoscopy was not performed for the patient described, she did not have a history gastrointestinal bleeding and was negative for fecal occult blood. HH was detected during the detailed evaluation for etiology of severe IDA. The negative fecal occult blood test may be attributed to intermittent blood loss. Repetitive tests are supposed to be more informal.

The cut off value of hemoglobin for IDA which is not compatible with life is not exactly defined in English literature. Buchta et al (4) reported a 20 year old man with only growth retardation, had a hemoglobin level of 1.5 g/dl and IDA was found to be related to HH and corrosive esophagitis.

Zaki et al (6) reported that a 5 year old girl with growth retardation who had a hemoglobin level of 4.8 g/dl and the laboratory findings were compatible with IDA and diaphragmatic hernia.

The patient has mild thrombocytosis on admission. Thrombocytosis in pediatric practice is usually reactive and resolves after correction of underlying disease (7). The most common causes of reactive thrombocytosis are infection and IDA (7).

To summarize, pediatricians should be aware of severe or medically refractory IDA, which may be related to HH. It is recommended to evaluate all patients with appropriate imaging modalities. A chest X-ray is not only valuable for detecting cardiomegaly but can also suggest other reasons for IDA. Once a HH has been diagnosed in a child, surgical repair may be necessary for a total recovery from IDA.

## REFERENCES

1. Shih TC, Shih HH, Chang YT, Dai ZK, Chen IC. Hiatal Hernia: A Rare Cause of Iron-Deficiency Anemia in Children. *Pediatr Neonatol*. 2016 Dec 18. pii:1875-9572(16)30370-9. doi:0.1016/j.pedneo.2016.05.008. [Epub ahead of print]
2. Brotanek JM, Halterman JS, Auinger P, Flores G, Weitzman M. Iron deficiency, prolonged bottle-feeding, and racial/ethnic disparities in young children. *Arch Pediatr Adolesc Med* 2005;159:1038-42.
3. Lanzkowsky's Manual of Pediatric Hematology and Oncology: Iron-Deficiency Anemia, Etiologic Factors, In: Philip Lanzkowsky, Jeffrey M. Lipton, Jonathan D. Fish (Eds). *Iron-Deficiency Anemia*. 6th edition. Elsevier, Mica Haley, UK 2016:69- 73.
4. Buchta RM, Bickerton R. A case of profound iron deficiency anemia owing to corrosive esophagitis in a 20-year-old developmentally delayed male. *J Adolesc Health*. 1994 Nov;15(7):592-4.
5. Moskovitz M, Fadden R, Min T, Jansma D, Gavalier J. Large hiatal hernias, anemia, and linear gastric erosion: studies of etiology and medical therapy. *Am J Gastroenterol*. 1992 May;87(5):622-6.
6. Zaki SA, Dadge D, Shanbag P. Diaphragmatic hernia presenting as gastrointestinal bleeding. *Indian Pediatr*. 2010 Feb;47(2):185-7.
7. Sarangi R, Pradhan S, Dhanawat A, Patanayak R, Benia G. Thrombocytosis in children: Clinico-hematological profile from a single centre in Eastern India. *J Lab Physicians*. 2018 Jan-Mar;10(1):34-37.